





Coccygodynia

“A pain in the rear”




James J. Lehman, DC, MBA, DABCO
Assistant Professor of Clinical Sciences
University of Bridgeport College of Chiropractic



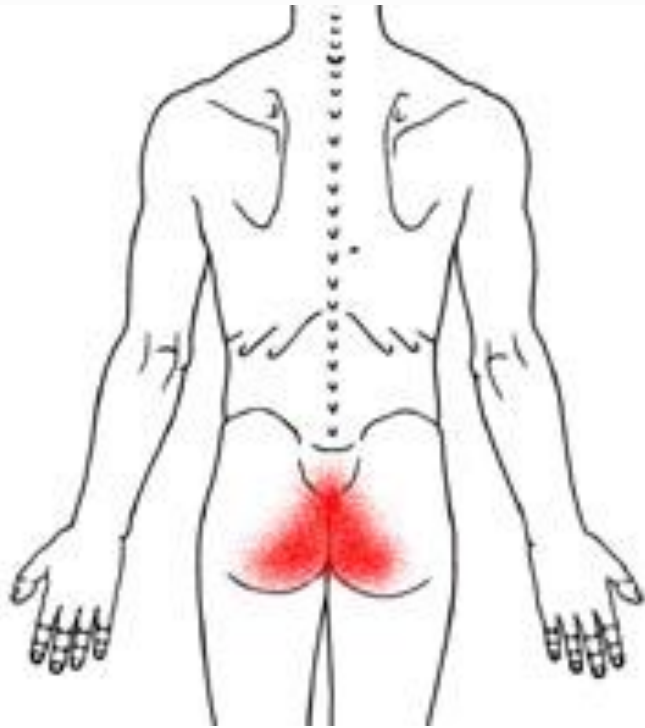
Coccygodynia

*What's in a name?
That which we call a
rose, by any other
name would smell as
sweet;*





Coccygodynia

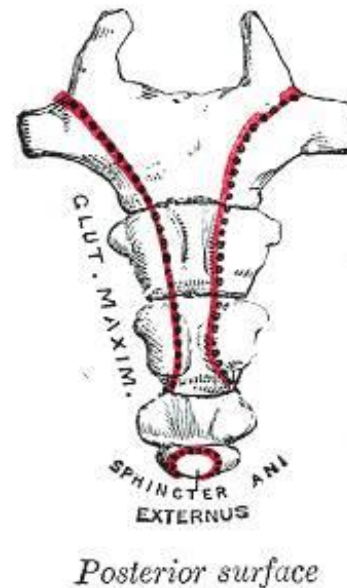
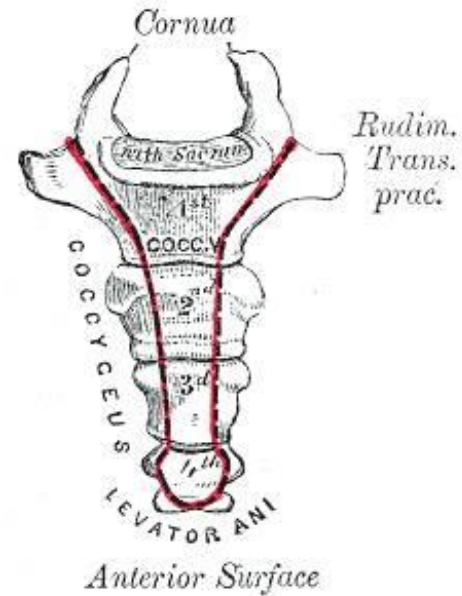


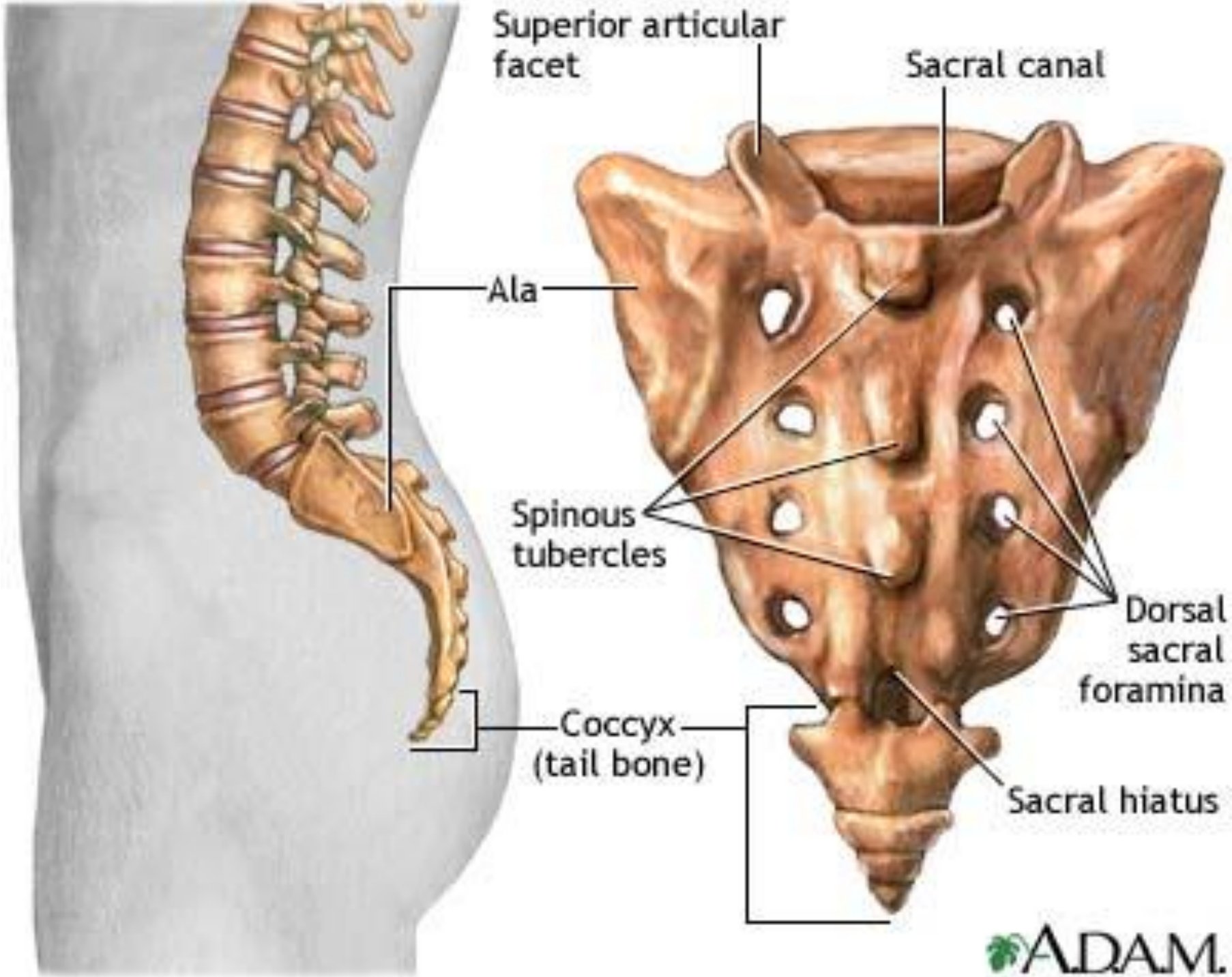
- **coccygodynia** (kok"si-go-din'e-ə) pain in the coccyx and neighboring region. Called also coccyalgia and coccydynia.
- Dorland Medical Dictionary

Description

The coccyx is a vestigial set of bones equivalent to the tail of many mammals.

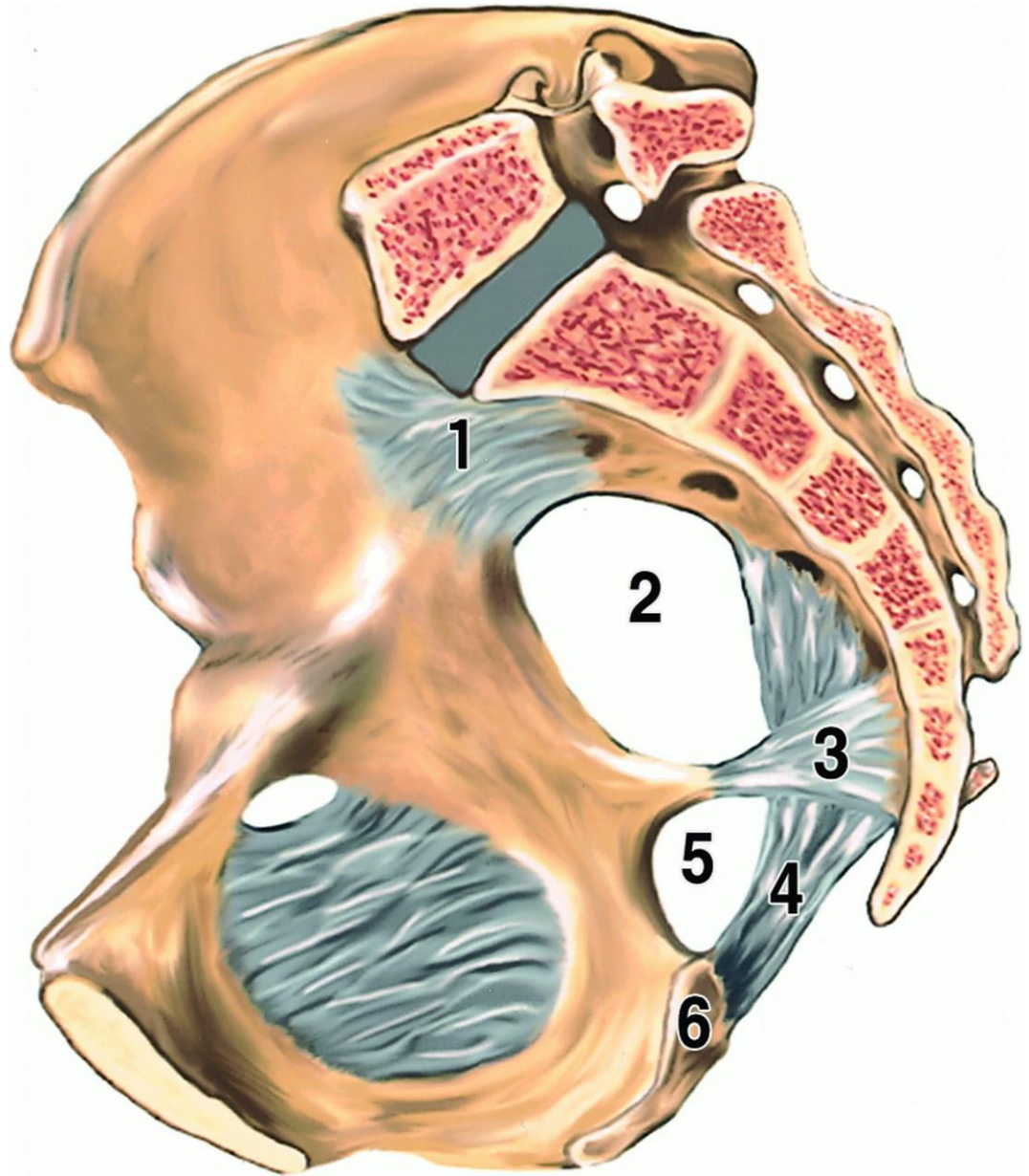
It is the set of fused, tapered, rounded bones, 4-5 in number, that articulate with the sacrum.





Midsagittal view of the greater sciatic foramen.

- 1 = sacral promontory,
- 2 = greater sciatic foramen,
- 3 = sacrospinous ligament,
- 4 = sacrotuberous ligament,
- 5 = lesser sciatic foramen,
- 6 = ischial tuberosity.



The greater sciatic foramen.

1 = piriformis muscle,

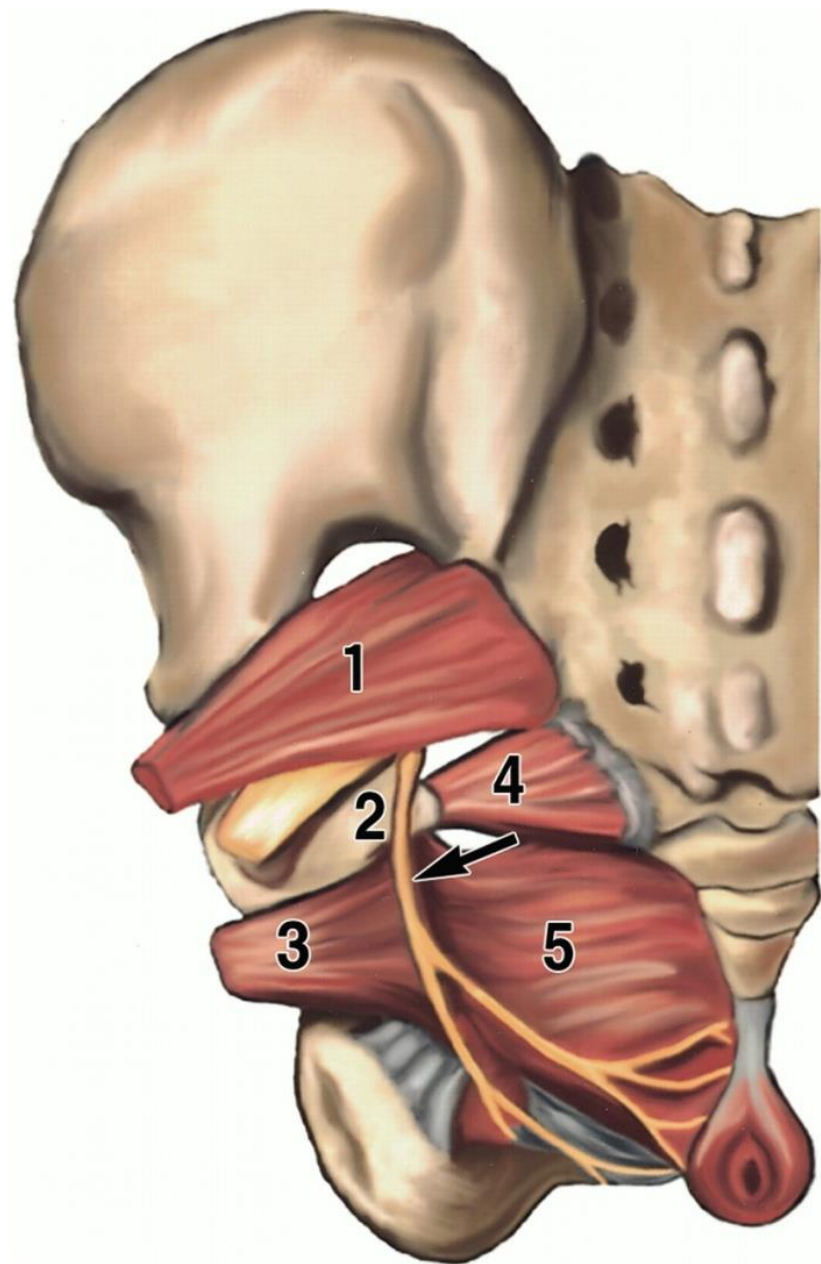
2 = ischial spine,

3 = obturator internus muscle,

4 = coccygeus muscle,

5 = levator ani muscles,

arrow = pudendal nerve.

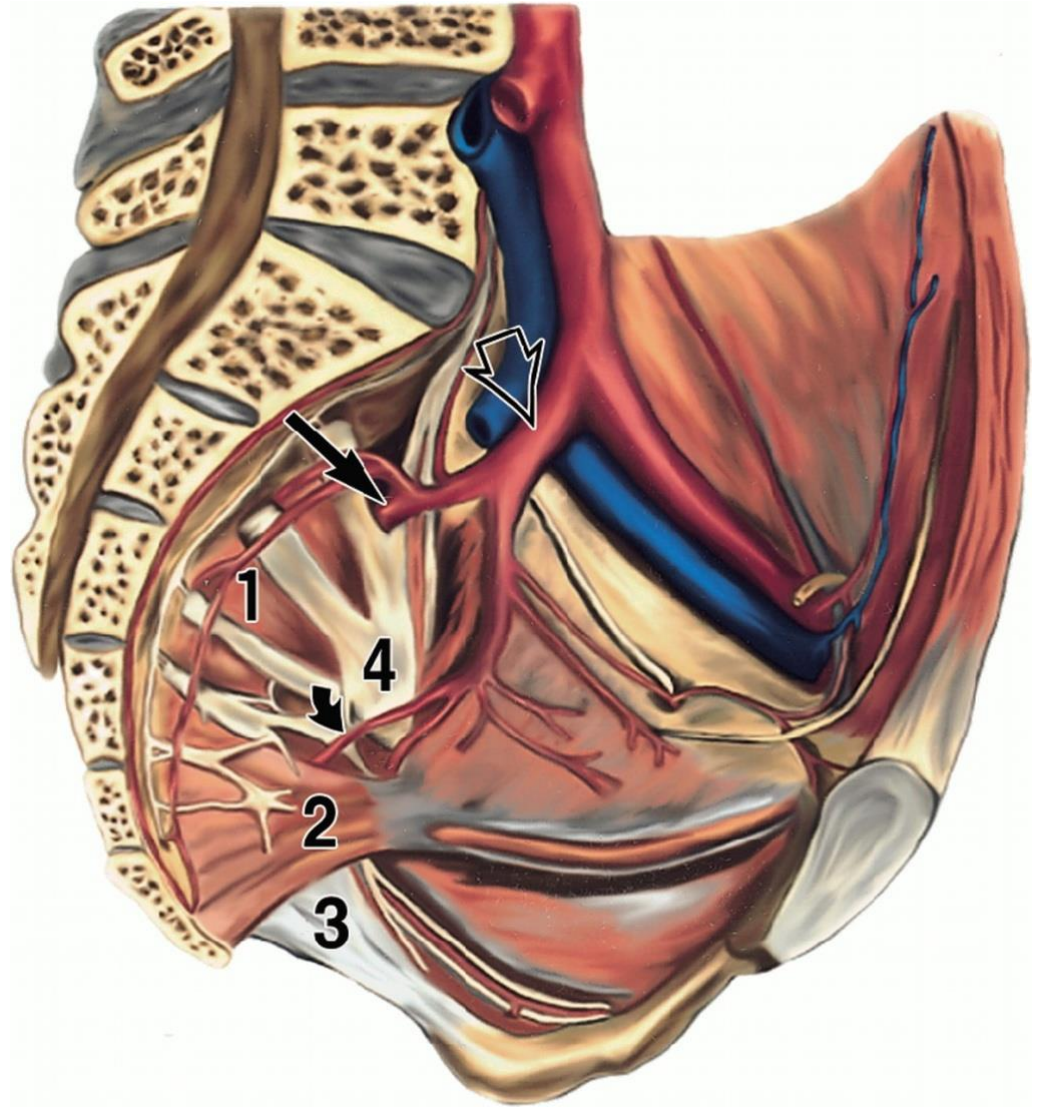


Midsagittal view of the pelvis.

Relationship of the sacral plexus (4) and gluteal arteries to the piriformis muscle (1).

2 = coccygeus muscle,
3 = sacrotuberous ligament,

straight solid arrow = superior gluteal artery,
curved arrow = inferior gluteal artery,
open arrow = internal iliac artery.



Incidence

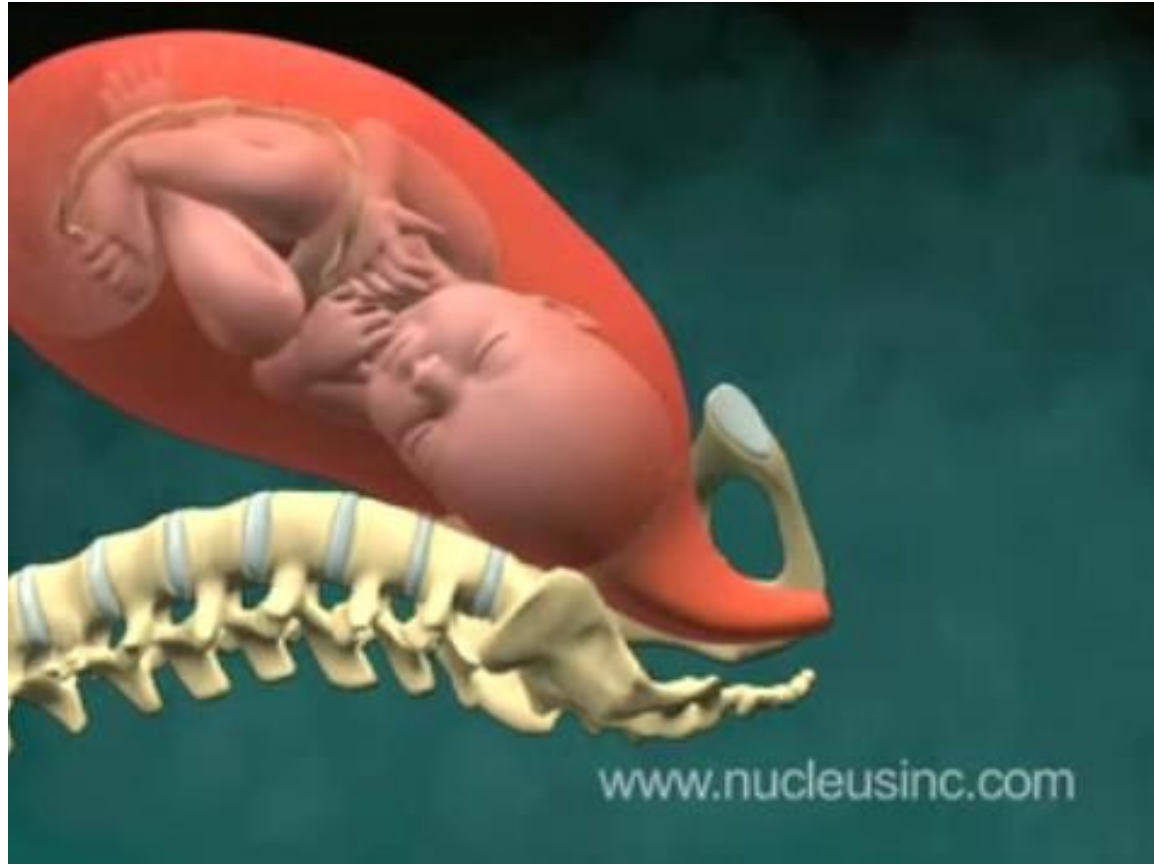
It is 5 times more common in women following direct trauma.

1% of back pain reported to physicians.



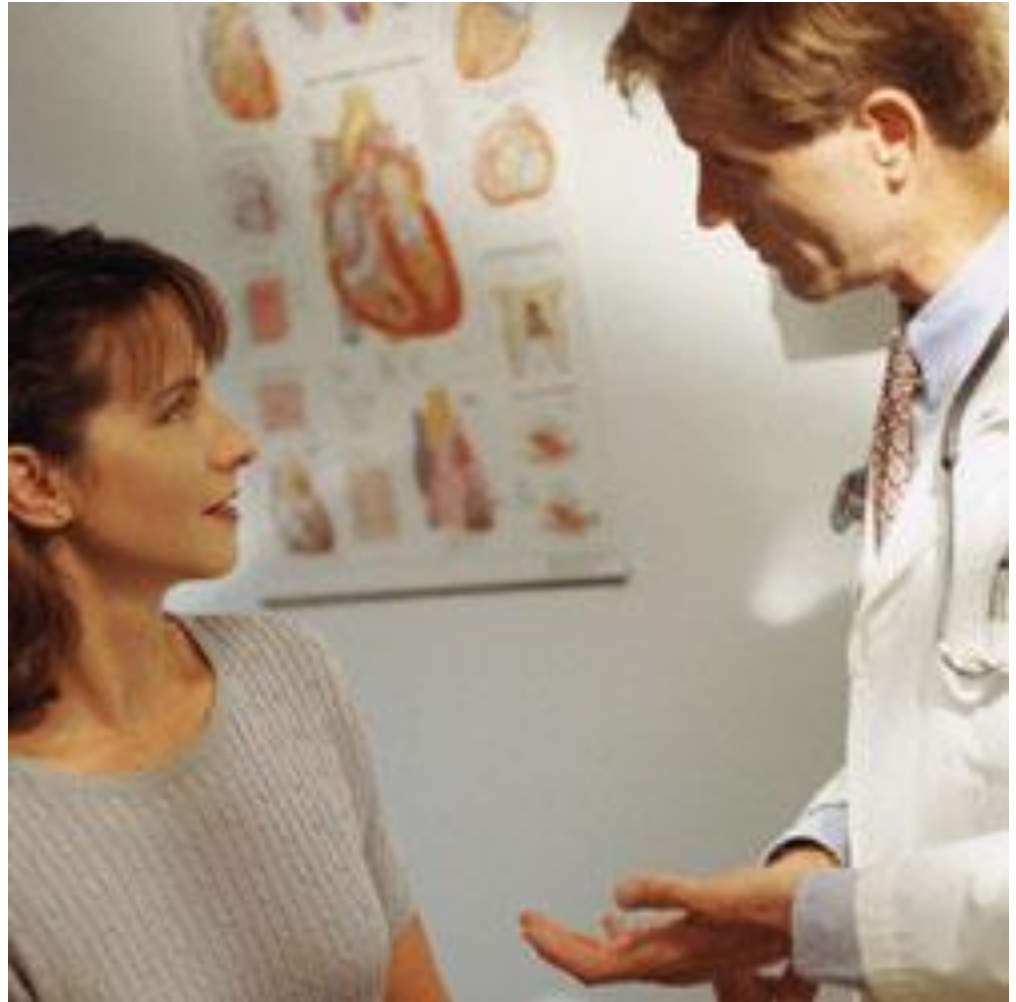Causes



Because patients often mention a fall on the buttocks or a delivery as precipitating event, a mechanical basis for the pain is likely.



Patient dilemma

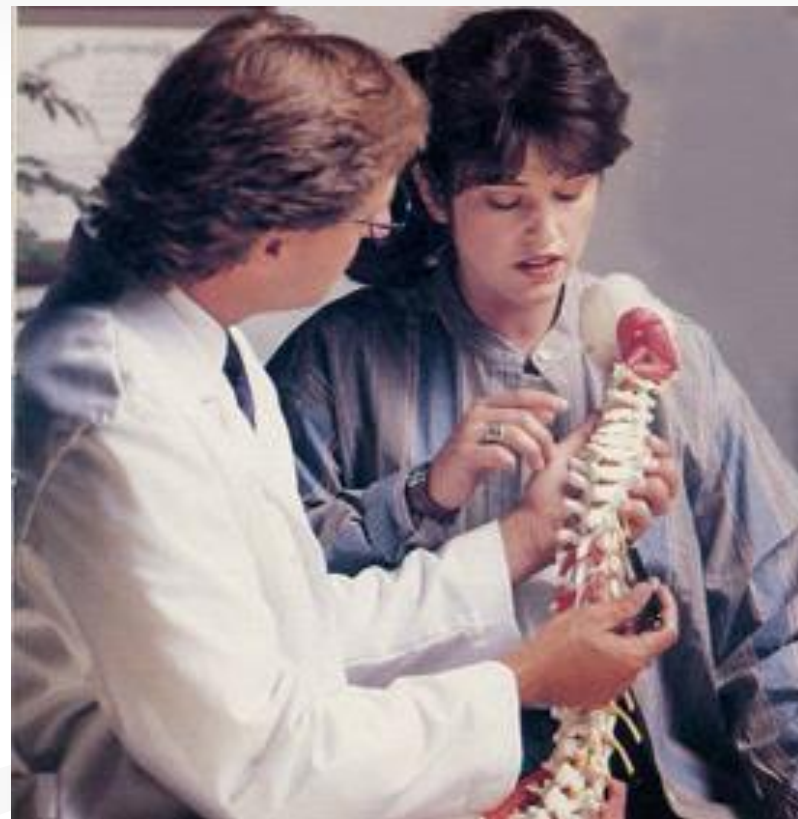
Patients with coccygodynia often report that their physicians minimize, dismiss, or belittle their symptoms.





Professional Questions

- Why would their (allopathic) physicians minimize, dismiss, or belittle their symptoms?
- Do chiropractic physicians react differently?



Patient Dilemma

Coccygodynia is often relatively severe and persistent, causing significant compromise of the patient's ability to perform or endure various activities.





Solution

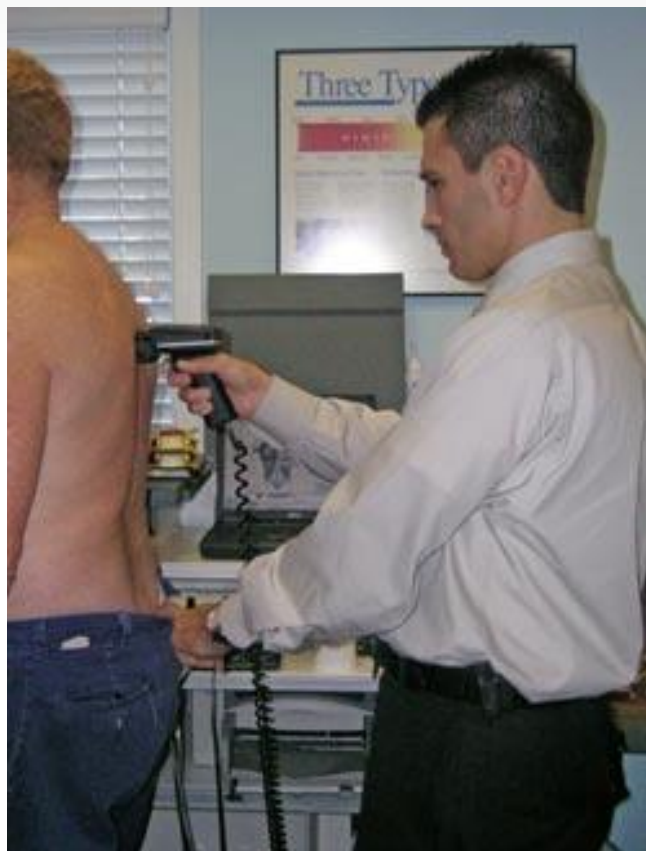Physicians who understand coccygodynia and the available treatment options can provide a great service to this otherwise neglected patient population.

'Tell me about
your pain in the butt'





Professional Question

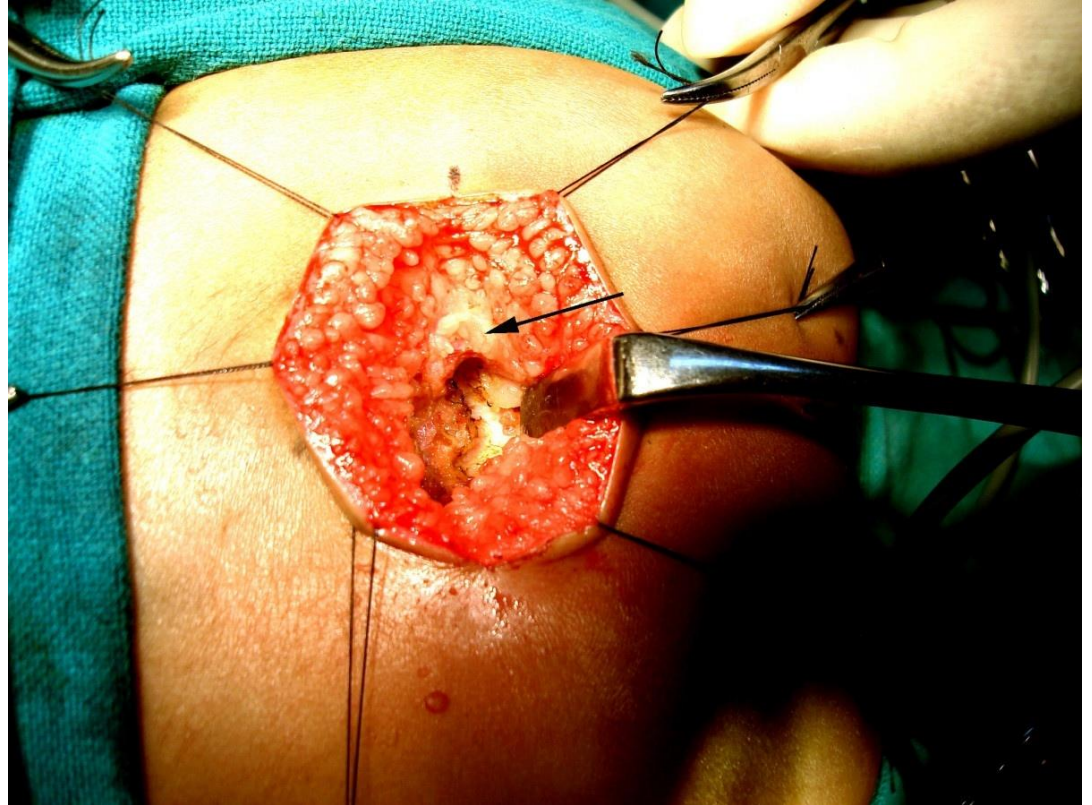


- How do chiropractic physicians evaluate and manage patients suffering with coccygodynia?

Clinical Question:

Select the conservative care that you would consider prior to surgical excision for coccydynia?

1. NSAIDS
2. Donut cushion
3. Diathermy
4. Cryotherapy (ice)
5. Spinal manipulation
6. Coccygeal manipulation
7. Myofascial treatment
8. Radiotherapy
9. Manipulation of coccyx under anesthesia
10. Hot baths
11. Injections of anesthetics with corticosteroids
12. Psychotherapy



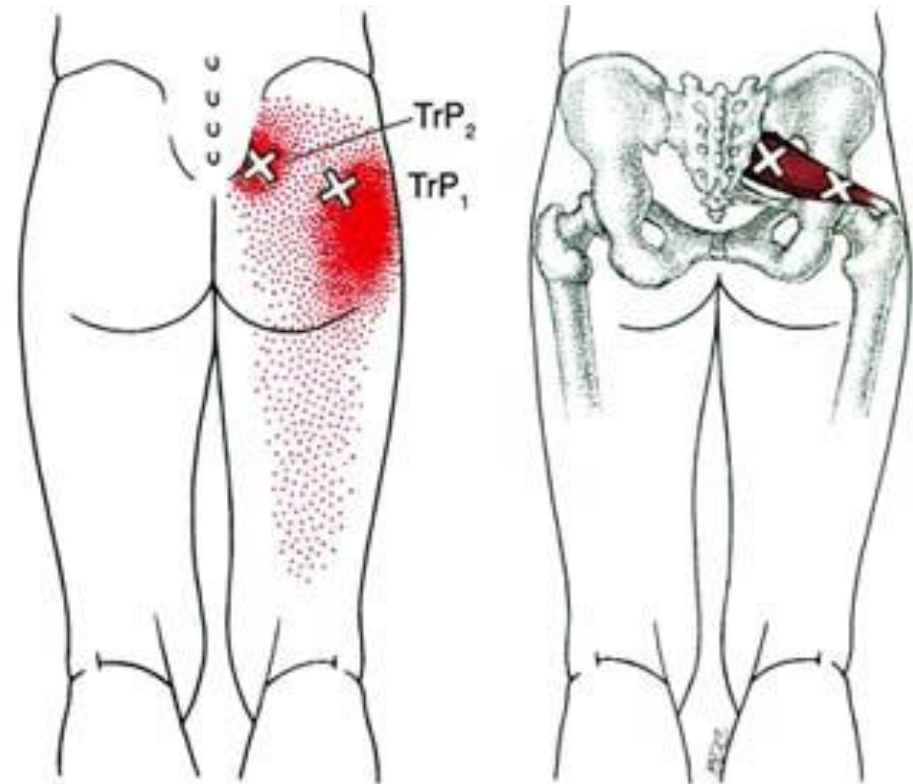
Lumbosacral joint
dysfunction and/or
sacroiliac joint fixation
with pelvic obliquity

Rule out lumbar
and sacral
biomechanical
dysfunction as a
cause of pain in
the tailbone.



Piriformis Myofascial Pain

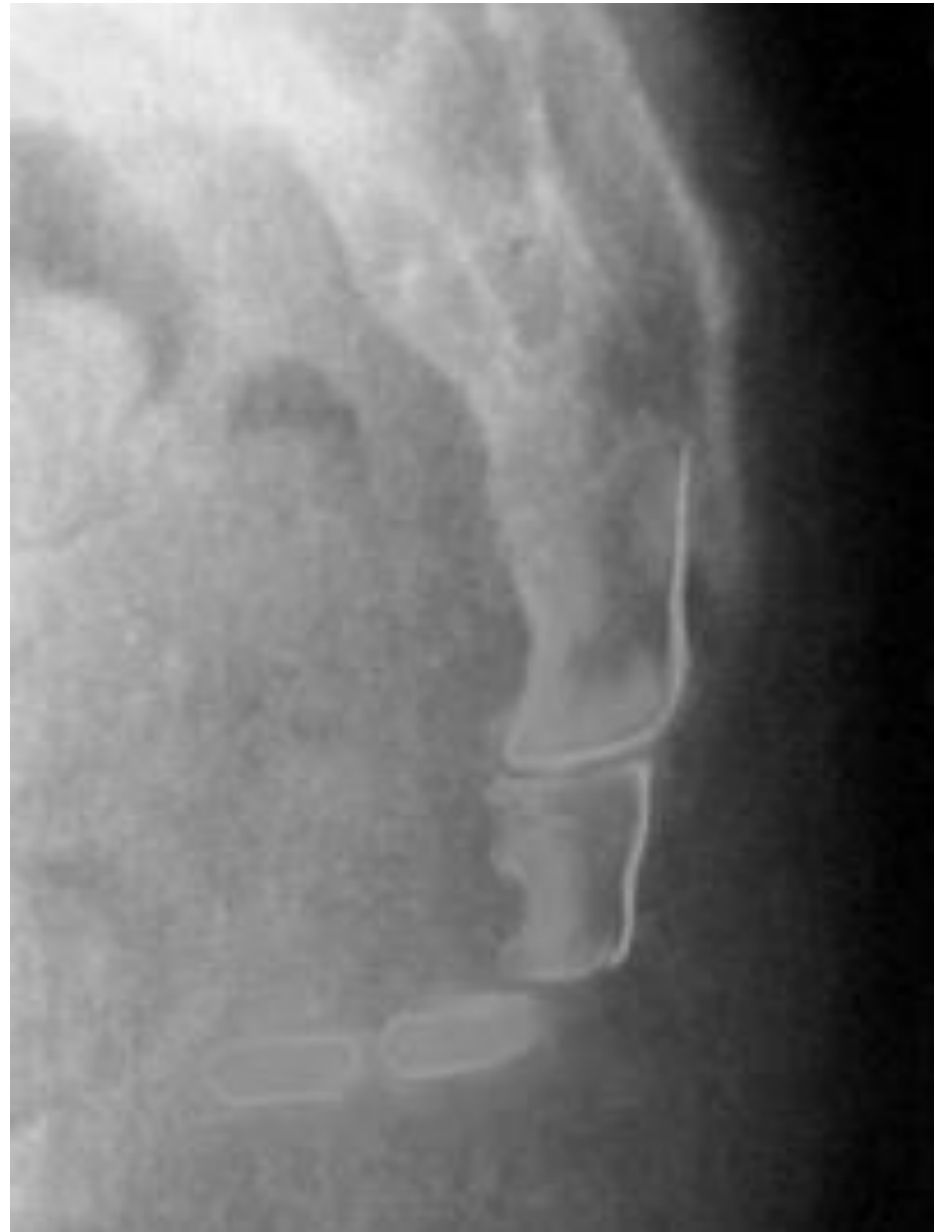Rule out piriformis trigger points or “wallet neuritis” as a cause of pain in the tailbone.



Clinical Question:

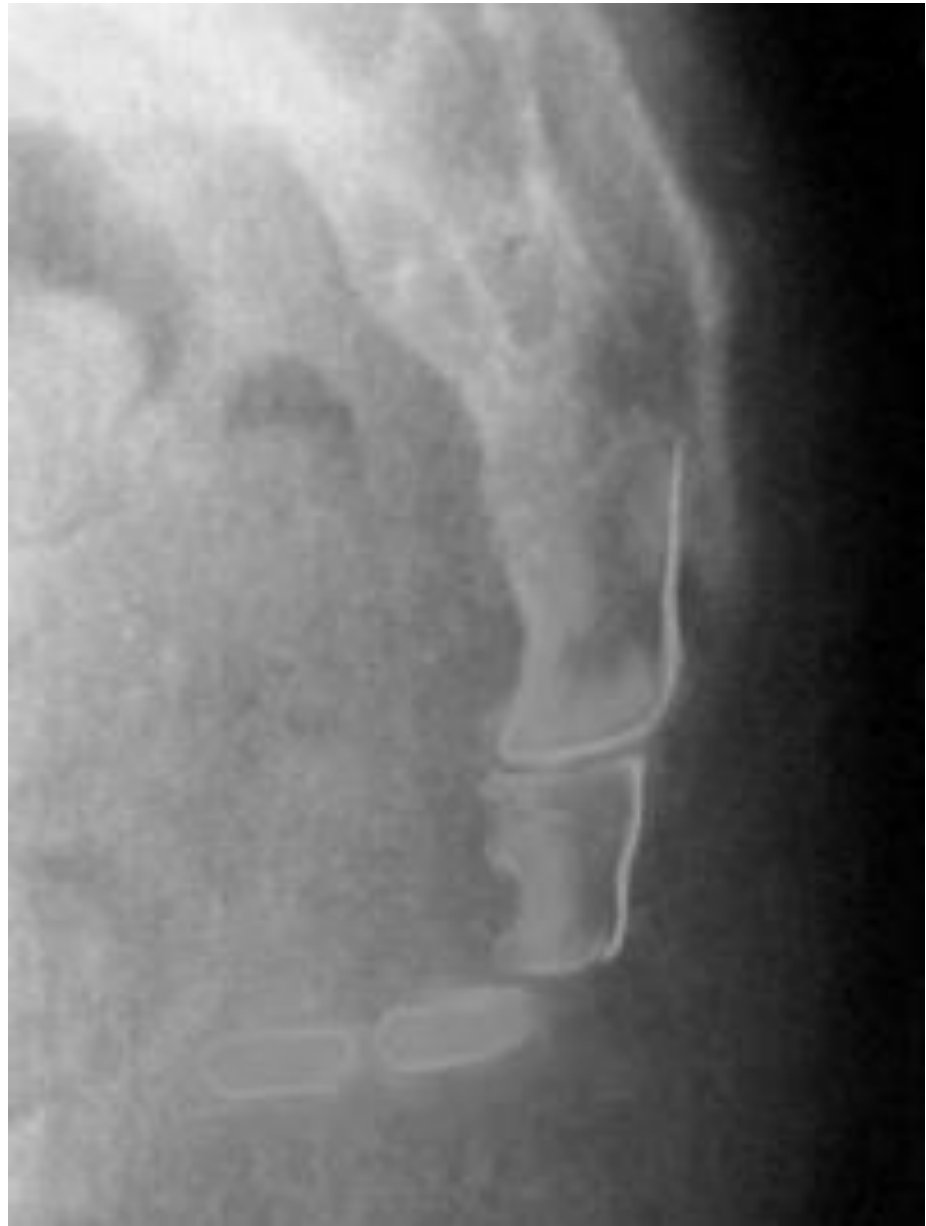What is your diagnosis?

1. Normal sacrococcygeal joint
2. Hypomobility of sacrococcygeal joint
3. Hypermobility of sacrococcygeal joint
4. Subluxation of sacrococcygeal joint
5. Luxation of sacrococcygeal joint
6. Dislocation of sacrococcygeal joint



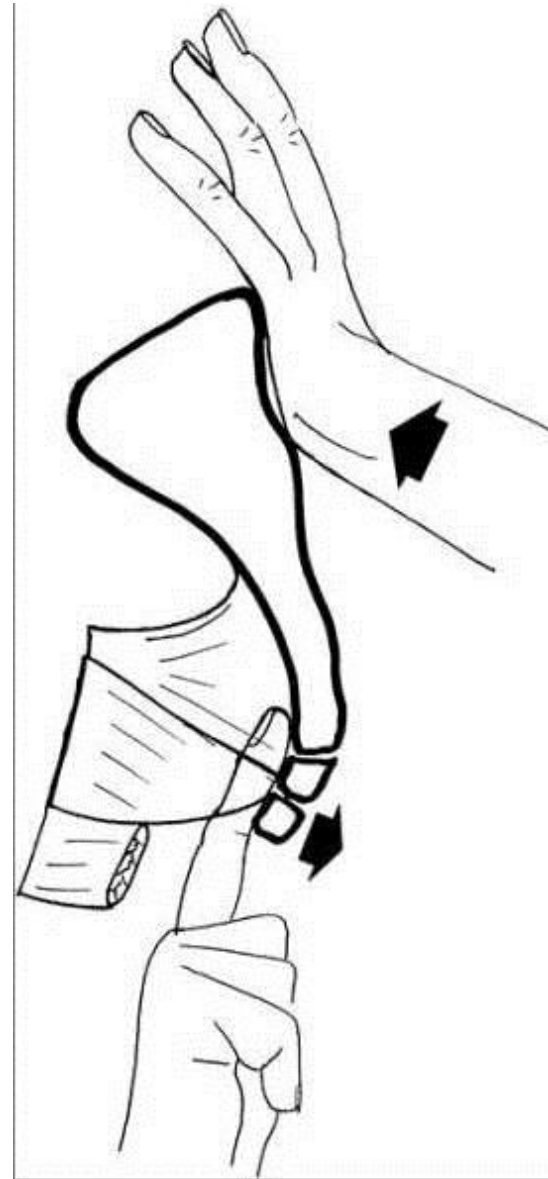
Clinical Questions

1. Would you consider the coccygeal alignment as a cause of coccygodynia?
2. Would you consider internal coccygeal manipulation to treat this patient if she were suffering with coccygodynia?



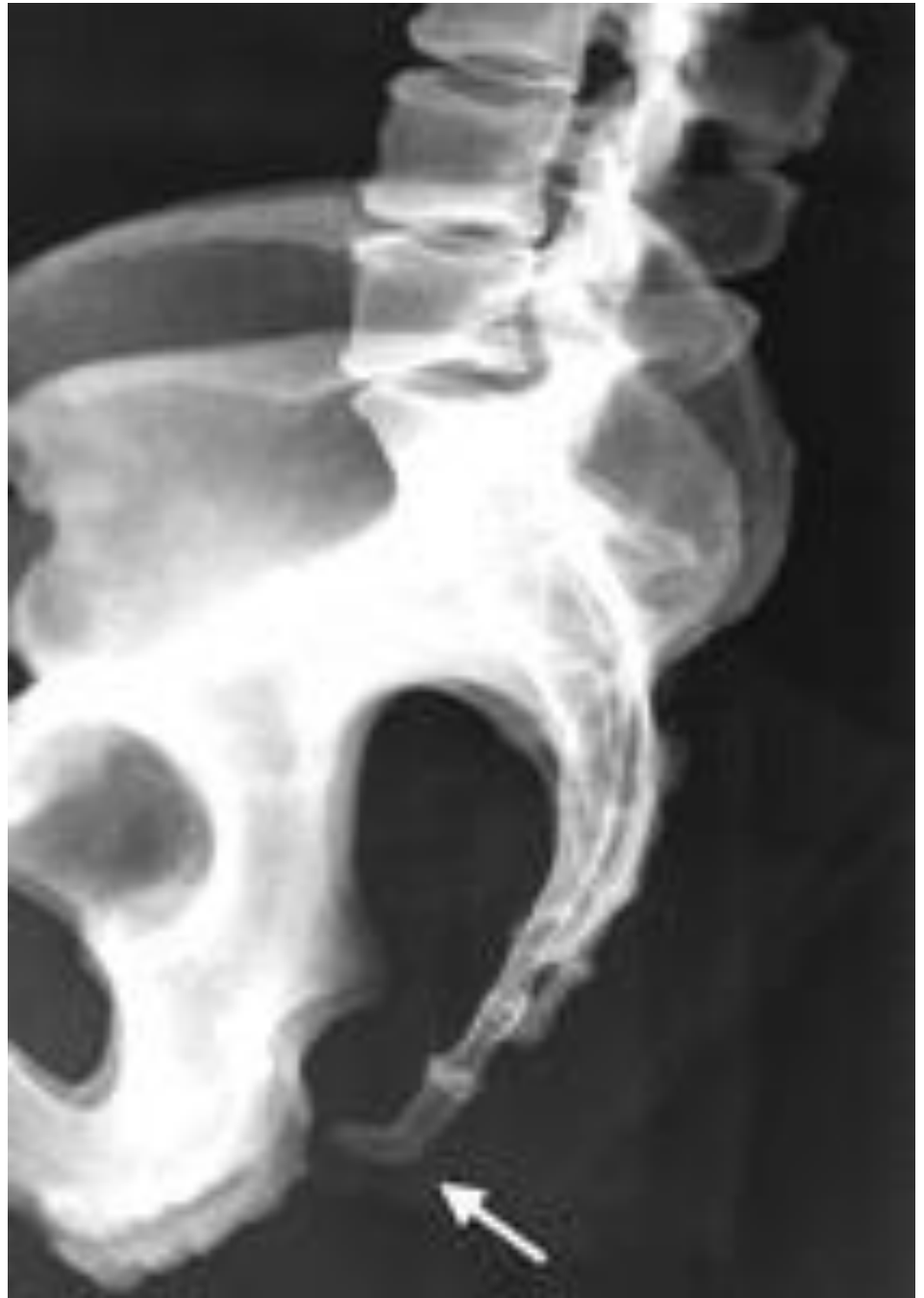Anterior coccyx:
internal method



The coccyx is kept in hyperextension, which stresses the sacrococcygeal and intercoccygeal ligaments, stretches the levator ani muscles and reduces joint misalignments.



Clinical Questions



1. Is the coccygeal alignment abnormal?
2. Do you think the coccygeal position could be a cause of coccygodynia?
3. How would you treat this patient if she were suffering with coccygodynia?







Case Report

- 30 Y/O Female
- CC Pain in tailbone
- HPI
 - Fell onto left buttocks 8/2008
 - Tailbone pain began during 11/2008 with use of elliptical exercise equipment
 - Sitting and leaning back increased pain





Pain Description

- Pain was described as a deep, dull, achey pain that made her nauseated.
- Sitting = 9/10
- Standing and walking = 6/10
- Coughing increased the local pain
- Rising to stand could increase pain
- External palpation of coccyx increased pain





Past History

- Past history included a fall onto the buttocks 16 years ago during the summer of 1992 while attending the tenth grade. This episode of pain in the tailbone bothered her for about one year with sitting but not with standing. She described the pain sensations for the initial episode similar to the 2008 episode of pain in the tailbone area.





Physical Examination

- Patient pointed to coccygeal area as the site of pain and palpation duplicated it.
- Walking and sitting provoked pain.
- Internal rectal exam provoked the pain with palpation of the levator ani muscles.
- The coccyx was stable and properly aligned.





Treatment

- Internal rectal treatment of active trigger points was performed with trigger point pressure release (TPPR).
- Eight trigger points were treated in the levator ani, coccygeus, and obturator internus muscles.



Outcome

- Immediately following TPPR the patient was asked to sit on a hard surface and lean back and then to ambulate.
- She was able to sit with 90% reduction in pain.
- She was able to ambulate with 70% reduction in pain.




Outcome

- She was advised to return for care if she did not experience complete relief.
- One year post treatment, she was pain free and able to use the elliptical exercise equipment.

Protocol for Intrarectal Coccygeal Evaluation and Management

James J. Lehman, DC

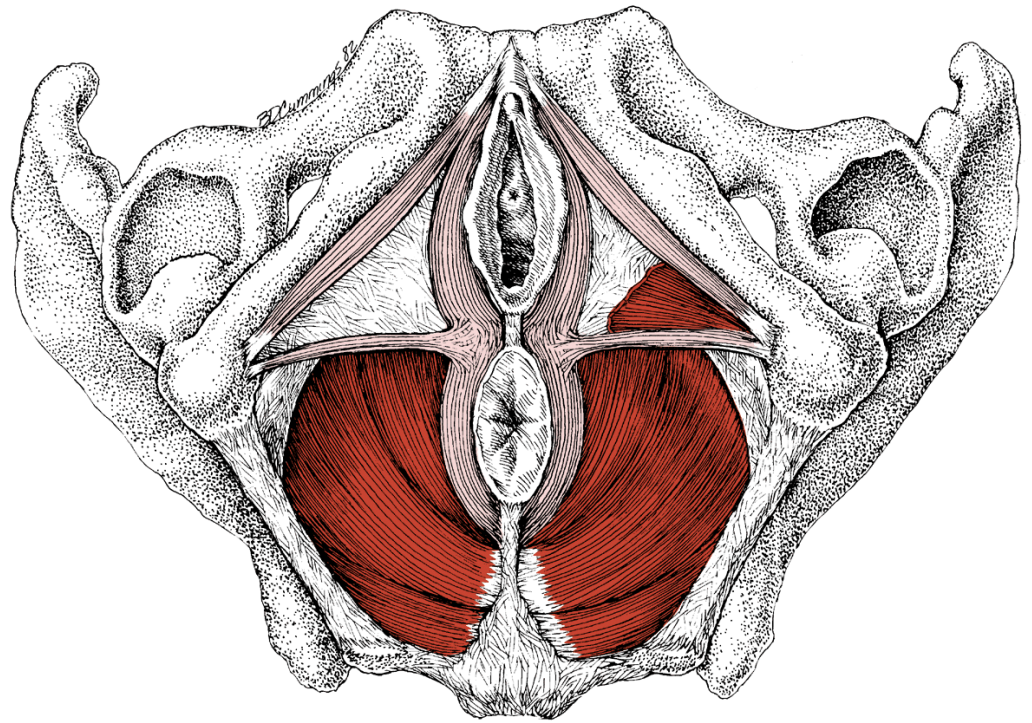
1. Pain in tailbone area
2. History of trauma
3. Chronicity
(>3 months)
4. Sitting on a firm surface is painful
5. Pain is moderate to severe
(VAS 4-10/10)



Protocol for Intrarectal Coccygeal Evaluation and Management

James J. Lehman, DC

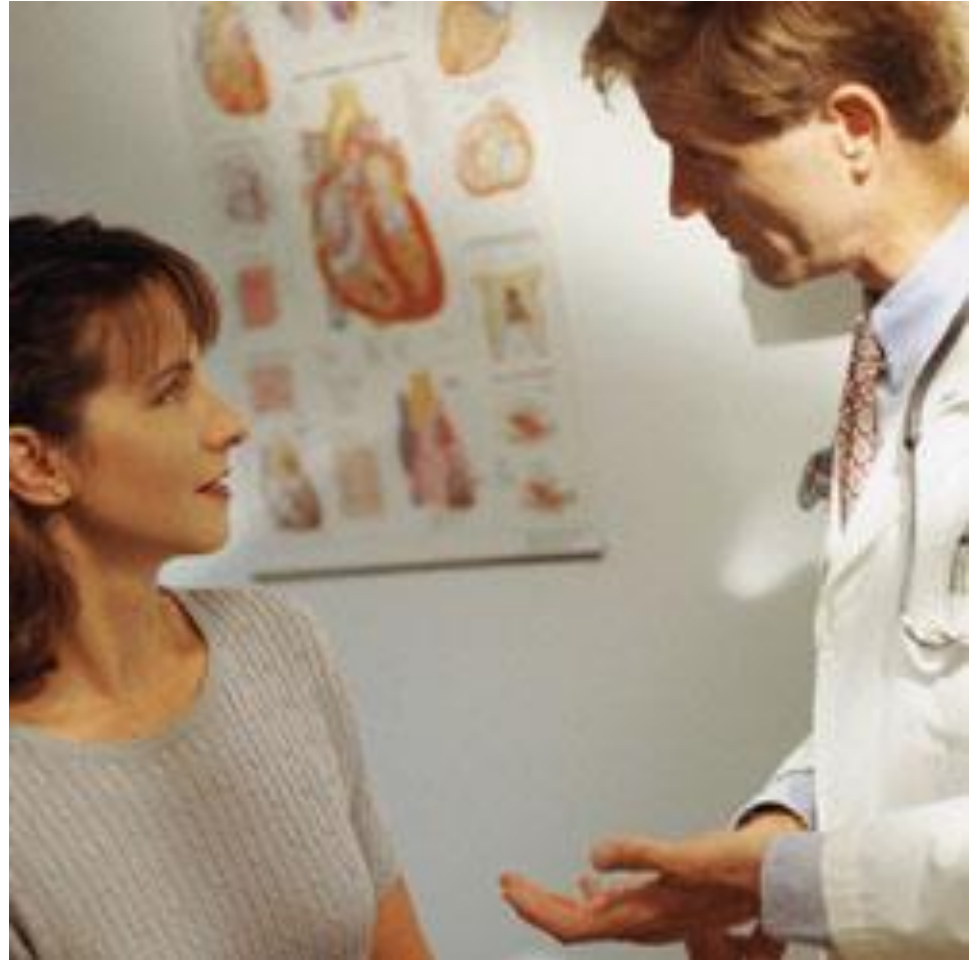6. External palpation of coccyx is painful.
7. Internal palpation of coccyx is painful.
8. Painful active trigger points revealed in the levator ani and coccygeal muscles.
9. Imaging for FX, dislocation, luxation, subluxation.



Protocol for Intrarectal Coccygeal Evaluation and Management

James J. Lehman, DC

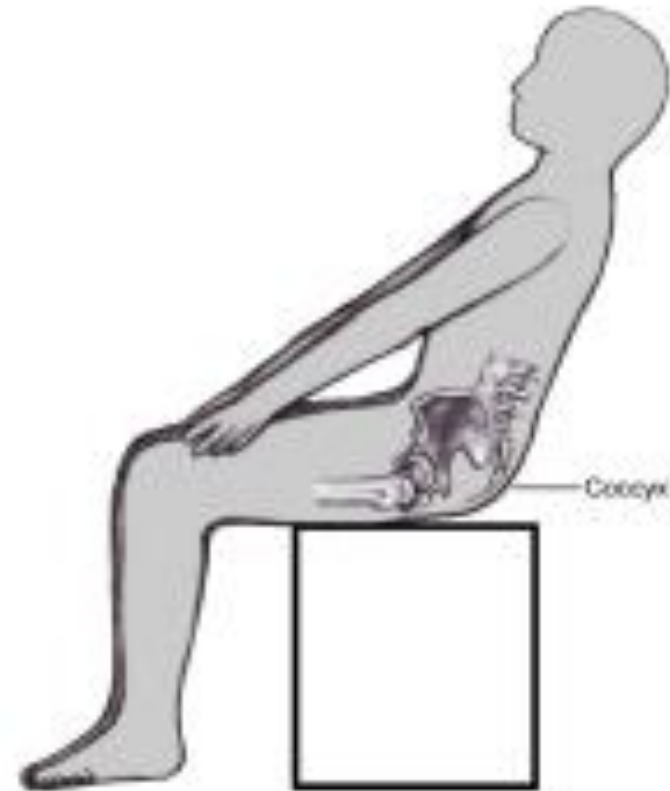
10. Provide full explanation of procedure, benefits, risks, alternatives.
11. Record informed consent process.
12. Patient is advised that the procedure will be uncomfortable.



Protocol for Intrarectal Coccygeal Evaluation and Management

James J. Lehman, DC

13. Advise patient that the results of a successful treatment will be evident immediately following the intervention.
14. The patient will be advised to sit on a firm surface and determine if pain severity is reduced or eliminated following treatment.



Protocol for Intrarectal Coccygeal Evaluation and Management

James J. Lehman, DC

15. Patient is advised to evacuate bowel prior to treatment.
16. Patient is advised that she will be wearing a gown with the open part in the back.
17. Patient is advised that she will need to remove panties.



Protocol for Intrarectal Coccygeal Evaluation and Management

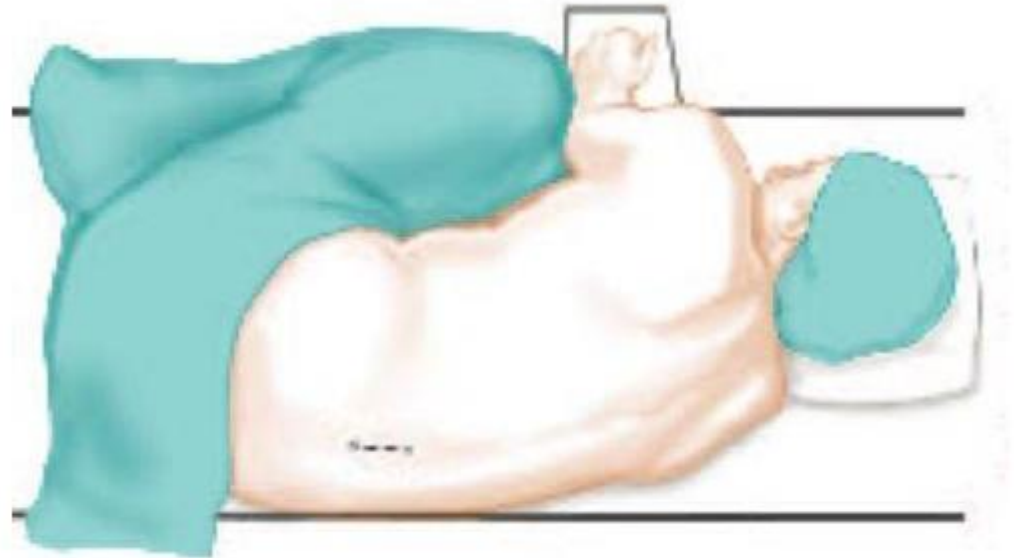
James J. Lehman, DC

18. Exam room should be near a restroom.

19. Patient is gowned and placed in a lateral decubitus position with knees flexed.

20. Provide patient with tissue.

21. Sheet or large towel covers the buttocks and lower extremities.



Protocol for Intrarectal Coccygeal Evaluation and Management

James J. Lehman, DC

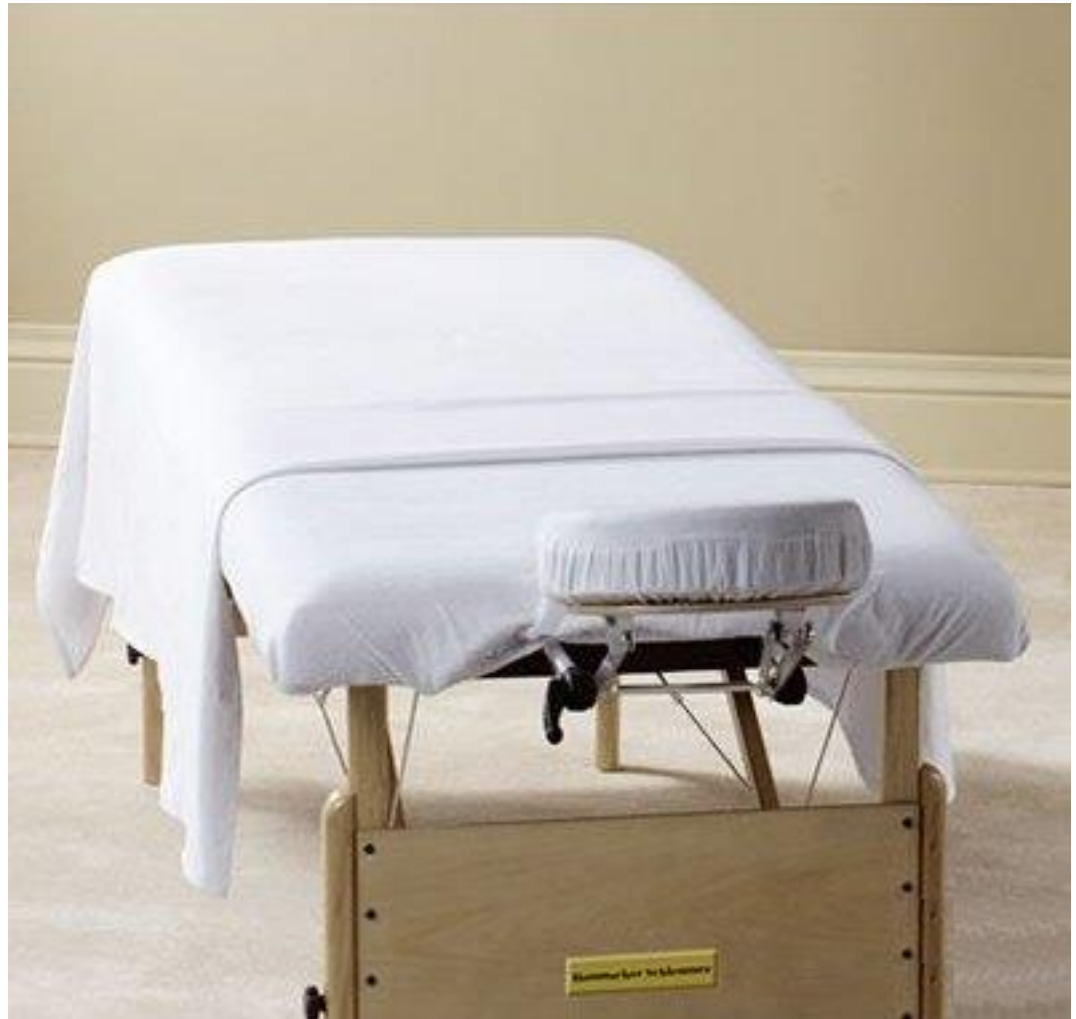22. Ask patient if she is ready to begin.

23. If she agrees, then prepare for the exam.

24. Place towel on exam table inferior to the buttocks of patient.

25. Place lubricant (KY jelly), examination gloves, and tissues.

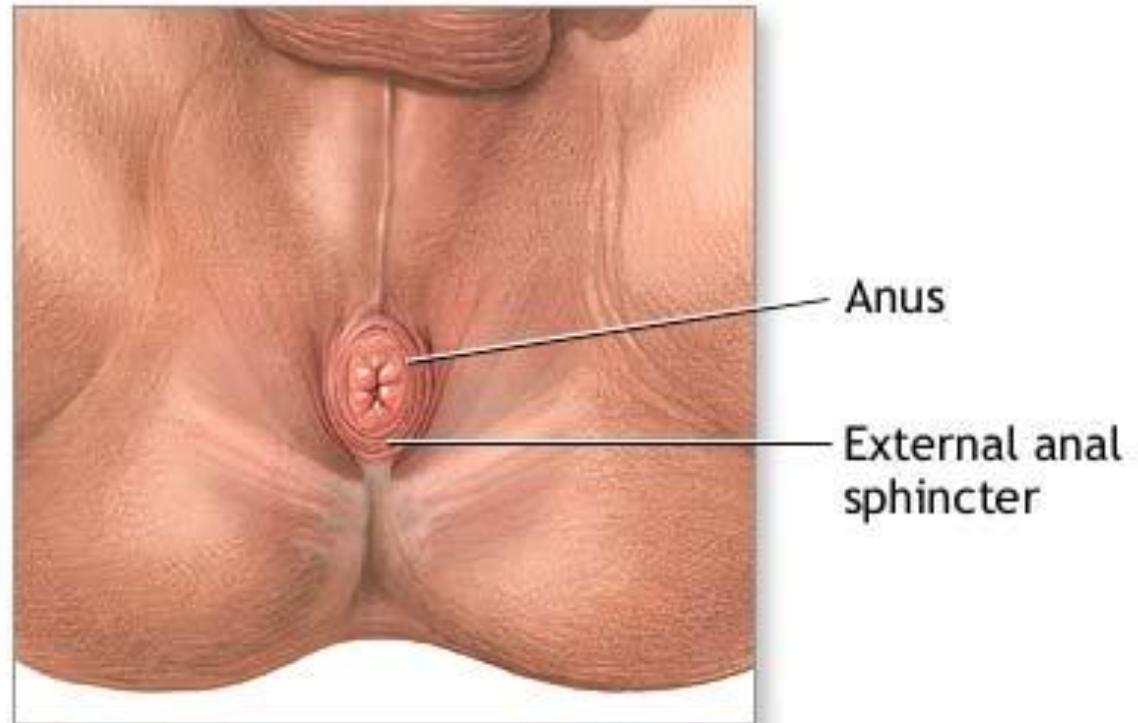
26. Put glove on examining hand and apply lubricant to examining finger.



Protocol for Intrarectal Coccygeal Evaluation and Management

James J. Lehman, DC

27. Examine anus and apply lubricant.
28. Advise patient that you will insert your lubricated finger.
29. Slowly insert examining finger while confirming patient is tolerating the procedure.
30. Advise patient you will stop if the pain is not tolerable.



Protocol for Intrarectal Coccygeal Evaluation and Management

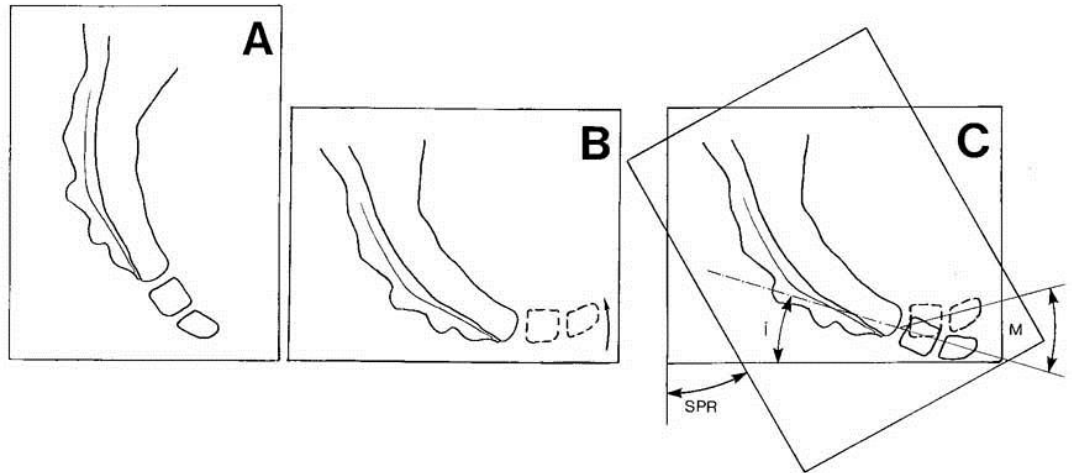
James J. Lehman, DC

28. Palpate the coccyx
for pain and motion.

29. Manual treatment
most often involves an
anterior to posterior
mobilization of the
coccyx with the internal
digit.

30. The external hand
contacts the posterior
sacrum to stabilize.

31. The internal digit
gently and slowly applies
mild traction to the
coccyx from superior to
inferior.

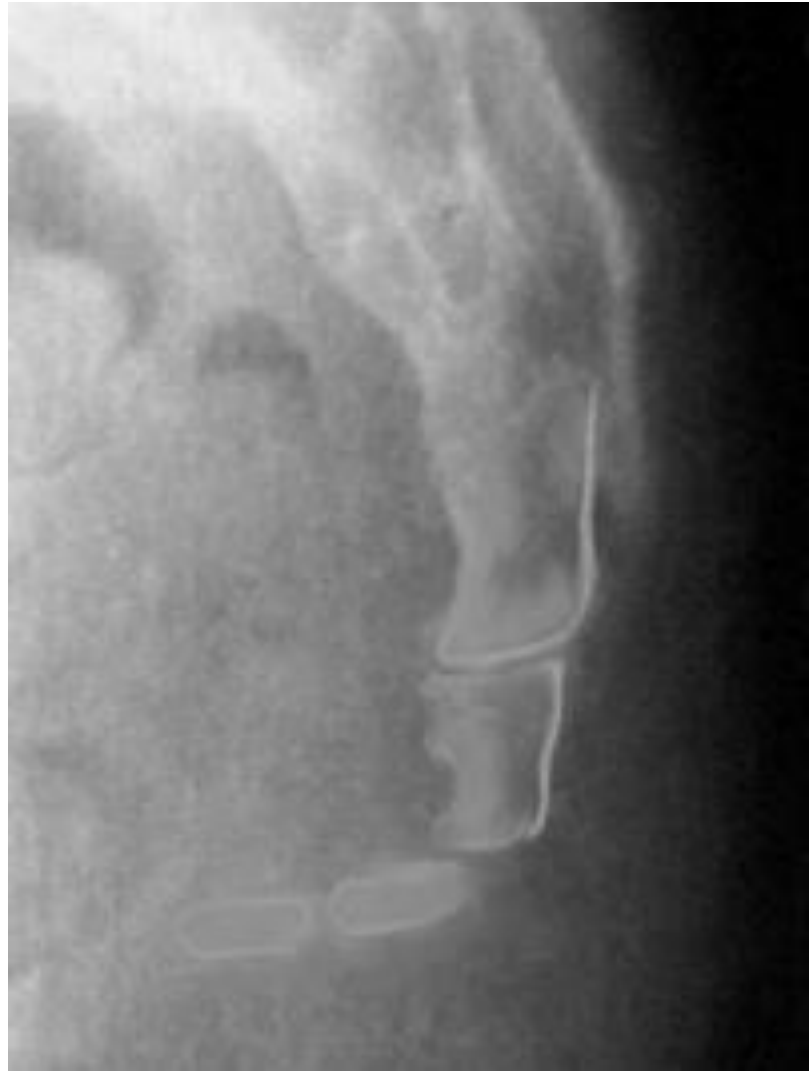

Protocol for Intrarectal Coccygeal Evaluation and Management

James J. Lehman, DC

32. If the joint is stable, the mobilization is performed three times.

33. If unstable, the reduction should be performed only once.



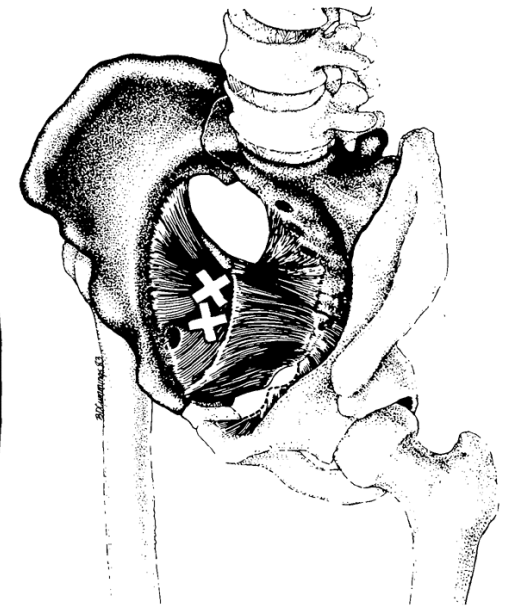
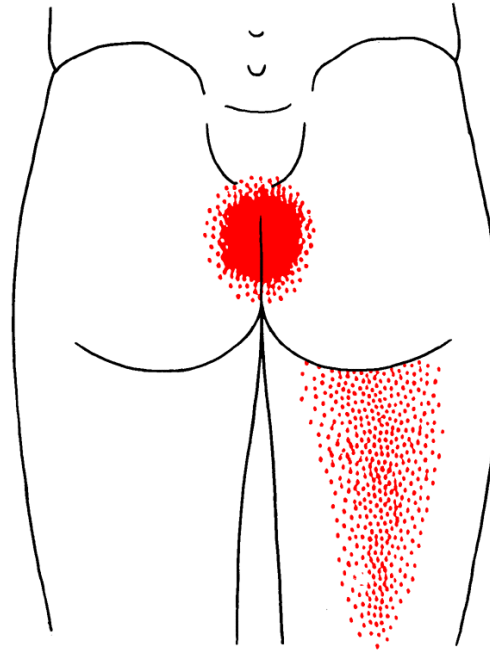
Protocol for Intrarectal Coccygeal Evaluation and Management

James J. Lehman, DC

34. Palpate the pelvic floor muscles for sites of pain and hypertonicity.

35. Identify the myofascial trigger points and treat with myofascial trigger point releases.

36. Apply gentle but firm continuous pressure to the trigger point and hold for 10 seconds.



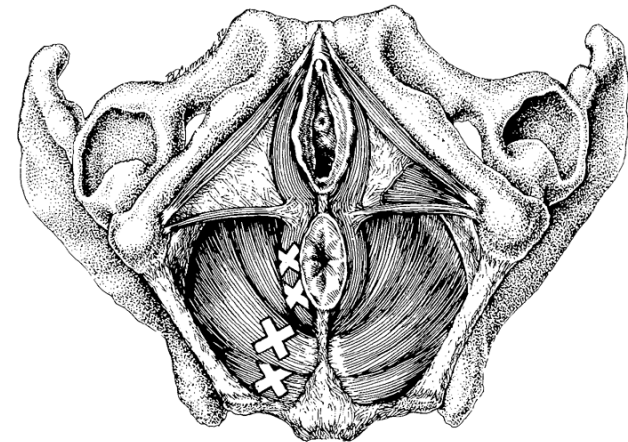
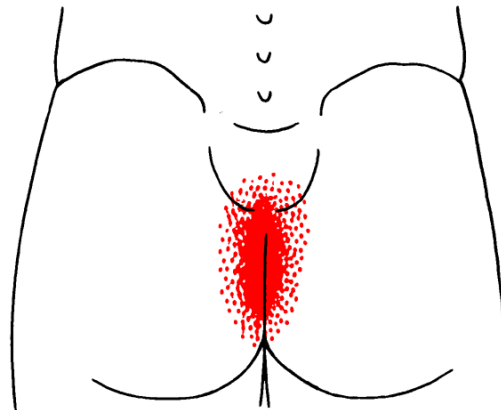
Protocol for Intrarectal Coccygeal Evaluation and Management

James J. Lehman, DC

37. You may find one to six trigger points in the levator ani, coccygeus, and obturator internus on each side.

38. You must examine and treat bilaterally.

39. Normally, a reduced severity occurs while applying the pressure.



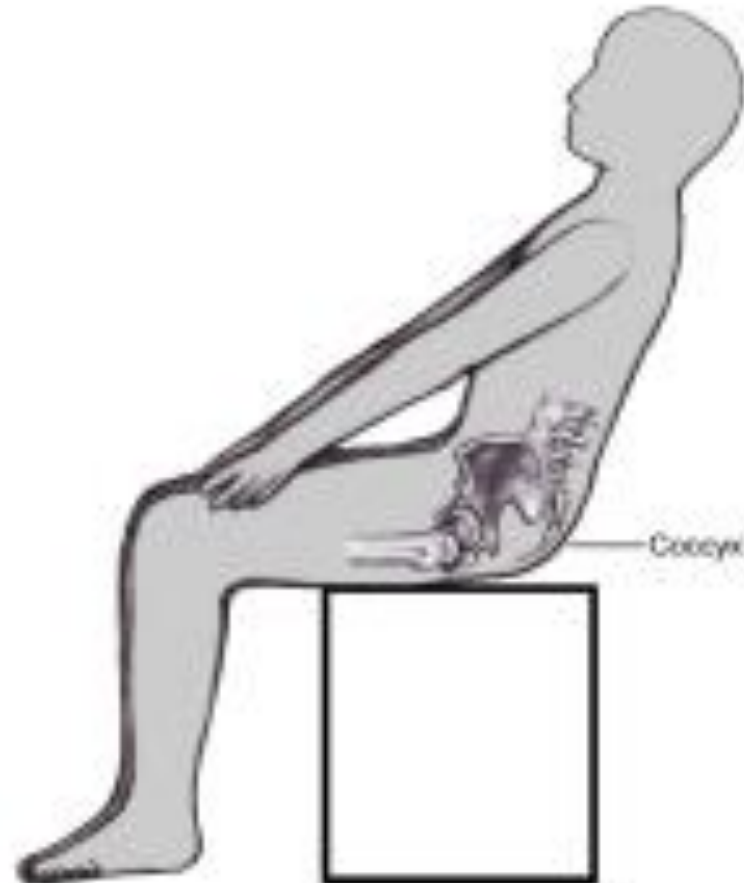
Protocol for Intrarectal Coccygeal Evaluation and Management

James J. Lehman, DC

40. Upon completion of the exam and treatment, ask the patient if she is ok and then advise her the procedure is completed.

41. The patient may prefer to use the restroom facility immediately post treatment.

42. Examine for pain reduction by asking the patient to sit on a firm surface in extension.




Protocol for Intrarectal Coccygeal Evaluation and Management

James J. Lehman, DC

43. An appropriate response to care will permit the patient to sit with a complete relief of pain or a significant reduction in severity.



44. Oftentimes, one or two treatments resolve coccygodynia.







Read, Discuss, and Present

- Read article by Jean-Yves Maigne MD, “Management of Common Coccygodynia”
- Decide appropriate conservative treatment that should be considered prior to coccygectomy
- Present your opinions



Management of Common Coccygodynia Jean-Yves Maigne, MD

- *Because patients often mention a fall on the buttocks or a delivery as precipitating event, a mechanical basis for the pain is likely. In addition, in the majority of cases, the pain occurs only in the sitting position. These factors led us to develop a protocol to document the painful coccyx with dynamic films and coccygeal discography (Maigne et al 1992, 1994).*



Management of Common Coccygodynia

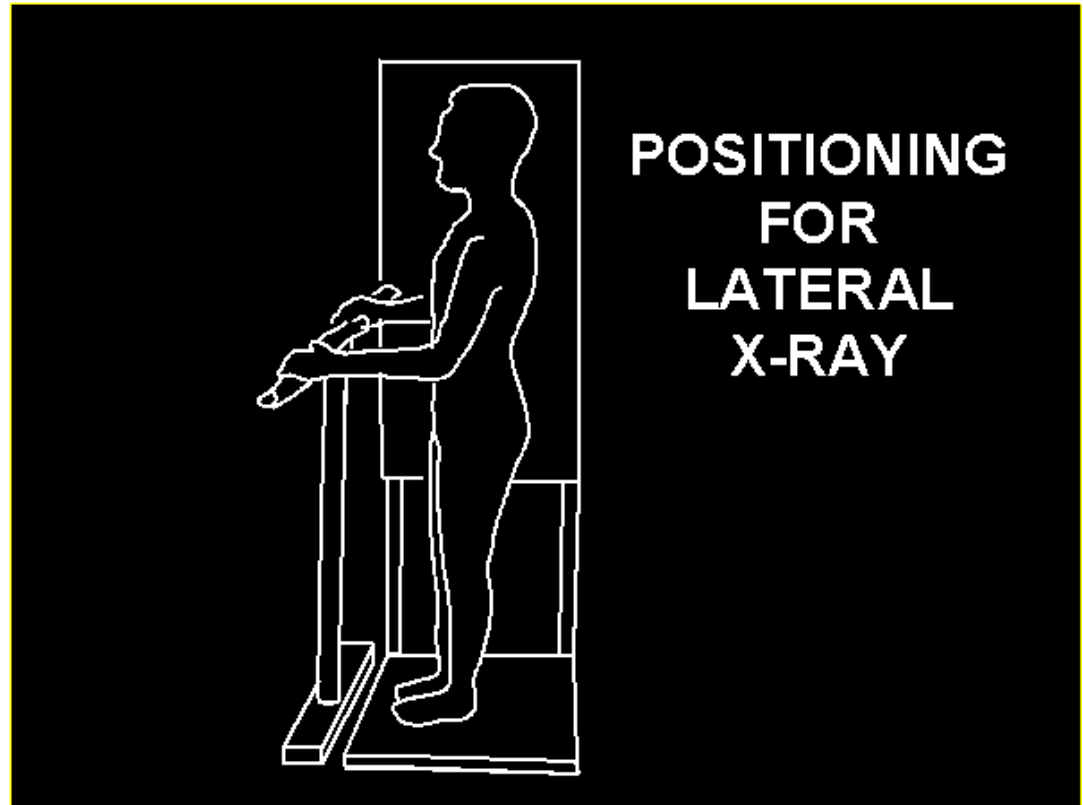
Jean-Yves Maigne, MD

- *Dynamic films are defined as X-rays films in the lateral sitting position (the painful position) as compared with standard lateral roentgenograms. Since 1992, more than 700 patients with coccygeal pain have undergone this protocol.*

Management of Common Coccygodynia

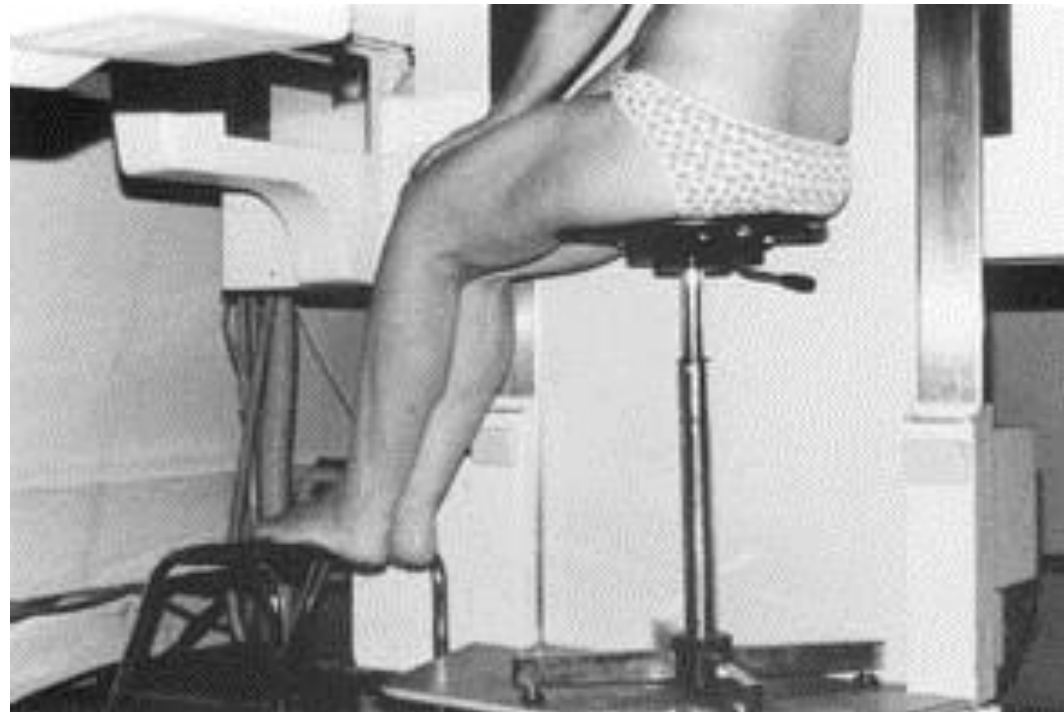Jean-Yves Maigne, MD

The first (standard) film is taken in the lateral standing position. In order for the coccyx to be in a neutral position, it is very important for the patient to avoid sitting for the five to ten minutes preceding the X-rays examination. Otherwise, in some cases of hypermobility or luxation, there is not time enough for the coccyx to come back into the neutral position.



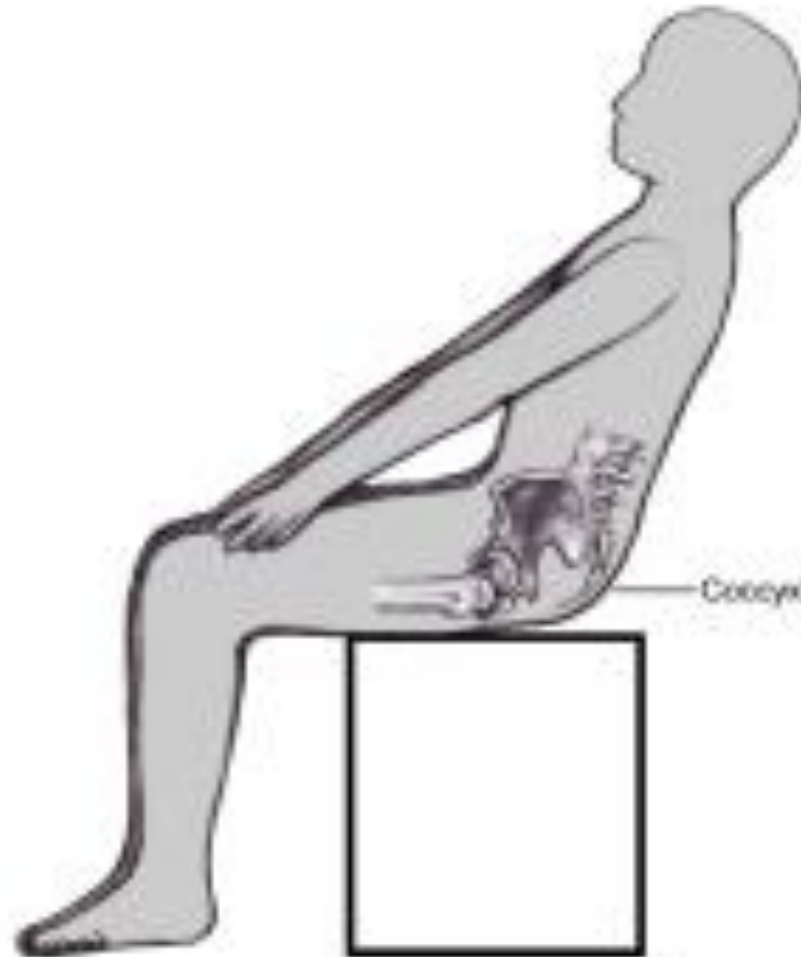
Management of Common
Coccygodynia
Jean-Yves Maigne, MD

The correct
position to X-
ray the coccyx
in a sitting
posture.
Note the foot
rest.



Management of Common
Coccygodynia
Jean-Yves Maigne, MD

Passive flexion is due to the direct pressure of the seat over the coccyx. In other cases, a passive extension is encountered, which is due to an increased intra-pelvic and abdominal pressure by the seat. The direction is depending on the coccygeal anatomy.

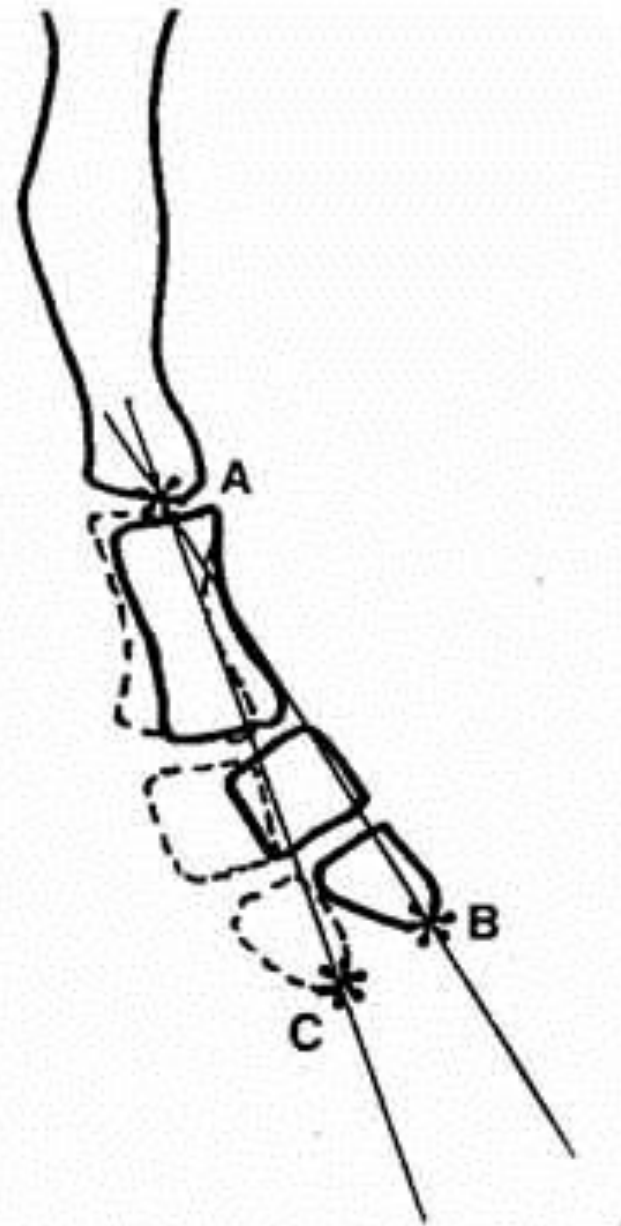


Management of Common Coccygodynia

Jean-Yves Maigne, MD

Range of motion of the coccyx is measured in degrees (angle ABC).
Bold line : standard film.
Dotted line : coccyx in the sitting position.

A: apex of the angle located at the caudal part of the sacrum (or of the first coccygeal vertebra if the sacro-coccygeal disc is ossified).

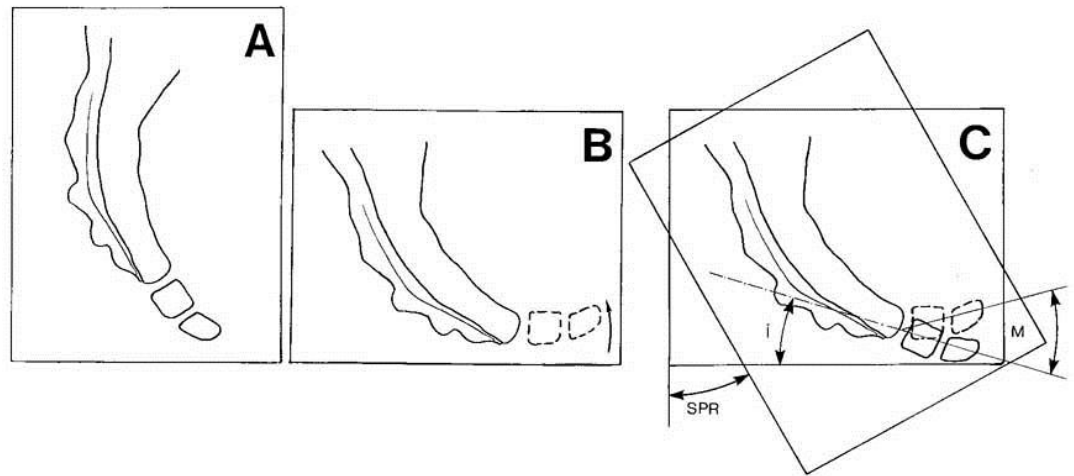


Management of Common
Coccygodynia
Jean-Yves Maigne, MD

Flexion larger than 25-30
degrees represents
hypermobility.

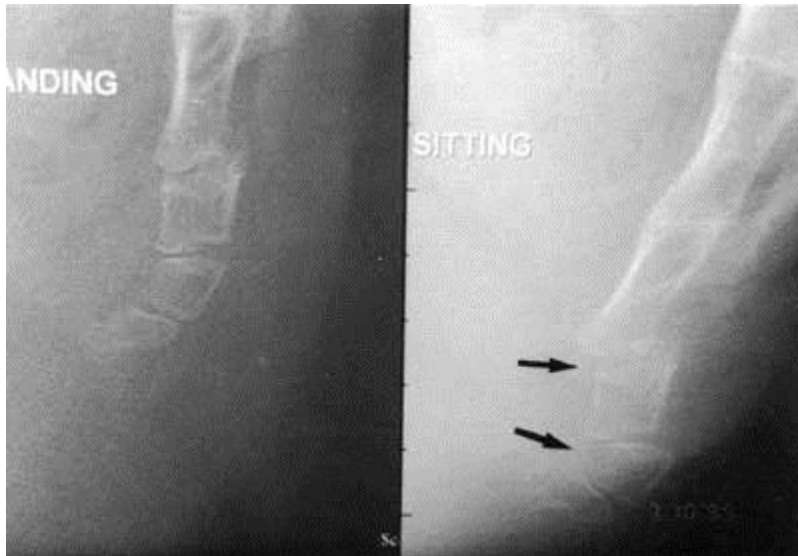
Larger than 25%
represents **luxation.**

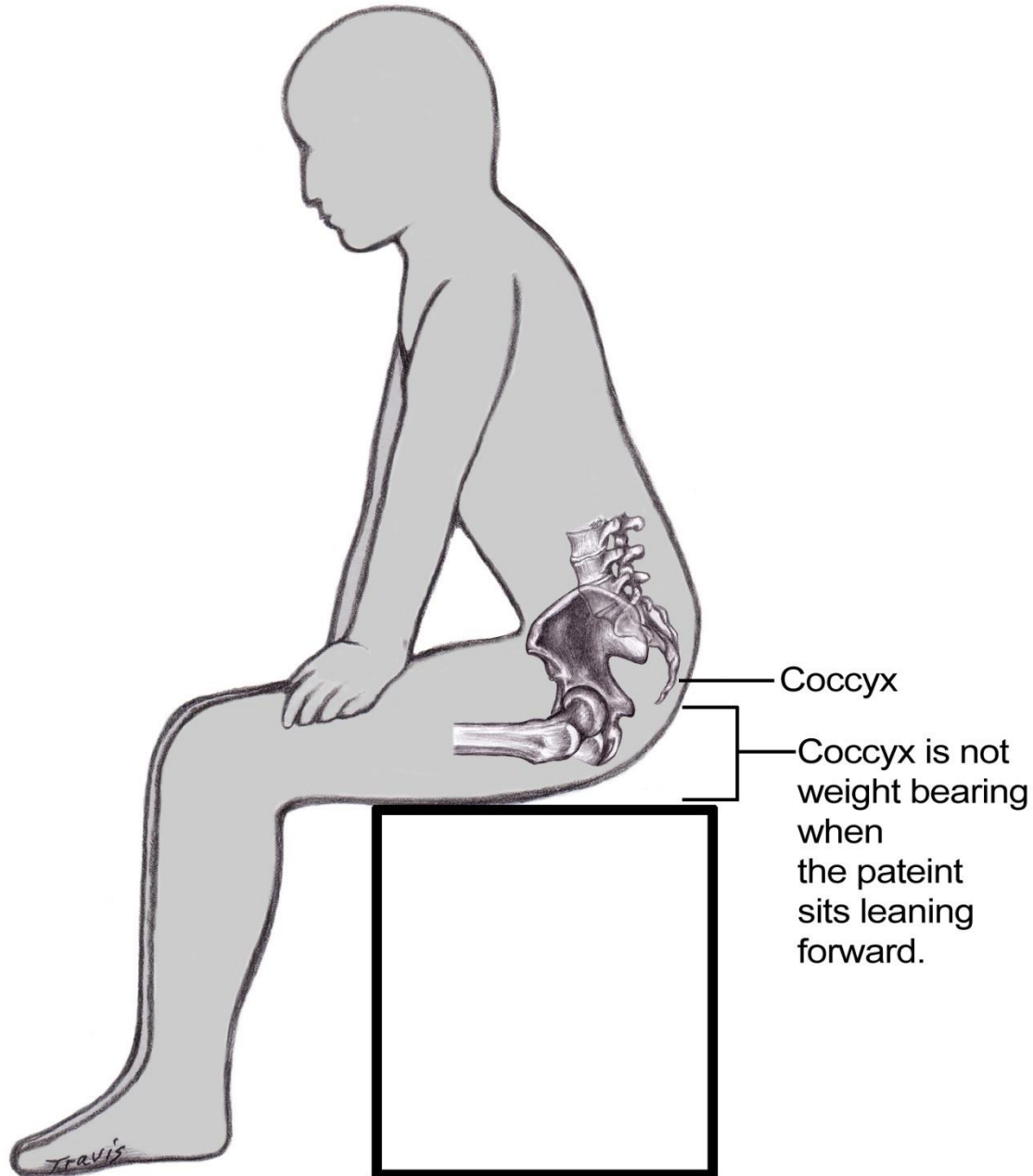
Extension larger than
15-20 degrees is also
pathologic, but it is a
very rare situation.



Characteristics of patients with luxation

- Body Mass Index is statistically higher.
- History of direct and violent trauma to the coccyx prior to the pain
- Acute pain while passing from the sitting to the standing position,
- More intense with sitting position



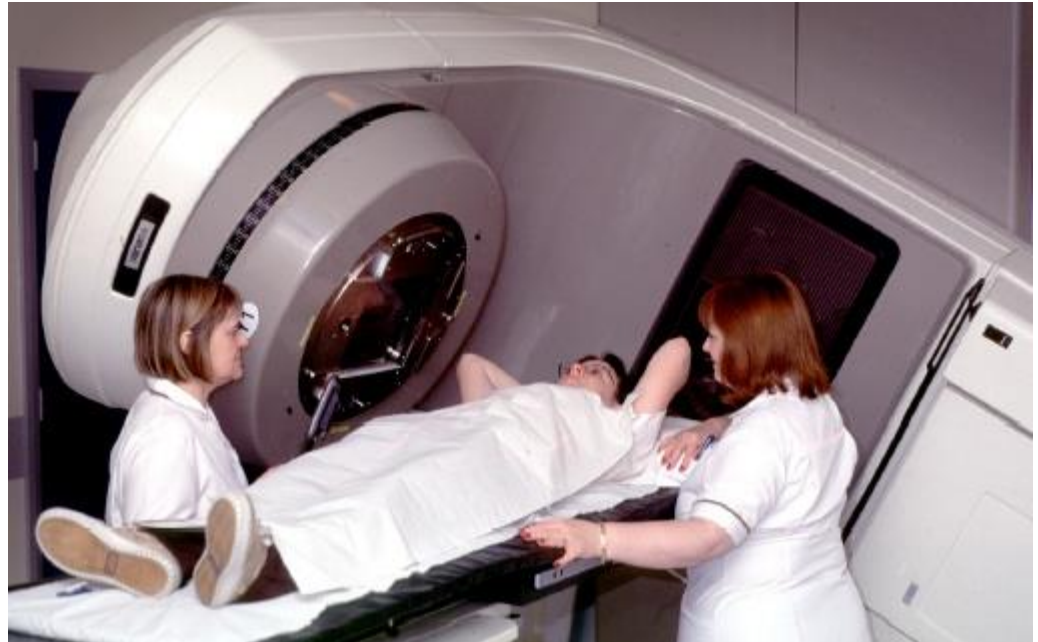

Coccyx

Coccyx is not weight bearing when the pateint sits leaning forward.

Coccygectomy: an effective treatment option for chronic coccydynia Trollegaard, Aarby, and Hellberg

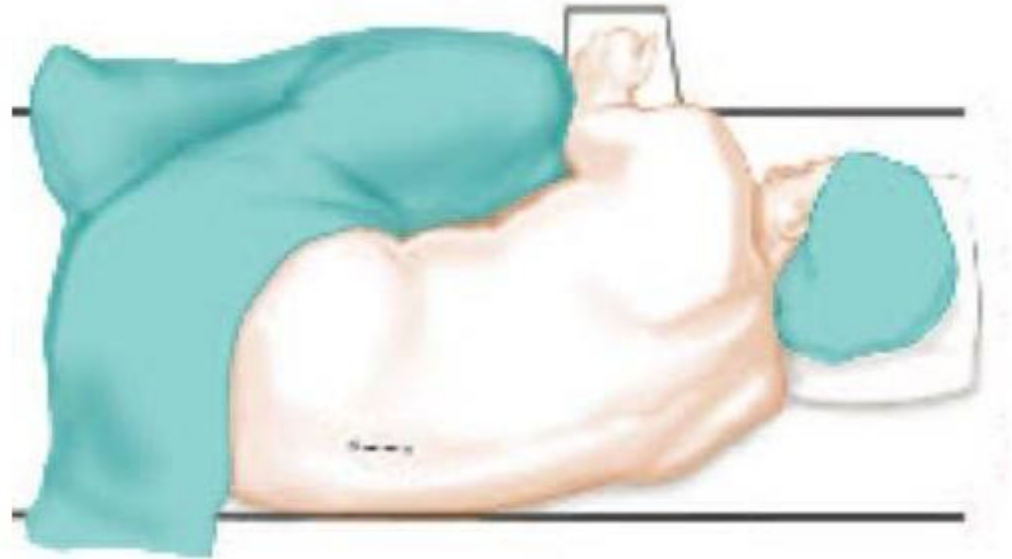
Conservative management is successful in about 90% of patients using an assortment of treatments, including nonsteroidal anti-inflammatory drugs, hot baths, ring-shaped cushions, manual therapy, massage, injections of local anaesthetic with corticosteroid, radiotherapy and psychotherapy.





Management of Common Coccygodynia

Jean-Yves Maigne, MD

Manual treatments consist in either manipulations of the coccyx or massages of the pelvic muscles (levator ani or piriformis). This is a very classic treatment of coccygeal disorders. In an open study by Wray et al, adding manipulation to injection treatment produced a 25% increase in the rate of satisfactory results.





THANK
YOU