

Internal Derangement of the Knee


James J. Lehman, DC, MBA, FACO

Director

Health Sciences Postgraduate Education Department


University of Bridgeport






Learning Objectives

- Correlate anatomy and the patients' signs and symptoms in order to locate the neuromusculoskeletal lesions of the knee and properly record the findings.




Learning Objectives

- Elicit a patient history and record the subjective findings in order to perform differential diagnosis procedures and determine use of objective testing.




Learning Objectives

- Perform neuromusculoskeletal evaluation procedures (Posture, orthopedic and neurological) and record the objective findings in order to make an assessment/diagnosis.




Learning Objectives

- Organize a clinical thought process while performing a neuromusculoskeletal evaluation.
- Identify injured and painful tissues through careful assessment and intelligent use of neuromusculoskeletal testing and document the findings.

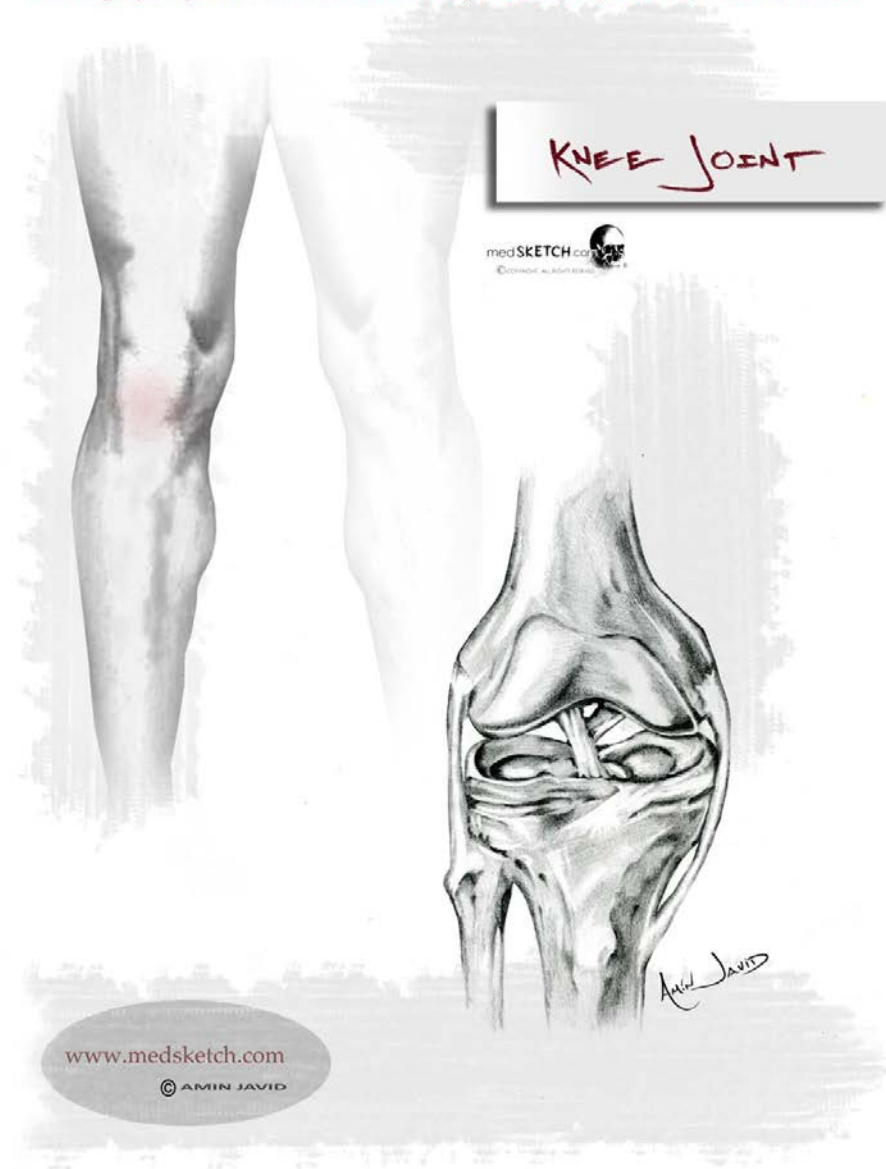

Opening Statement ...



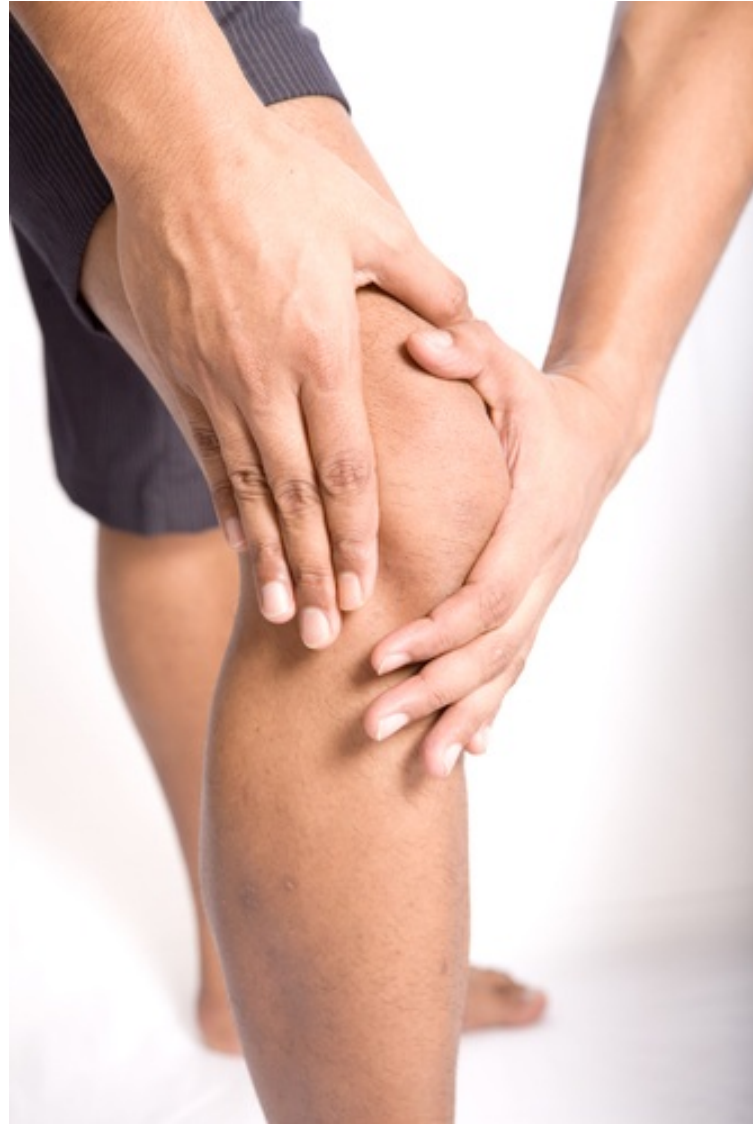- Diagnosis is the key to successful treatment!

Knee pain
accounts for
approximately
one third of
musculoskeletal
problems seen
in primary care
settings.



Knee pain is most prevalent in physically active patients, with as many as 54 percent of athletes having some degree of knee pain each year.

Rosenblatt RA, Cherkin DC, Schneeweiss R, Hart LG. The content of ambulatory medical care in the United States. An interspecialty comparison. *N Engl J Med.* 1983;309:892-7.



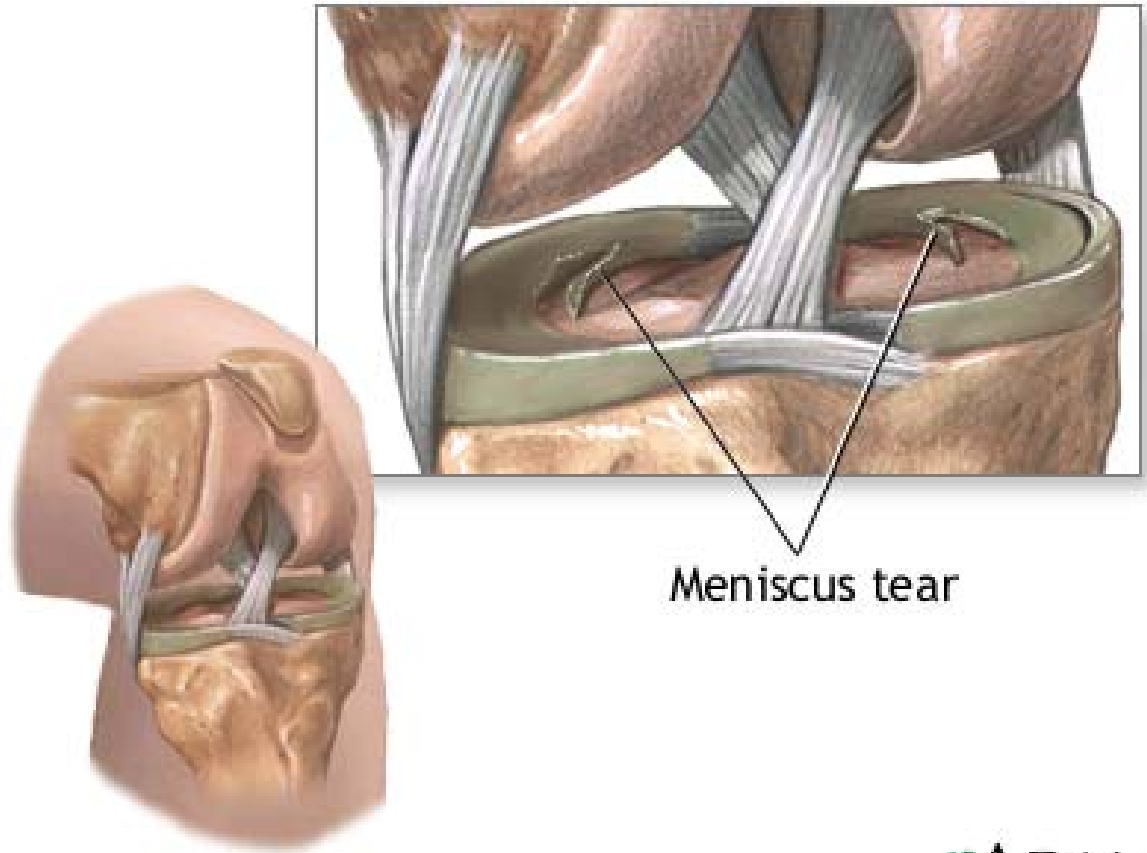
The abbreviation, “IDK” often means “I don’t know” rather than internal derangement of the knee.

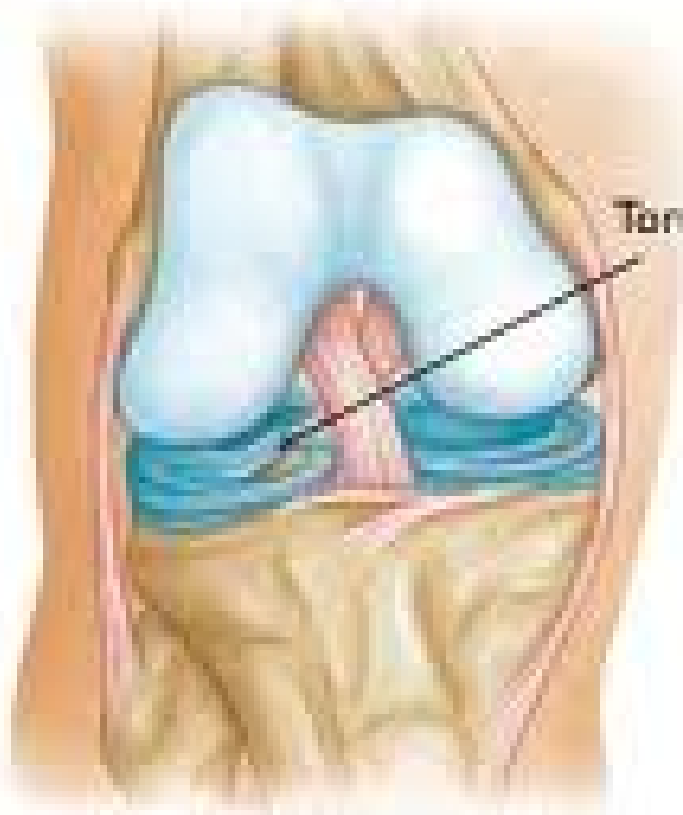


Internal Derangement of the Knee

ICDA Codes 717

Internal derangement of the knee (IDK) is the term used to cover a group of disorders involving disruption of the normal functioning of the ligaments or cartilages (menisci) of the knee joint.





Torn Meniscus

Meniscal Tears



Normal Meniscus



Longitudinal




Bucket Handle



Flap

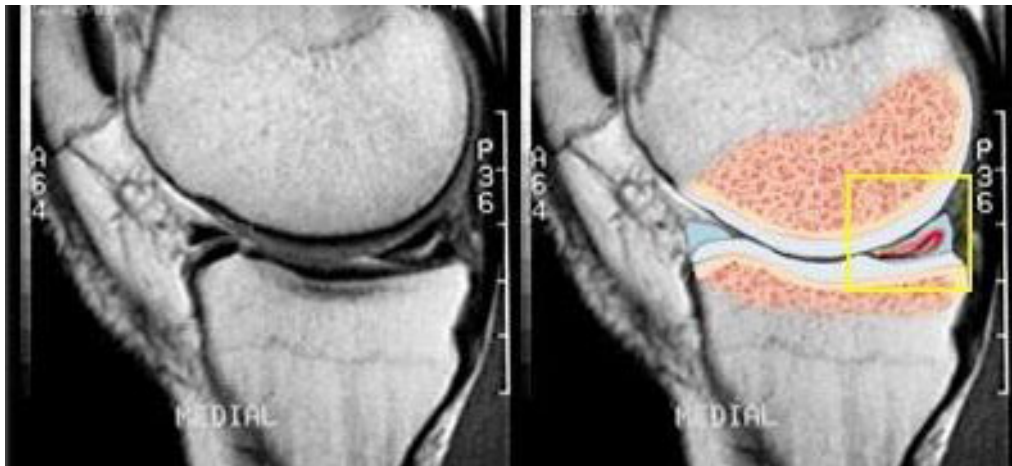


Transverse



Torn Horn

Unspecified Internal Derangement of Knee



**2014 ICD-9-CM
Diagnosis Code
717.9 (Final
Revision)**

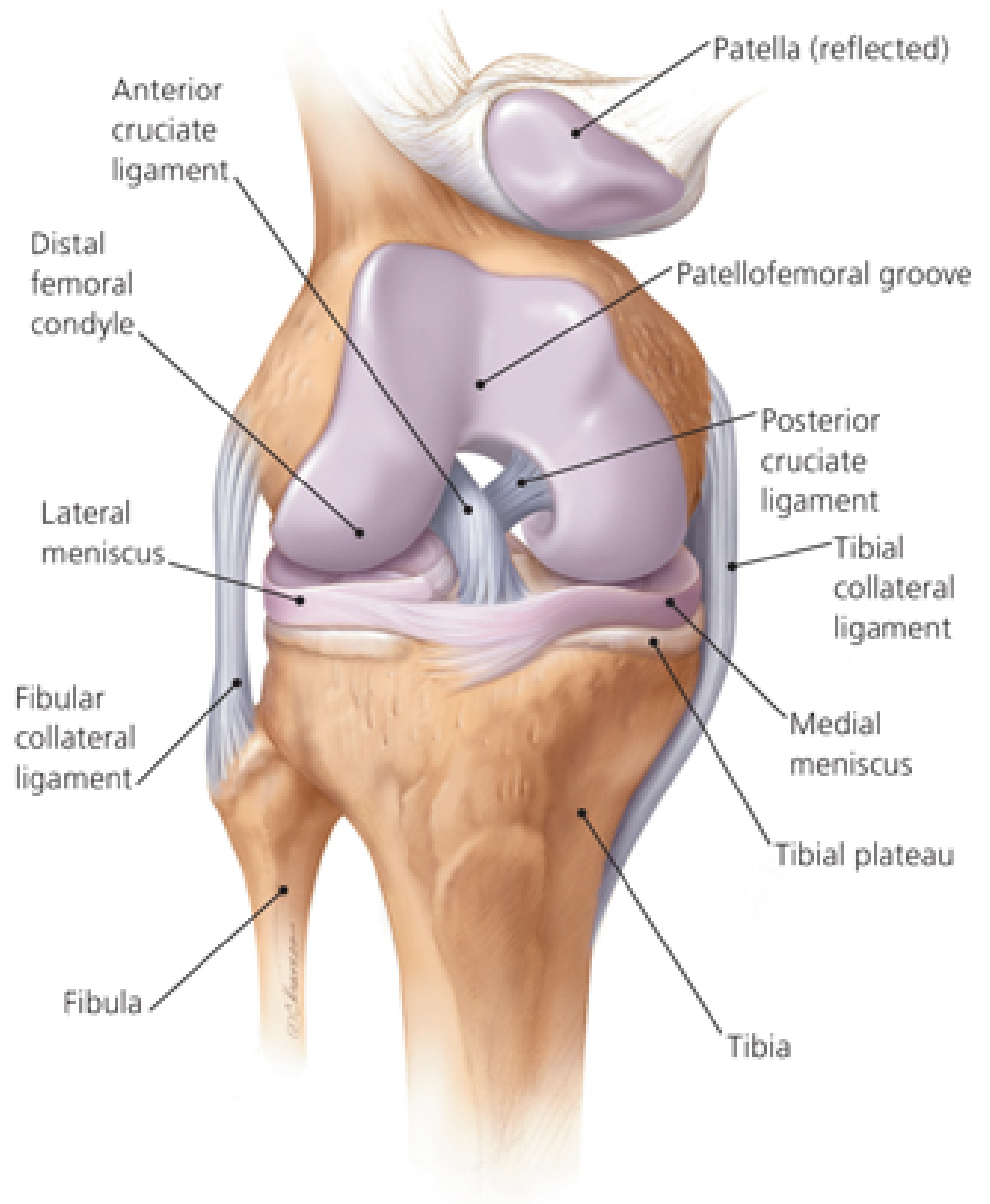
American Family
Physician

Evaluating Acutely
Injured Patients for
Internal
Derangement of the
Knee.

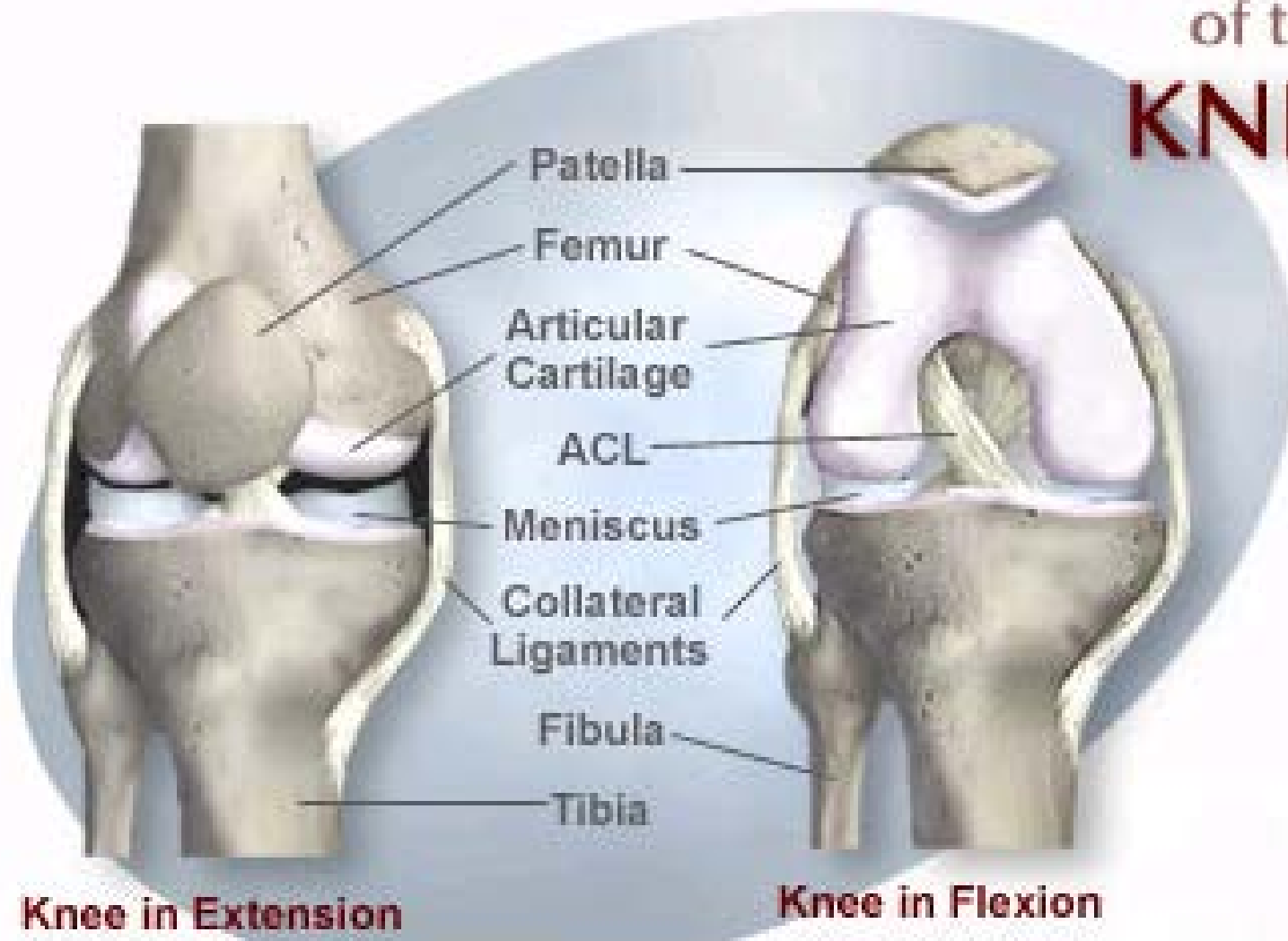*Am Fam
Physician.* 2012 Feb 1;85(3):247-
252.

MICHAEL GROVER, DO, Mayo
Clinic College of Medicine,
Scottsdale, Arizona

[http://www.aafp.org/afp/2012/0201/
p247.html](http://www.aafp.org/afp/2012/0201/p247.html)



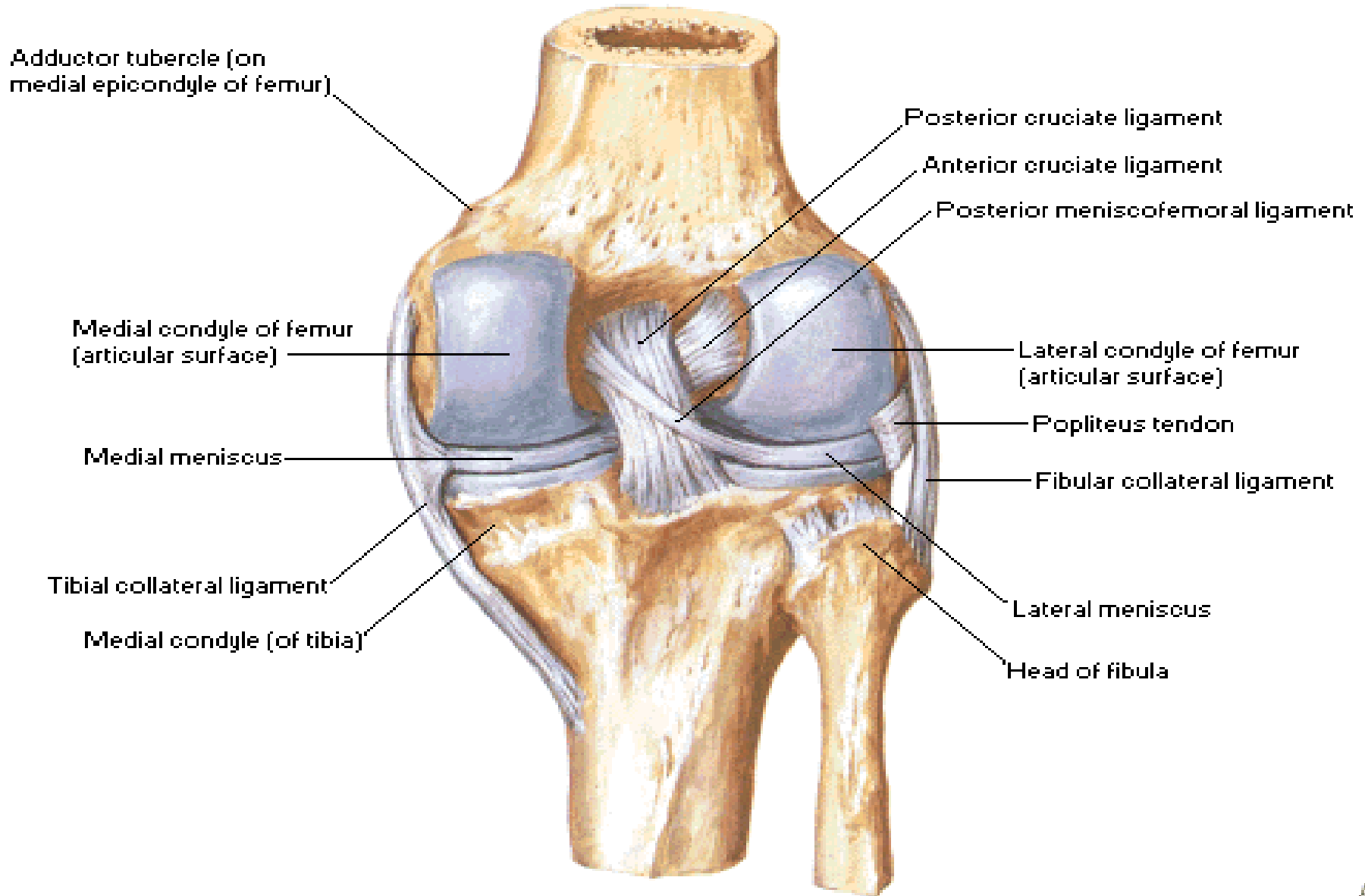
Anatomy of the **KNEE**



Graphic Courtesy of the
Southern California Orthopedic Institute.

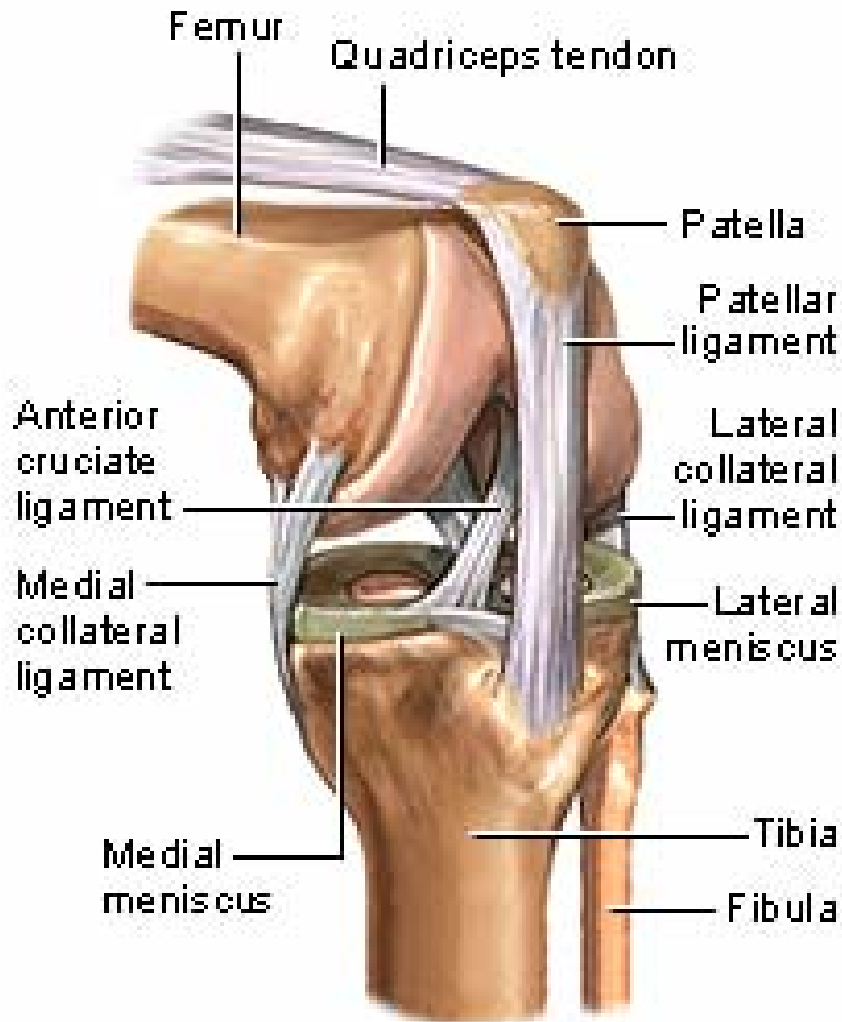
Knee - Cruciate and Collateral Ligaments

Right Knee in Extension

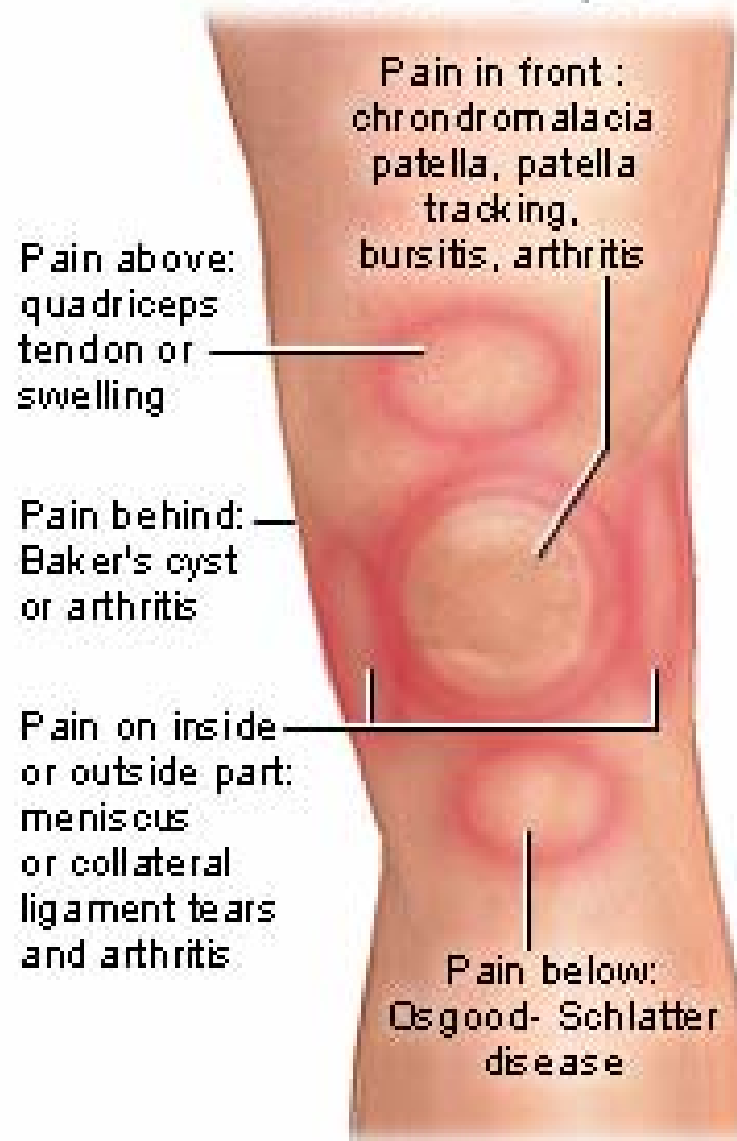


Posterior View

Normal anatomy



Location of pain





History:

Painful Tissue

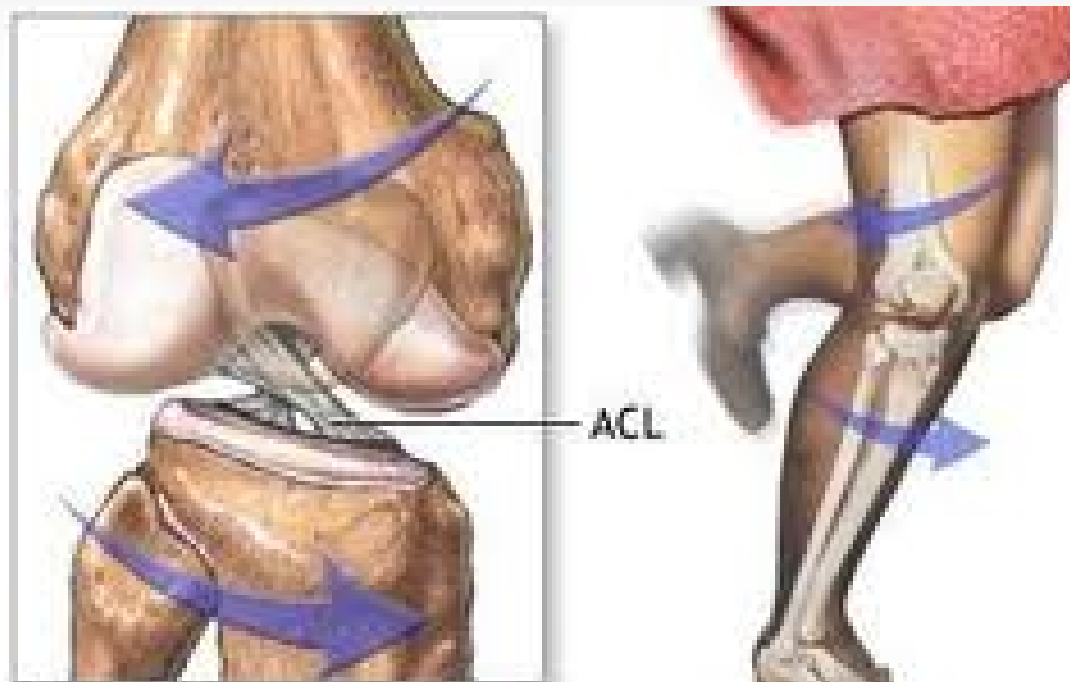Identification Check List

- ✓ Ask the patient to point to the pain
- ✓ When did the pain commence?
- ✓ Trauma?
- ✓ What makes it better or worse?
- ✓ Quality of the pain
- ✓ Radiating or localized?
- ✓ Pain severity rating
- ✓ When is it painful
- ✓ Treatments and reaction?
- ✓ Previous diagnoses?






ACL Sprain Mechanism of Injury




ACL injuries occur when bones of the leg twist in opposite directions under full body weight

ADAM



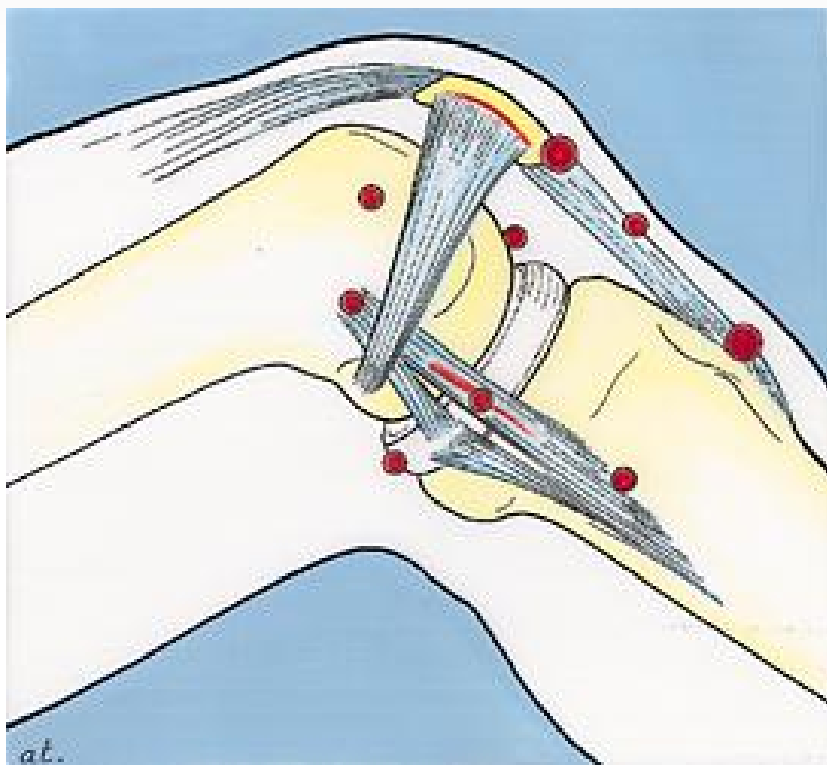
Generalized Pain Description

- **Joint pain** may be constant dull, deep ache but sharp upon motion
- **Muscle pain** may be a dull ache, crampy or spasm sensation
- **Trigger points** may be localized with pin point pain or diffuse with poor localization and paresthesias (formication)



Knee Pain

Can you identify the condition with the point of pain?



- Osgood Schlatter's Disease?
- Jumper's knee?
- PFA?
- Collateral ligament sprain?
- Meniscal tear?

Examination Protocols

1. History taking or interview
2. Observation and inspection
3. Palpation
4. Range of motion
5. Special tests
6. 3 part-PNS exam
7. Imaging

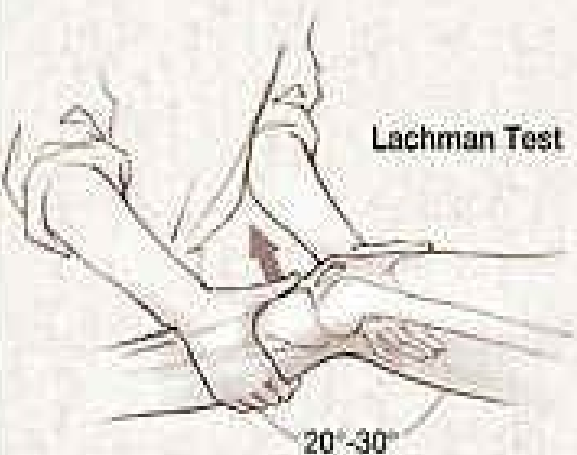


Orthopedic test

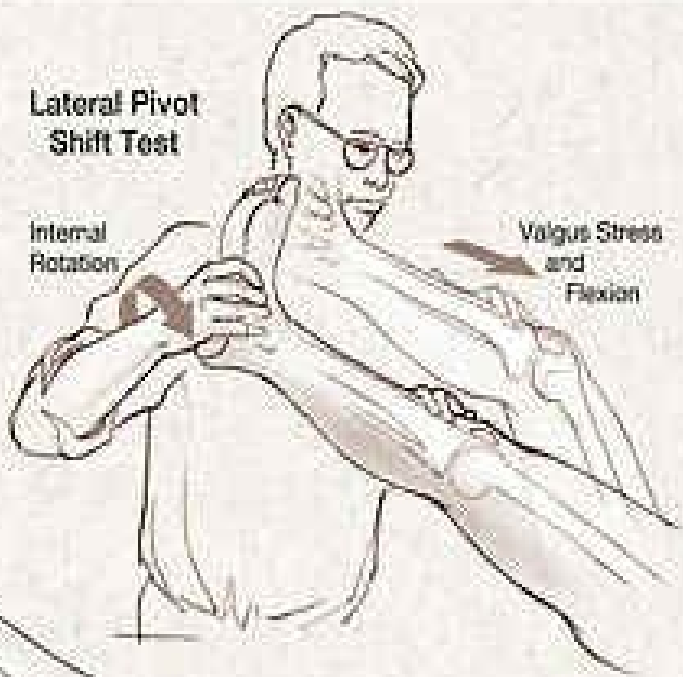A provocative maneuver (most often) using stretching, compressing, and contracting to duplicate the pain and identify the involved tissues.



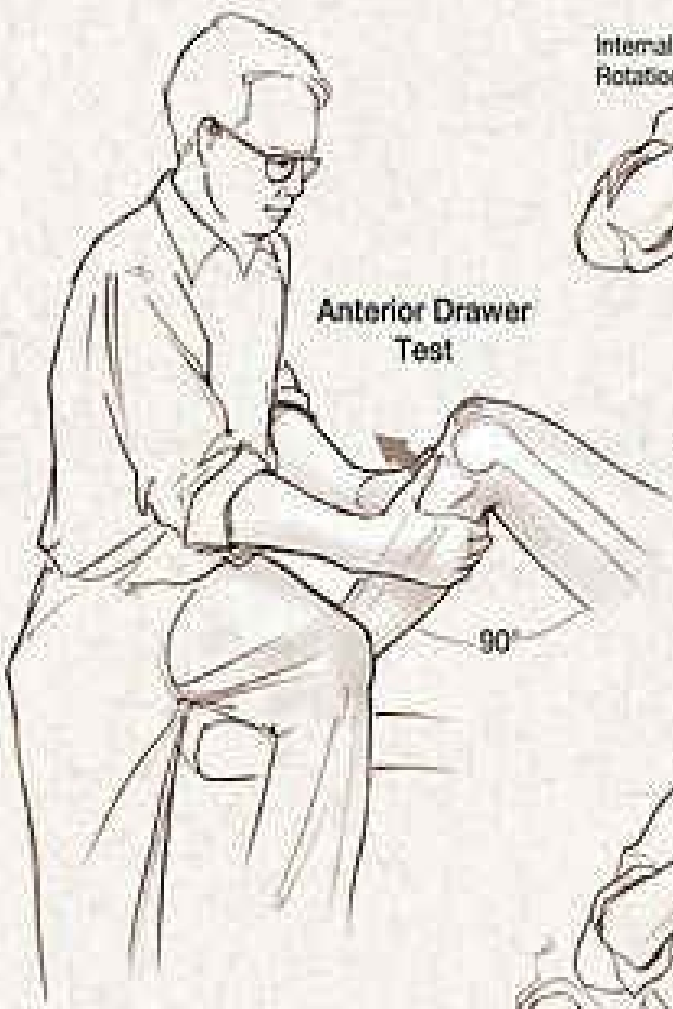
Lachman Test



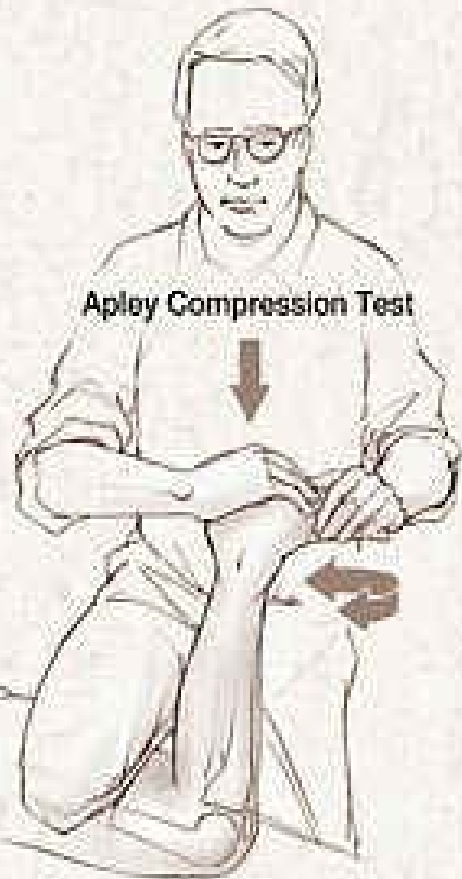
Lateral Pivot Shift Test



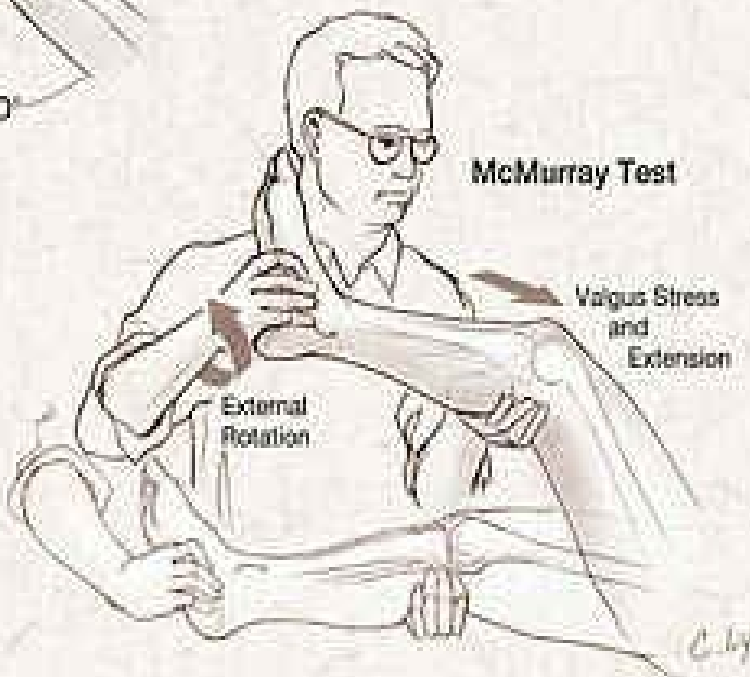
Anterior Drawer Test



Apley Compression Test



McMurray Test




Diagnostic accuracy of a new clinical test (the Thessaly test) for early detection of meniscal tears. J Bone Joint Surg Am. 2005 May;87(5):955-62.
Available from: <http://www.ncbi.nlm.nih.gov/pubmed/15866956>

- The Thessaly test at 20 degrees of knee flexion had a high diagnostic accuracy rate of 94% in the detection of tears of the medial meniscus and 96% in the detection of tears of the lateral meniscus, and it had a low rate of false-positive and false-negative recordings. Other traditional clinical examination tests, with the exception of joint-line tenderness, which presented a diagnostic accuracy rate of 89% in the detection of lateral meniscal tears, showed inferior rates.

TABLE II Values for Diagnostic Parameters of the Clinical Examination Tests

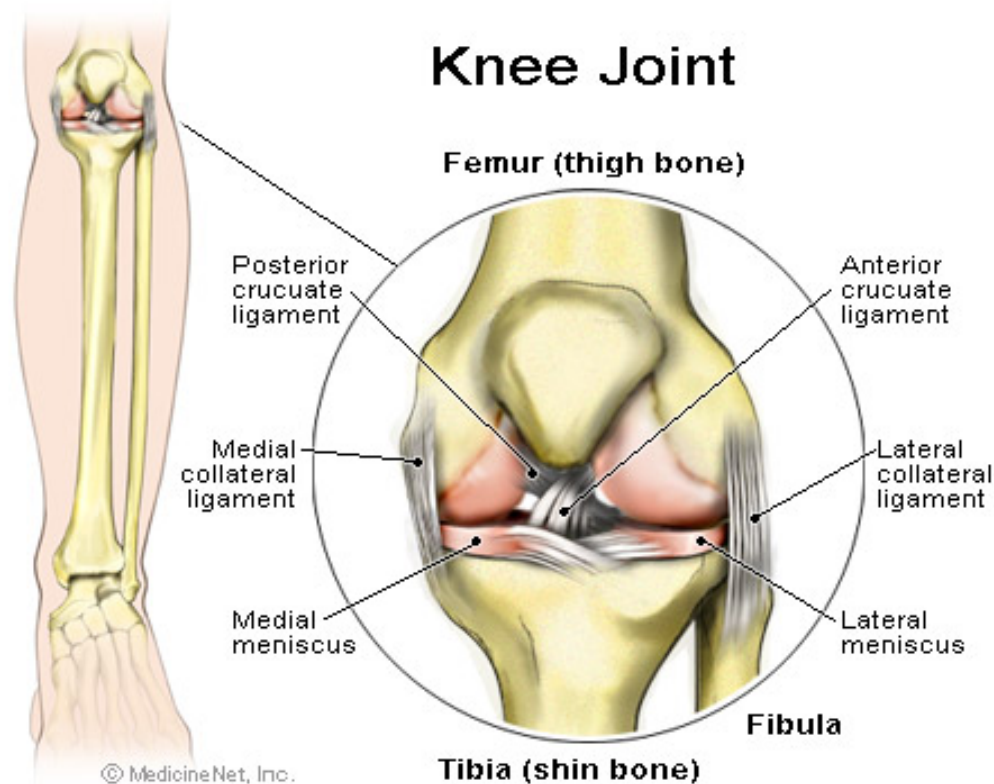
Test	Diagnosis		
	Injury of Medial Meniscus	Injury of Lateral Meniscus	Combined Injury of Anterior Cruciate Ligament and Meniscus
McMurray test			
Sensitivity	48%	65%	45%
Specificity	94%	86%	76%
False positive	4.2%	12.4%	23%
False negative	17.6%	3.2%	2.7%
Accuracy	78%	84%	74%
Apley test			
Sensitivity	41%	41%	20%
Specificity	93%	86%	84%
False positive	4.6%	13%	38%
False negative	20%	5.4%	4%
Accuracy	75%	82%	59%
Joint-line tenderness			
Sensitivity	71%	78%	65%
Specificity	87%	90%	80%
False positive	8.8%	9.3%	19%
False negative	10%	2%	1.7%
Accuracy	81%	89%	80%
Thessaly test at 5° of flexion			
Sensitivity	66%	81%	65%
Specificity	96%	91%	83%
False positive	2.9%	8%	17.6%
False negative	11.4%	1.7%	1.7%
Accuracy	86%	90%	82%
Thessaly test at 20° of flexion			
Sensitivity	89%	92%	80%
Specificity	97%	96%	91%
False positive	2.2%	3.7%	9%
False negative	3.6%	0.73%	1%
Accuracy	94%	96%	90%





Ligament Injuries

Knee Joint

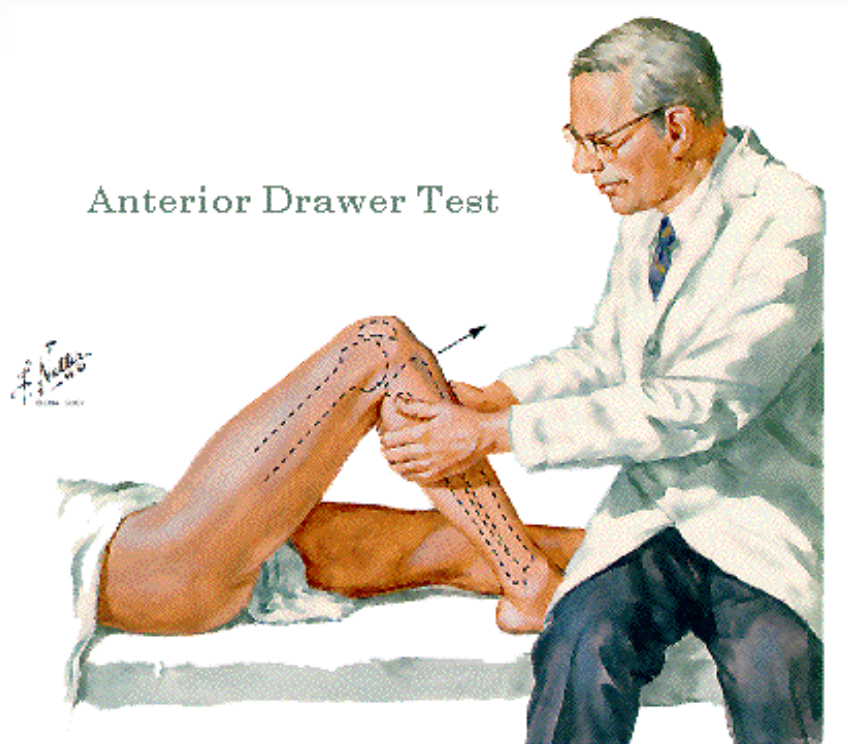
Femur (thigh bone)




Medial collateral and anterior cruciate ligaments are the most commonly injured.



Anterior Drawer Sign

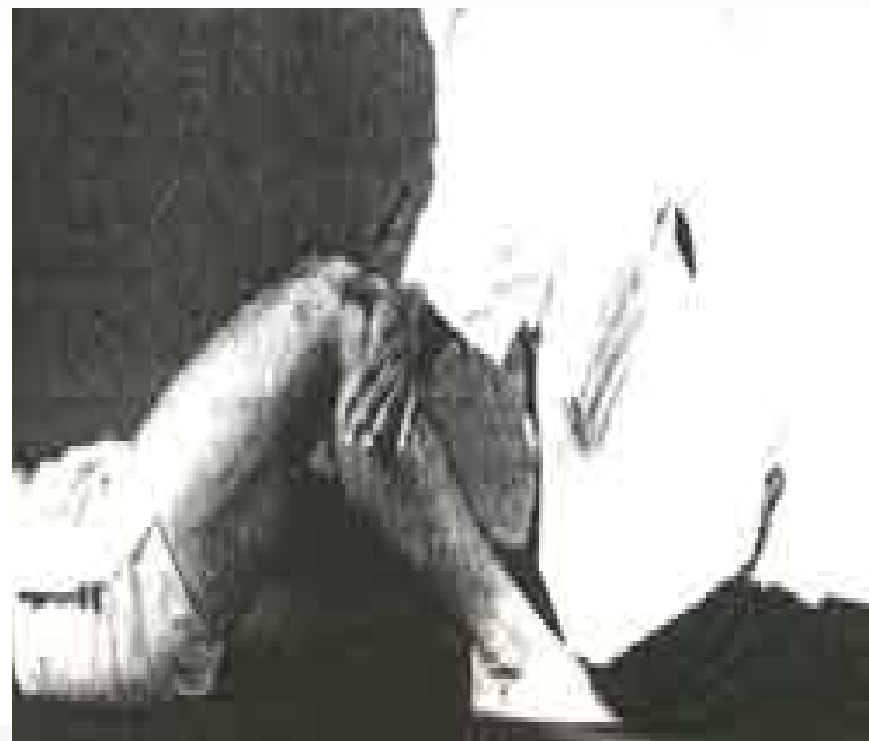


- Anterior cruciate
- Medial collateral ligament
- ITB
- Capsules & ligaments
- Arcuate-politeus complex



Ligament Instability

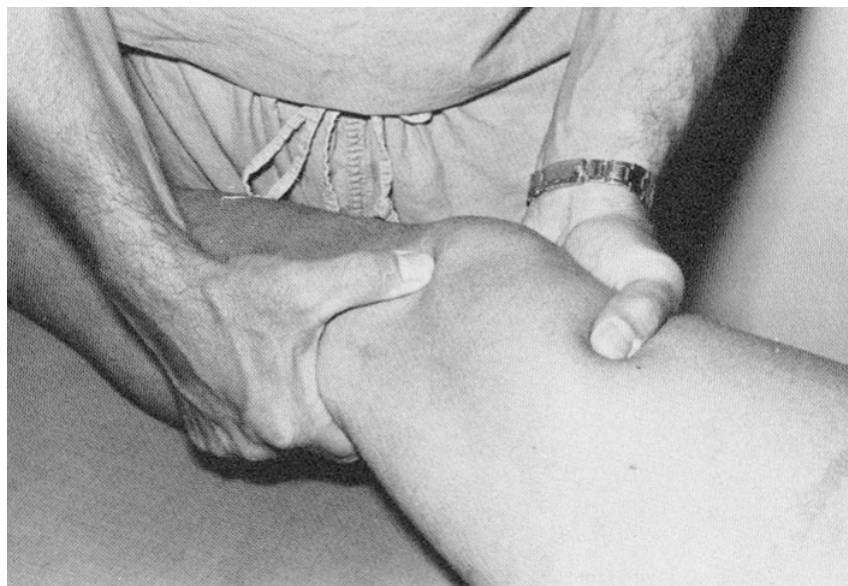Anterior and Posterior Drawer Signs





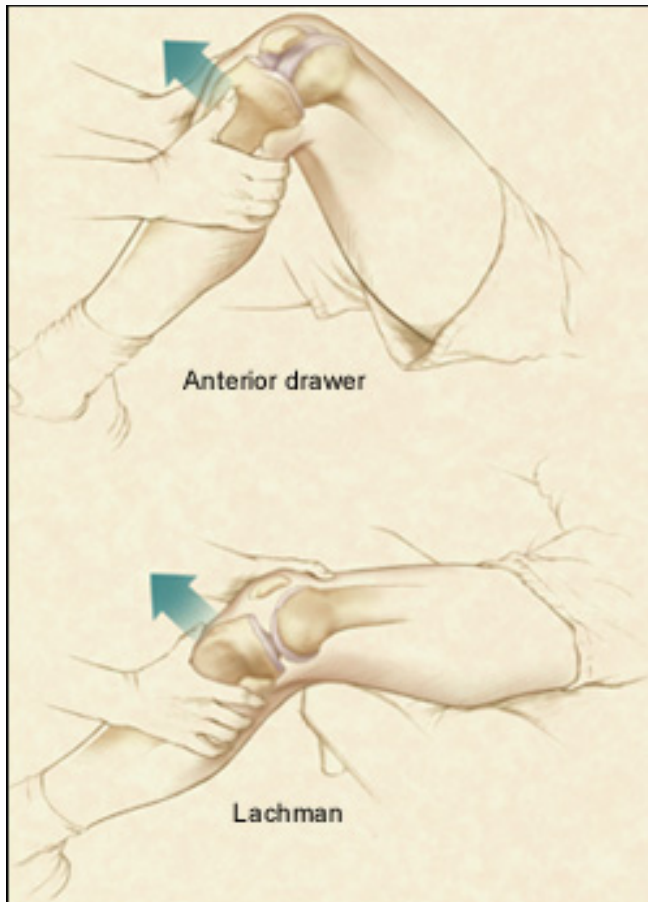
Ligament Instability

Lachman's Test




- Anterior and posterior cruciate ligament sprains
- Most reliable test for anterior cruciate ligament rupture

Anterior Drawer Sign and Lachman's Anterior Cruciate & Posterior Oblique

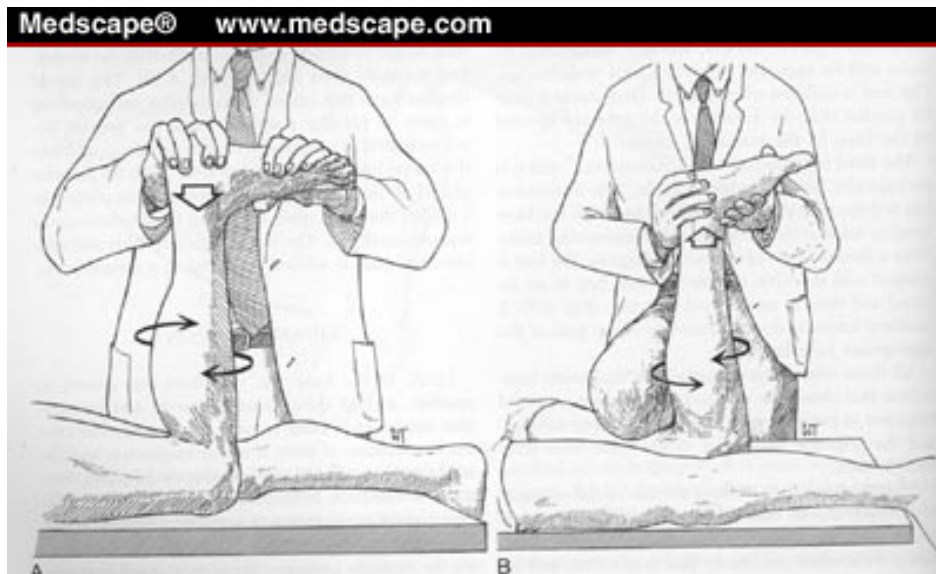


© 2000 Christy Kramas

- Anterior translation of more than 5 mm indicates injury



Meniscus and Ligament Instability

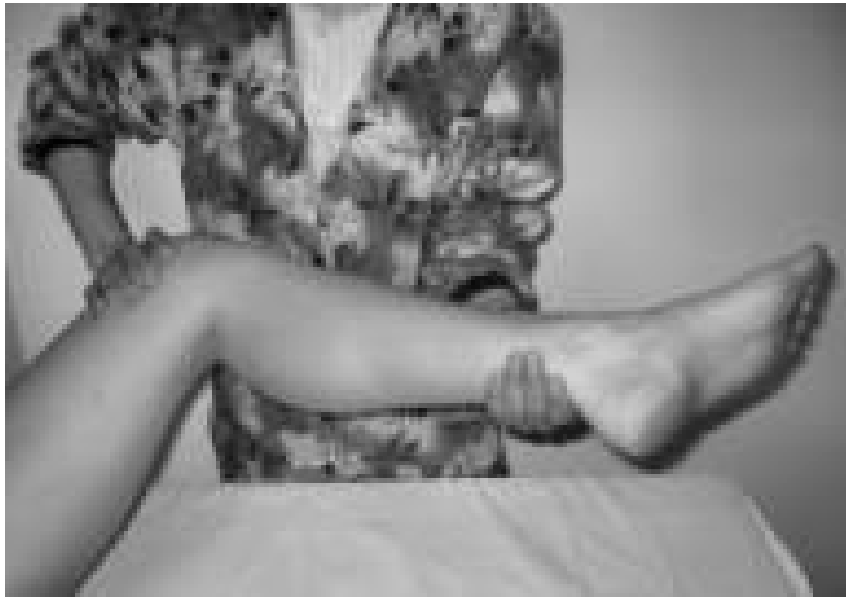

- Apley's compression tests meniscus
- Apley's distraction tests nonspecific ligaments



Meniscal Injury

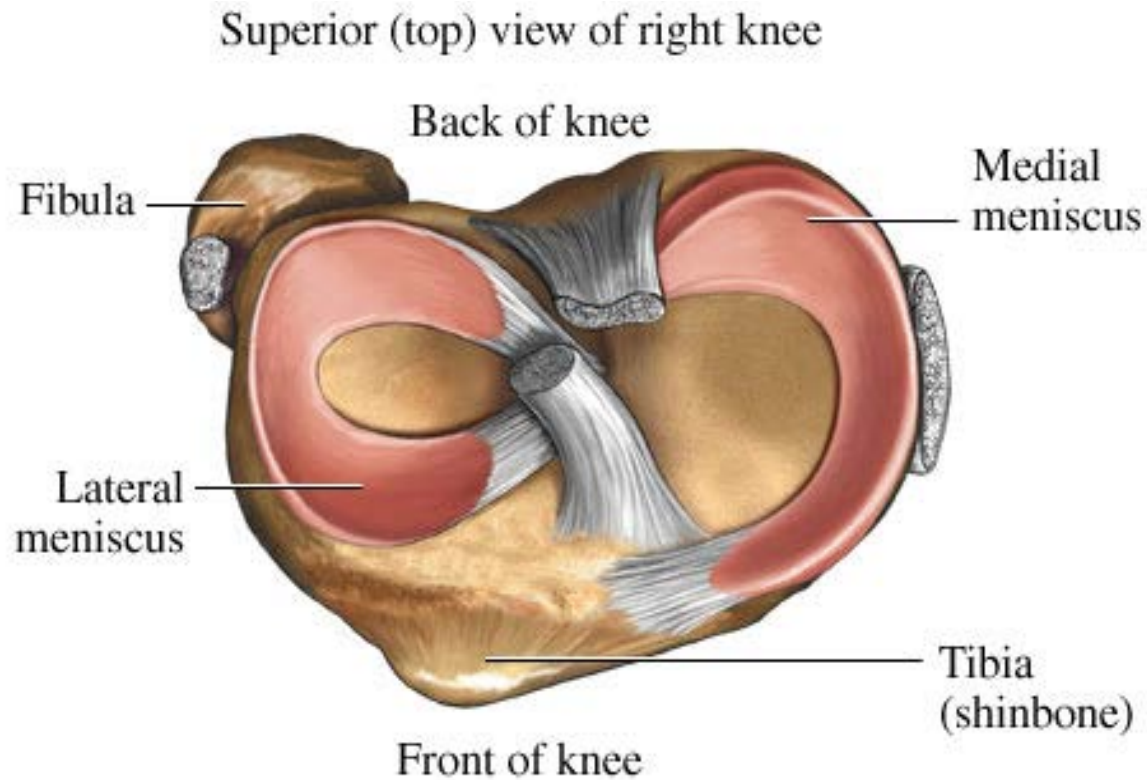
McMurray's Test




- Flex and extend with internal and external rotation.
- Stresses distorted meniscus
- Palpable or audible click is positive

Thessaly's Test

New test for the early detection of meniscal injury.



<http://www.ejbjs.org/cgi/content/abstract/87/5/955>




Thessaly Test for Meniscus Tear

Five degree of knee flexion



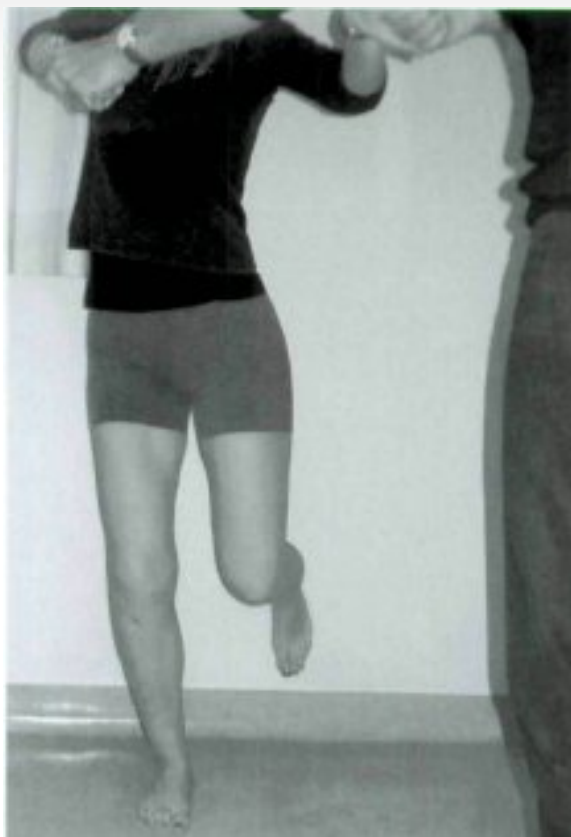Unaffected knee first






Thessaly Test for Meniscal Tear

External rotation assisted



Internal rotation






Thessaly Test for Meniscal Tear

Positive findings


Repeat process at 20 degrees

- Pain medial or lateral
- Clicking or locking
- Most accurate at 20 degrees of knee flexion







Did I mention...




- Diagnosis is the key to successful treatment!



Persistent Anterior Knee Pain

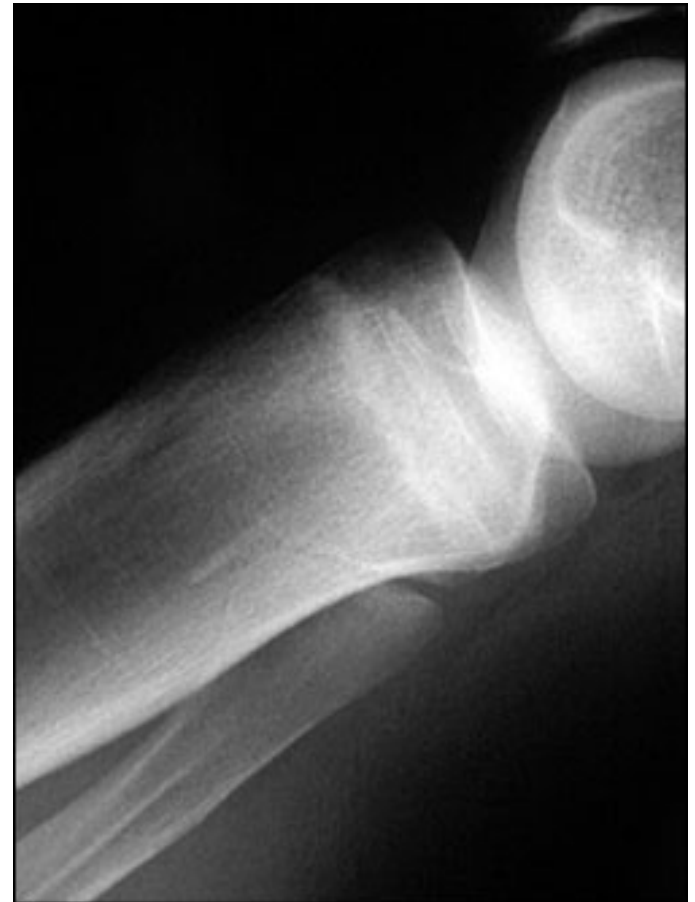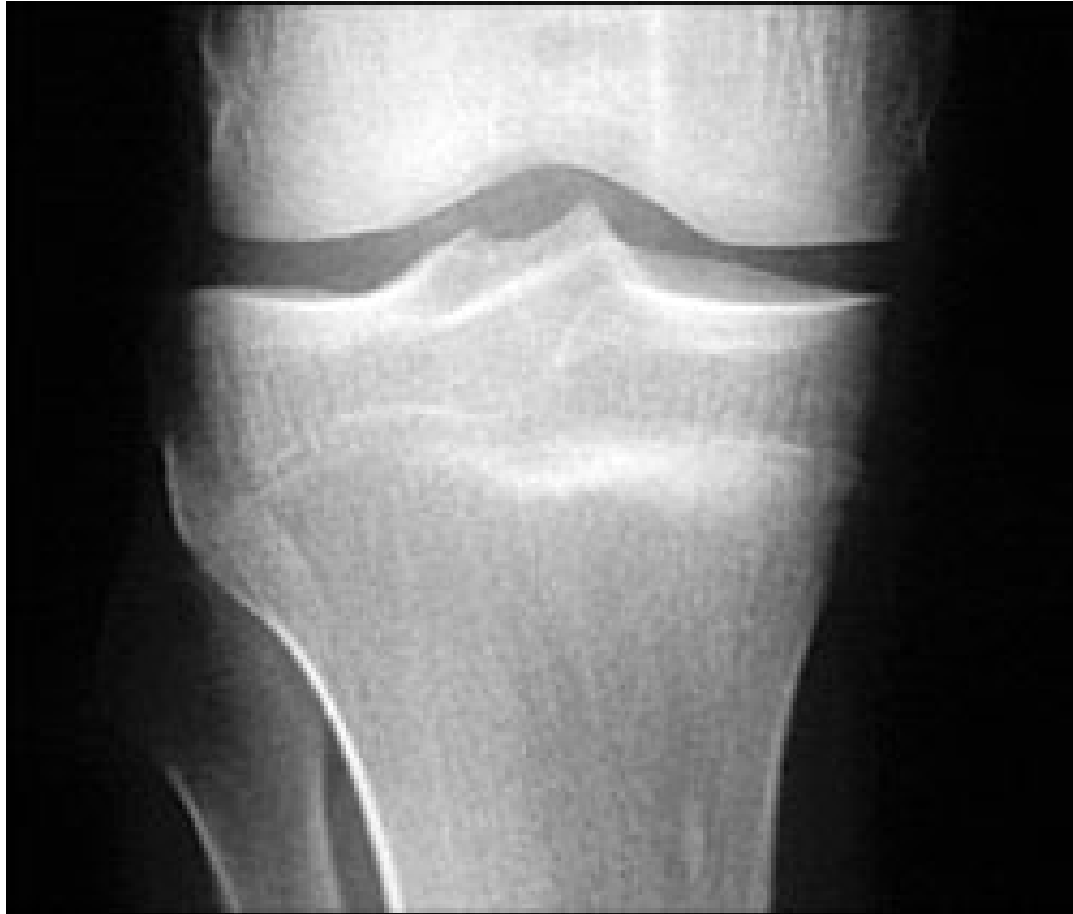- A 20-year-old military recruit presented for follow-up of anterior knee pain. Previously, he presented with three weeks of right knee pain without trauma, swelling, locking, or instability. At that visit, he was referred for physical therapy, but the knee did not improve during treatment. On recent examination, the patient had a positive “theater sign” (i.e., knee pain upon arising after prolonged sitting), positive patellar compression and inhibition tests, stable ligaments, pain with McMurray's test, and tenderness of the medial tibial plateau.



Question

- Based on the patient's history, physical examination, and radiography results, which one of the following is the most likely diagnosis?
- A. Medial plica syndrome.
- B. Patellar tendinopathy.
- C. Patellofemoral pain syndrome.
- D. Pes anserine bursitis.
- E. Proximal tibial stress fracture.

Atraumatic, Persistent, Anterior Knee Pain




Discussion

- The answer is E: proximal tibial stress fracture. Most tibial stress fractures occur in the tibial diaphysis. However, proximal tibial stress fractures, typically involving the medial condyle, can occur in athletes. Stress fractures may result from weaker bone that fails under normal loading (i.e., an insufficiency fracture) or normal bone that fails under new or increased repetitive loading (i.e., a fatigue fracture). Athletes are more likely to experience a fatigue fracture; military recruits are also at risk.


Drabicki RR, Greer WJ, DeMeo PJ. Stress fractures around the knee. *Clin Sports Med.* 2006;25:105–15.

Raasch WG, Hergan DJ. Treatment of stress fractures: the fundamentals. *Clin Sports Med.* 2006;25:29–36.



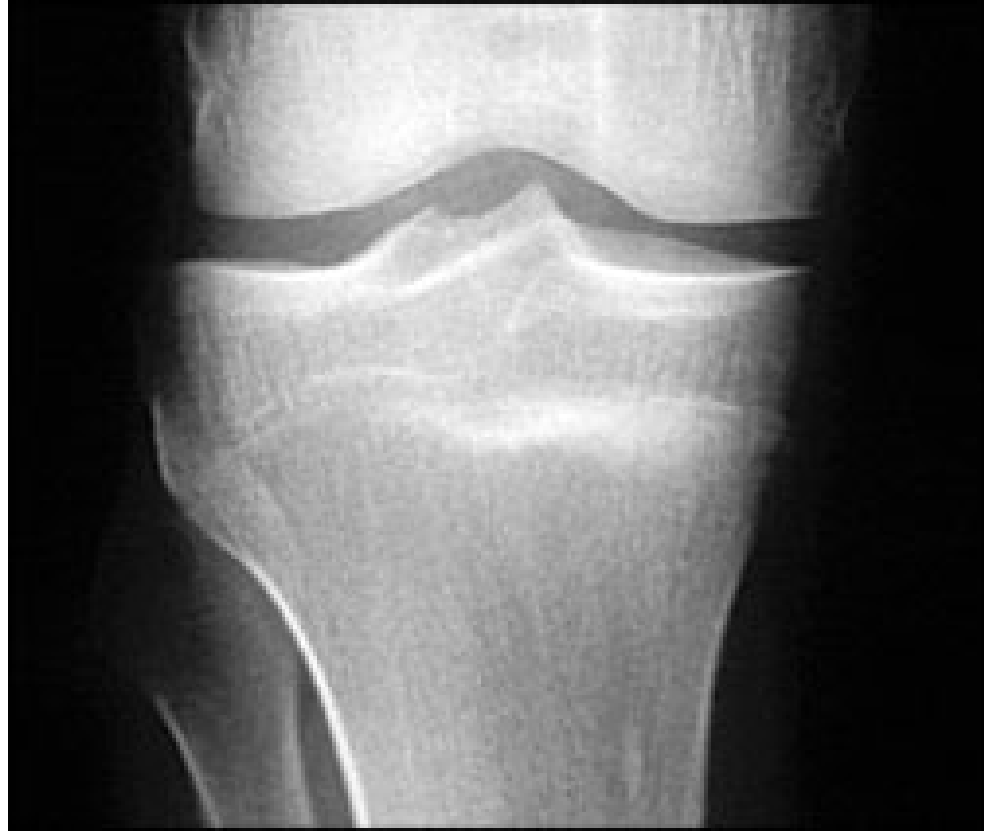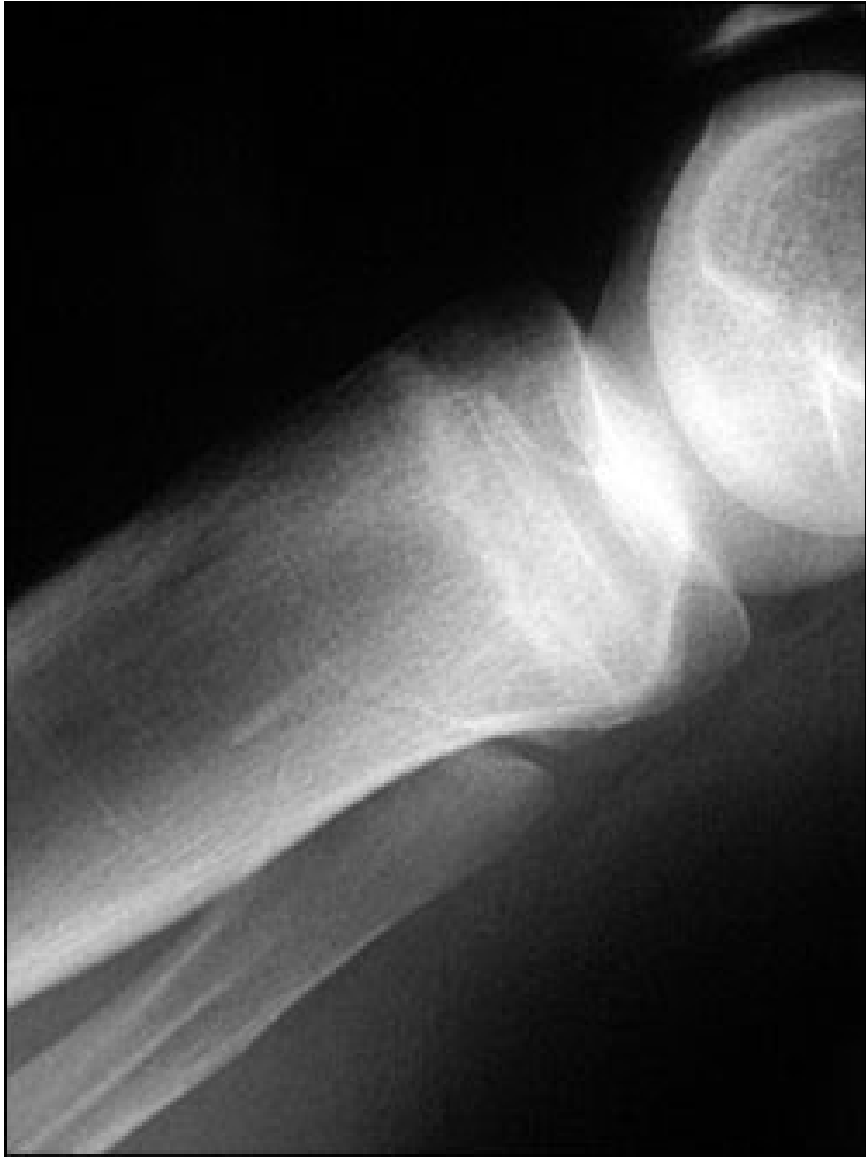Discussion


- Medical history that suggests a stress fracture will include persistent pain following an acute increase in physical activity (i.e., time, distance, or pace). Physical examination may reveal tenderness at or near the medial joint line, tenderness with a leverage motion, and tenderness with hopping on the affected leg. A joint effusion may also be present.



Discussion

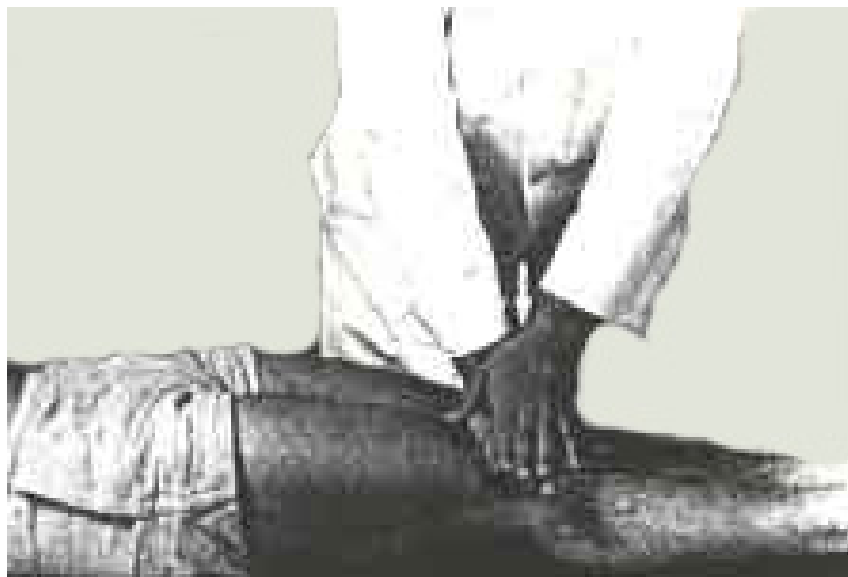- Plain radiographs can appear normal for weeks or even months. Because the metaphyseal portions of long bones are mostly cancellous bone, the typical periosteal/endosteal reaction will not be visible. In this type of bone, the features of a stress fracture manifest as a **band-like area of sclerosis**. If a stress fracture is suspected but radiographic results are normal, then magnetic resonance imaging (MRI) or a bone scan is the next diagnostic study. Of the two, MRI is more sensitive for diagnosing stress fracture.








Patellofemoral Dysfunction

Patella Grinding Test

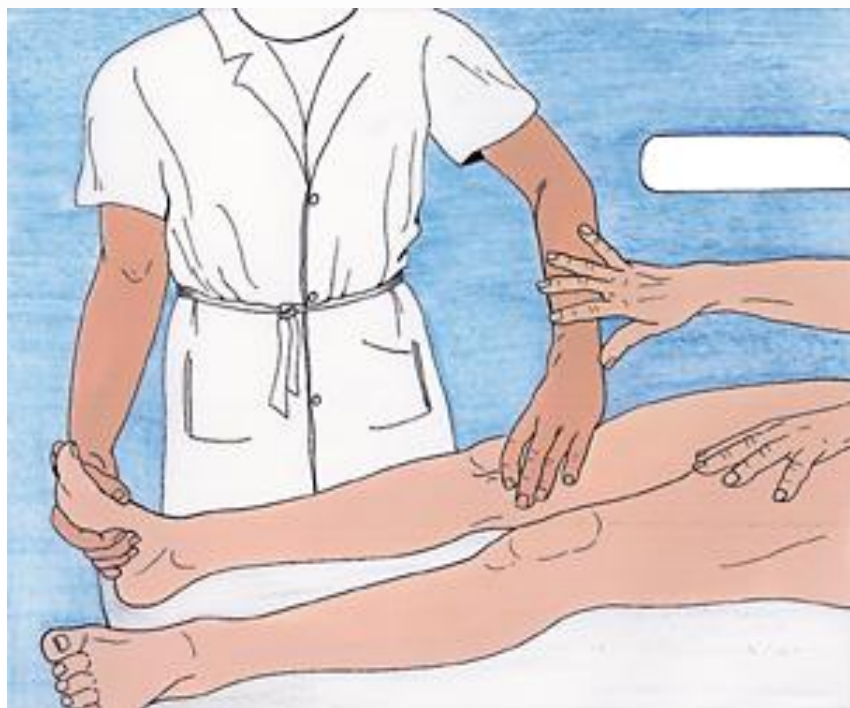


- Chondromalacia patellae
- Patellofemoral arthralgia
- Chondral fracture




Patellofemoral Dysfunction

Patella Apprehension Test

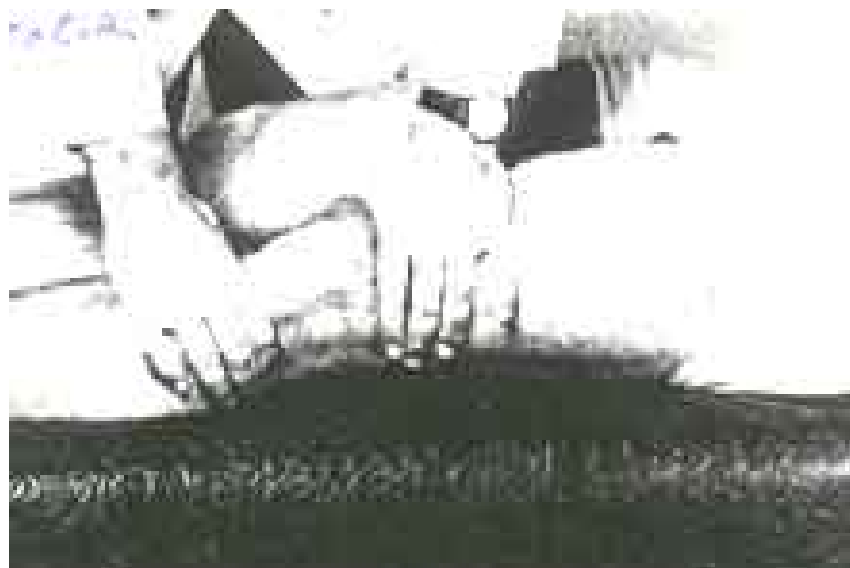

- Pain and apprehension are present
- Positive test indicates lateral patellar dislocation



Patellofemoral Dysfunction

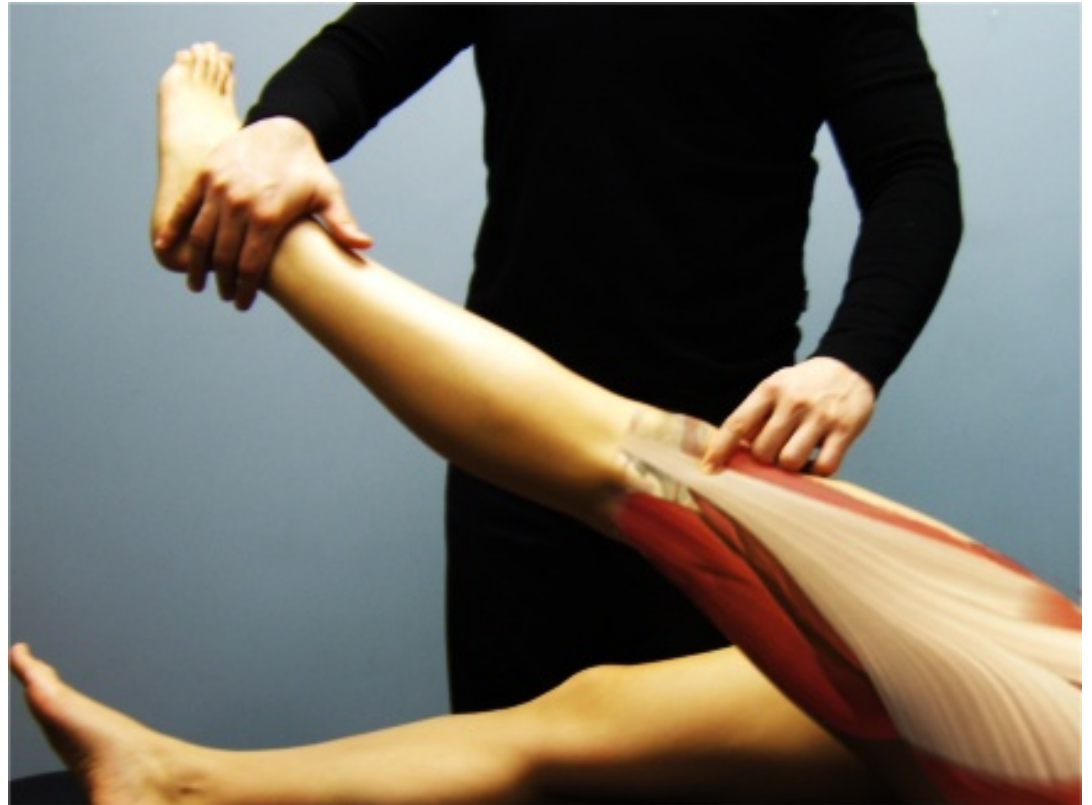Clarke's Patellar Scrape Test



- Pain and crepitation may indicate patellofemoral arthralgia or chondromalacia patellae

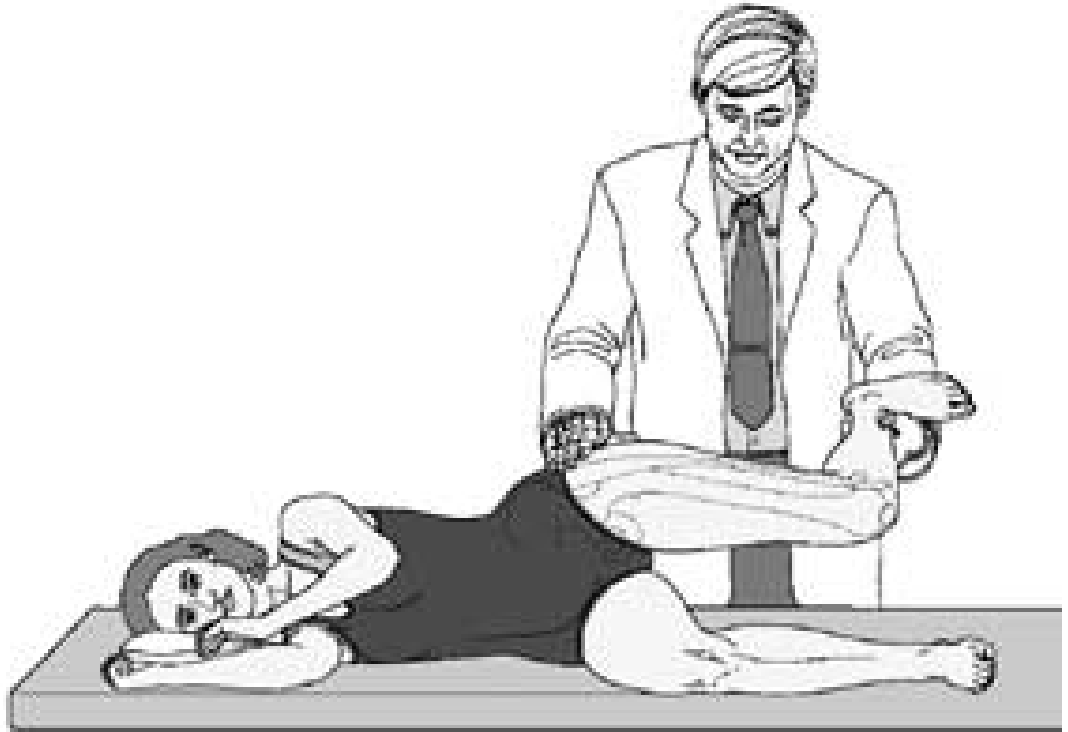Noble Compression Test for ITBS

1. Patient supine
2. Apply thumb pressure to the lateral femoral condyle with knee flexed to 75 degrees.
3. Maintain thumb pressure while extending knee
4. At 30 degrees of flexion, patient will complain of severe pain over ITB
5. This is a positive test for ITBS



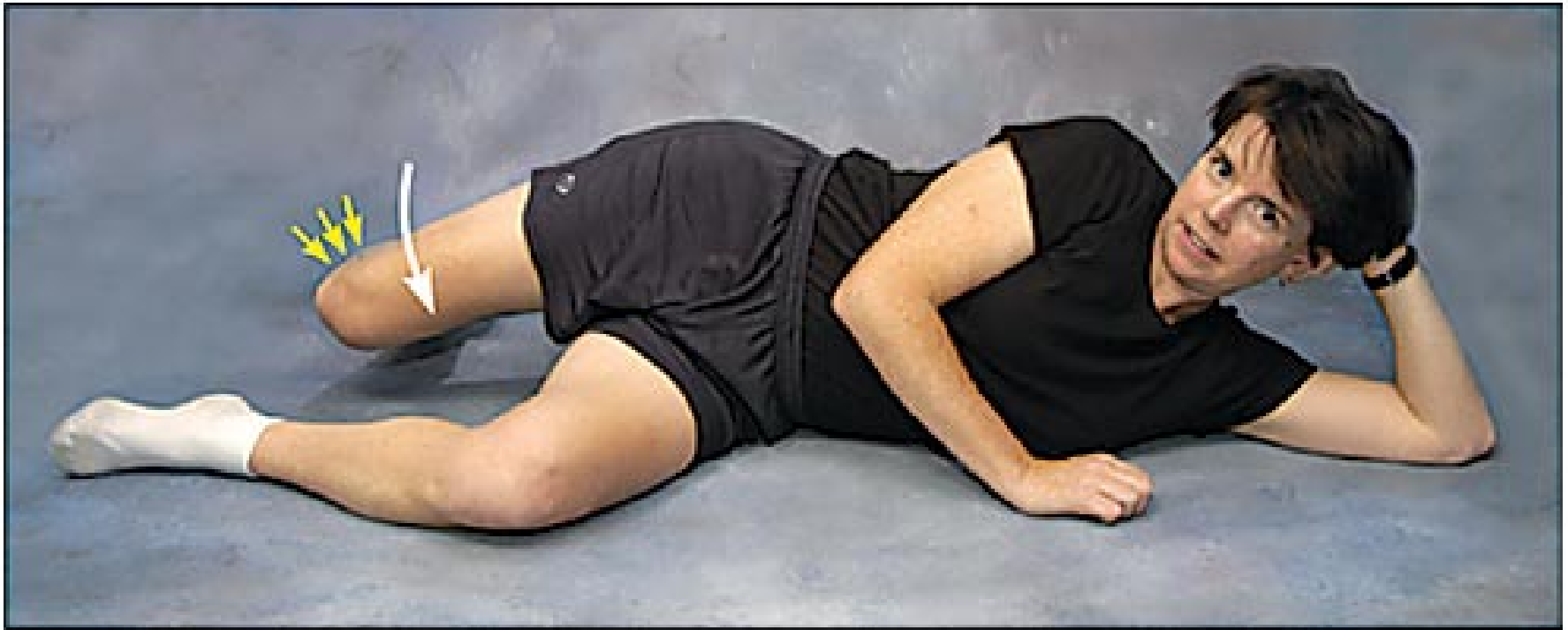Ober Test Iliotibial Band Syndrome

The patient lies down with the unaffected side down and the unaffected hip and knee at a 90-degree angle. If the iliotibial band is tight, the patient will have difficulty adducting the leg beyond the midline and may experience pain at the lateral knee .



Ober Test

Iliotibial Band Syndrome



Wilson Sign for Osteochondritis

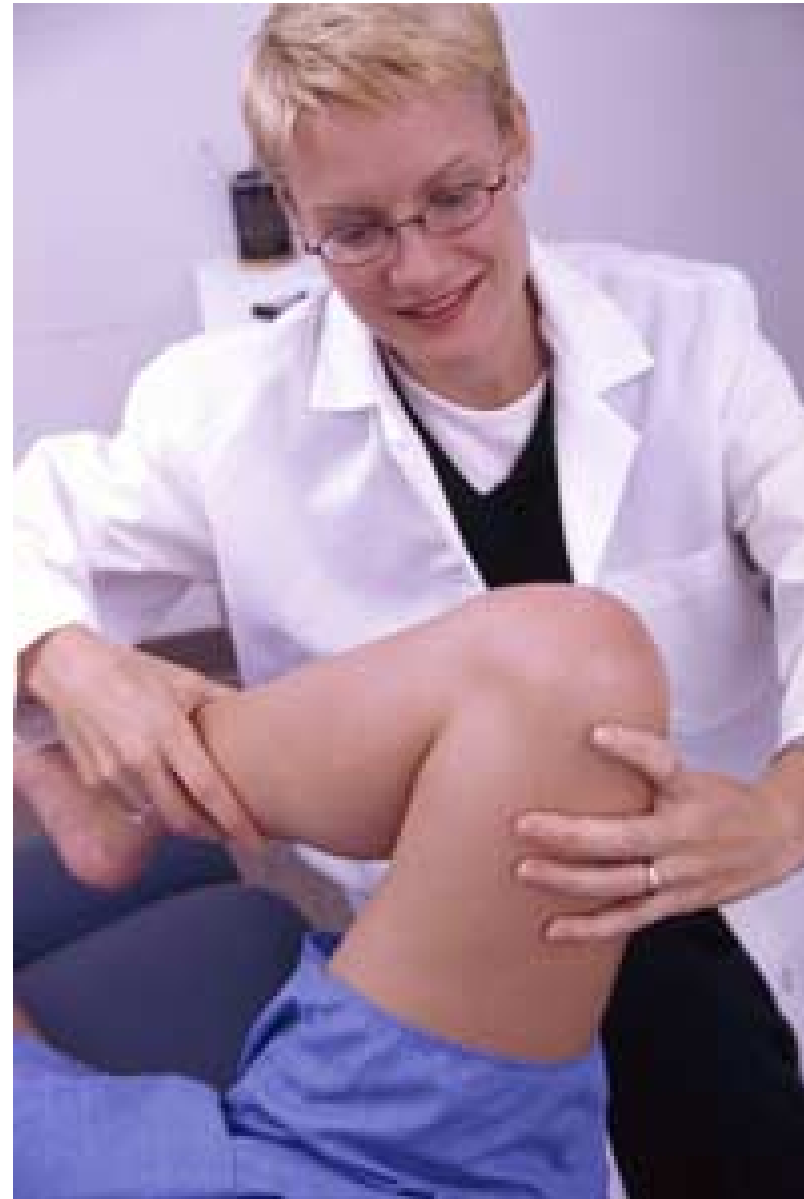Patient is supine


Knee is passively flexed to 90 degrees and then extended with medial rotation of knee.

Near 30 degrees of flexion, the pain increases and patient may resist further extension.

Rotating the knee laterally eliminates the pain.

This is a positive test for osteochondritis of the femur.





Radiographic Decision Rules

- The Pittsburgh decision rules were 99 percent sensitive and 60 percent specific for the diagnosis of knee fractures and could have reduced the use of radiography by 52 percent, with one missed fracture. If the rules indicated a fracture, 24.1 percent of patients actually had a knee fracture (positive predictive value); if the rules indicated no fracture, 99.8 percent of patients did not have a knee fracture (negative predictive value). The Ottawa knee rules were 97 percent sensitive and 27 percent specific for knee fractures, with three fractures missed. The authors of the comparative study concluded that the Pittsburgh decision rules were more specific, with **no loss of sensitivity**.

Seaberg DC, Yealy DM, Lukens T, Auble T, Mathias S. Multicenter comparison of two clinical decision rules for the use of radiography in acute, high-risk knee injuries. *Ann Emerg Med* 1998;32:8-13

Pittsburgh Rules

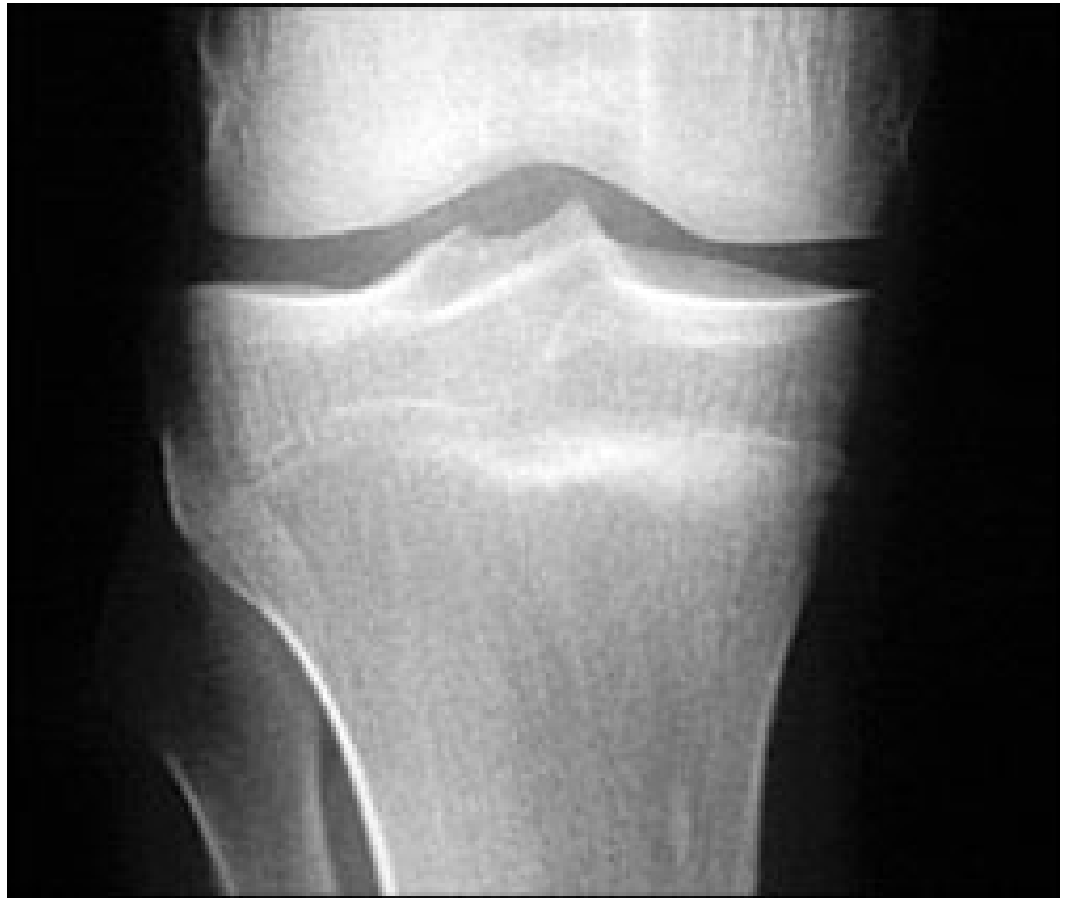Patient should receive knee films if:

Blunt trauma or a fall as mechanism of injury

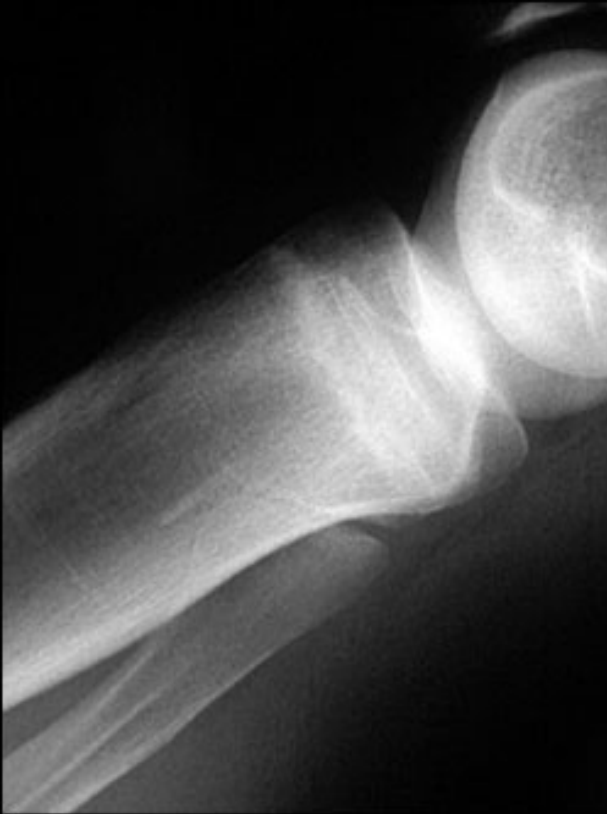
AND either of the following:

Age younger than 12 years or older than 50 years

Inability to walk four weight-bearing steps in the emergency department



Ottawa Rules



Age \geq 55?

Isolated
tenderness of the
patella (no other
bony tenderness)?

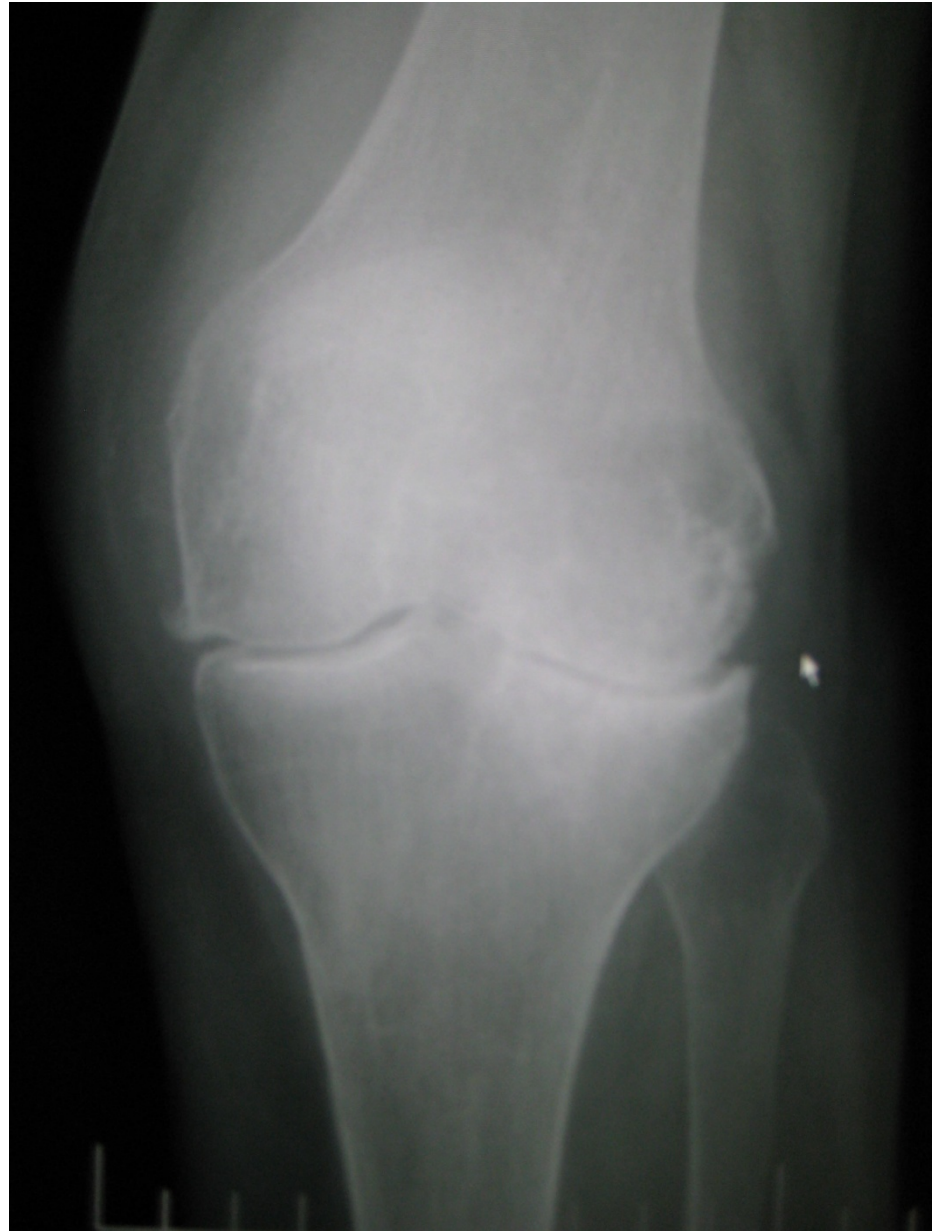Tenderness at the
fibular head?

Inability to flex
knee to 90° ?

**If any of the above criteria are met,
this patient may need knee
imaging.**

Degenerative Joint Disease of the Knee

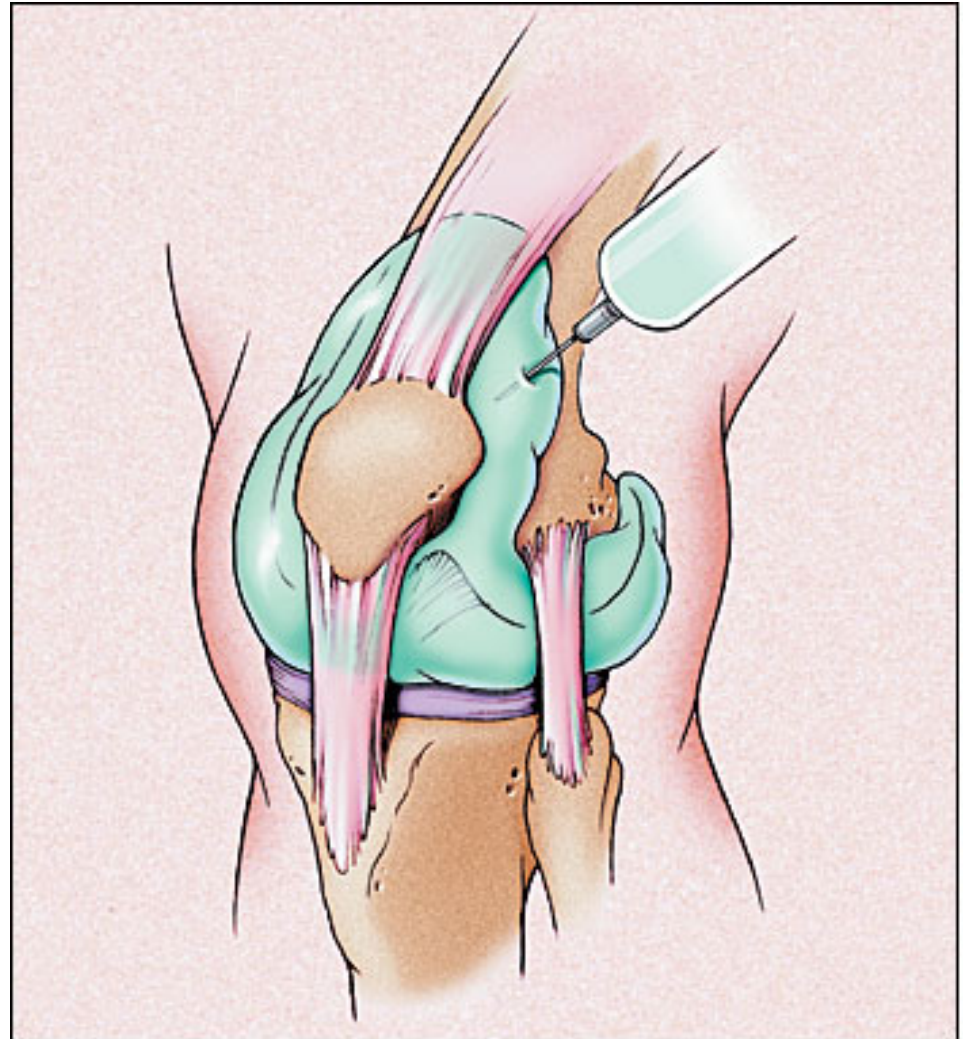
Osteoarthritis (OA) also known as degenerative arthritis or degenerative joint disease, is a group of mechanical abnormalities involving degradation of joints, including articular cartilage and subchondral bone.



Knee Aspiration and Injection

Knee joint aspiration and injection are performed to establish a diagnosis, relieve discomfort, drain off infected fluid, or instill medication. Because prompt treatment of a joint infection can preserve the joint integrity, any unexplained monoarthritis should be considered for arthrocentesis

<http://www.aafp.org/afp/2002/1015/p1497.html>

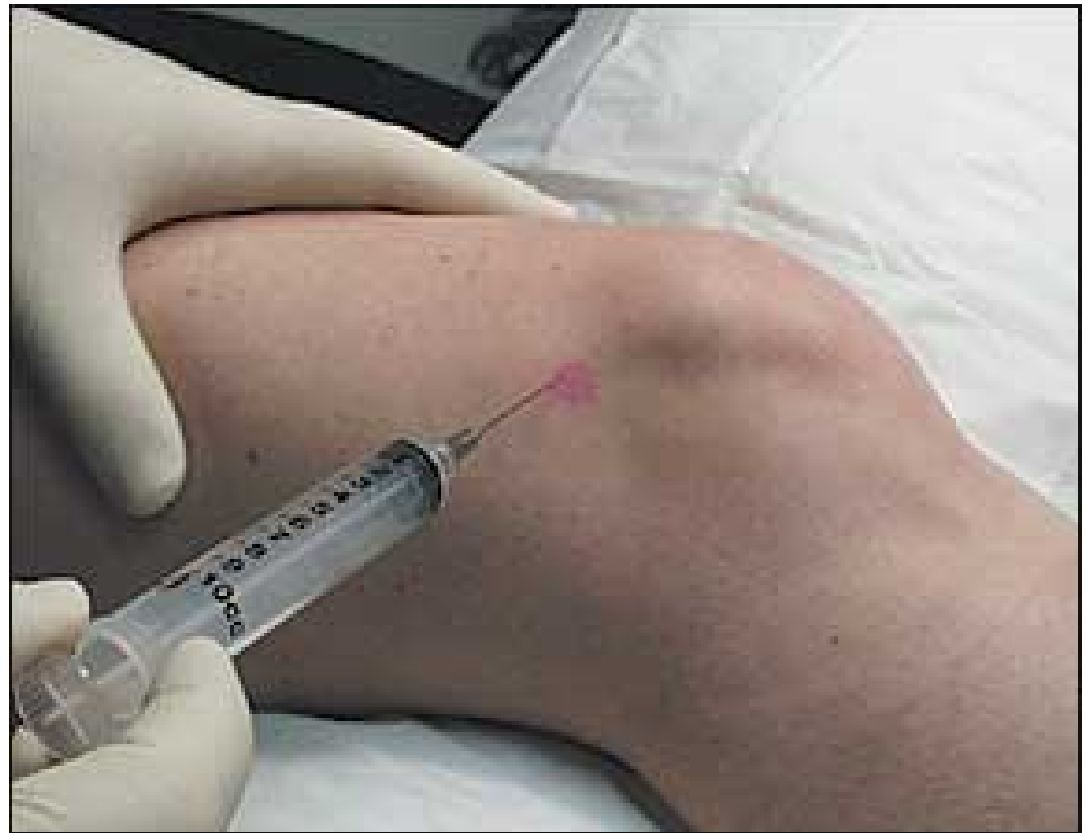

Lateral knee joint injection.

Entry should be in the soft tissue between the patella and femur.

For the medial approach, the needle enters the medial side of the knee under the middle of the patella (midpole) and is directed toward the opposite patellar midpole. In the anterior approach, the knee is flexed 60 to 90 degrees, and the needle is inserted just medial or lateral to the patellar tendon and parallel to the tibial plateau. This technique is preferred by some physicians for its ease of joint entry in advanced osteoarthritis.


<http://www.aafp.org/afp/2003/0515/p2147.html>



Symptoms of DJD of the Knee

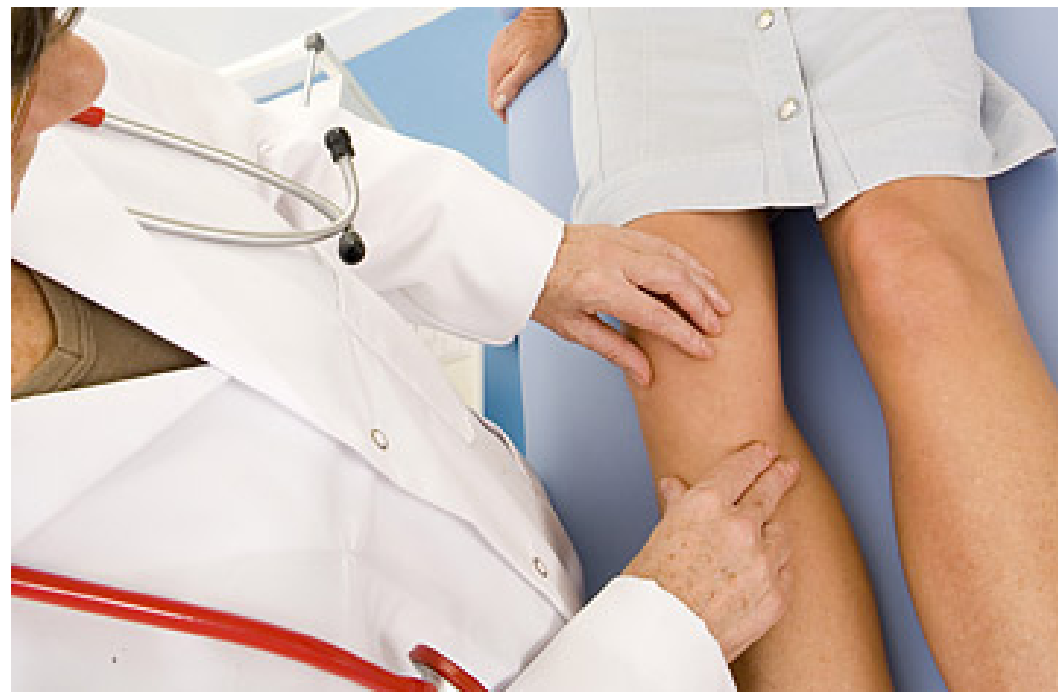The main symptom is pain, causing loss of mobility and often stiffness. "Pain" is generally described as a sharp ache, or a burning sensation in the associate muscles and tendons. OA /DJD can cause a crackling noise or crepitus when the affected joint is moved or touched, and patients may experience muscle spasm and contractions in the tendons.





Orthopedic Evaluation

- History
- Observation
- Palpation
- Range of motion
- Special tests



Treatment of DJD of the Knee

Modification of lifestyle

Moderate exercise

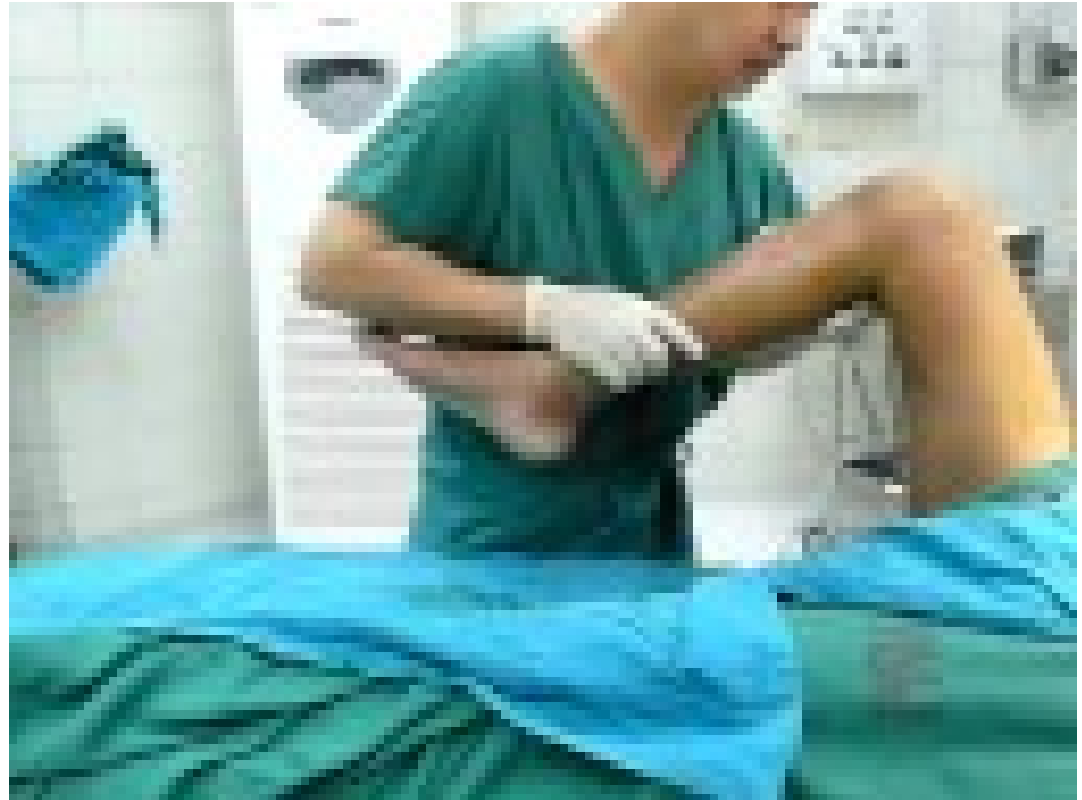Self-management (weight loss) is more beneficial than medications


Smoking cessation

Medications:

Acetaminophen preferred over NSAIDS

Manipulation/mobilization





Internal Derangement of Knee (IDK)

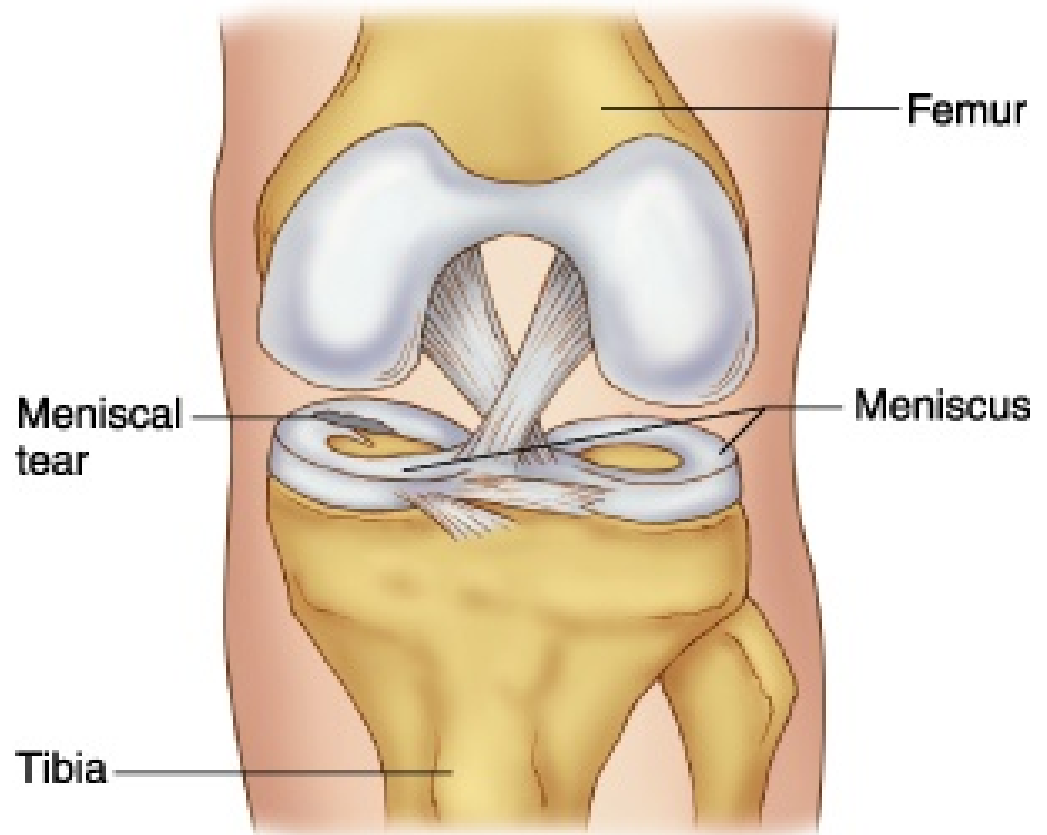


- Some physicians refer to IDK as “I don’t know.”

Internal Derangement of the Knee

ICDA Code 717

Internal derangement of the knee (IDK) is the term used to cover a group of disorders involving disruption of the normal functioning of the ligaments or cartilages (menisci) of the knee joint.



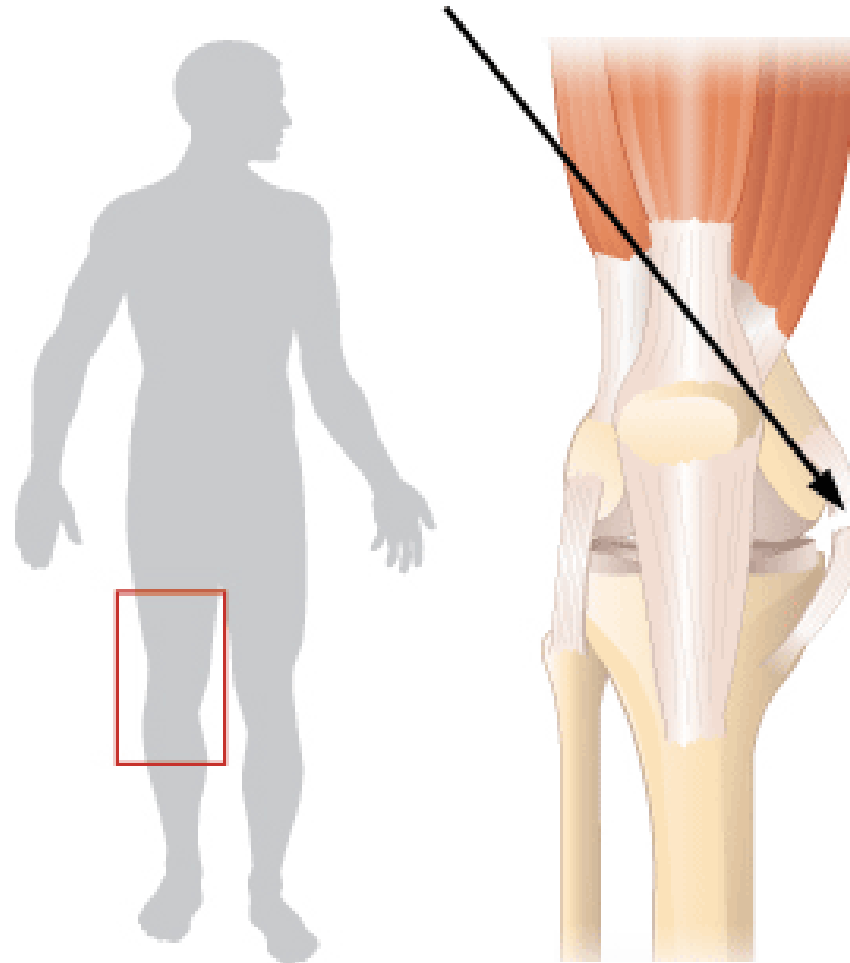
Most Common IDK Conditions

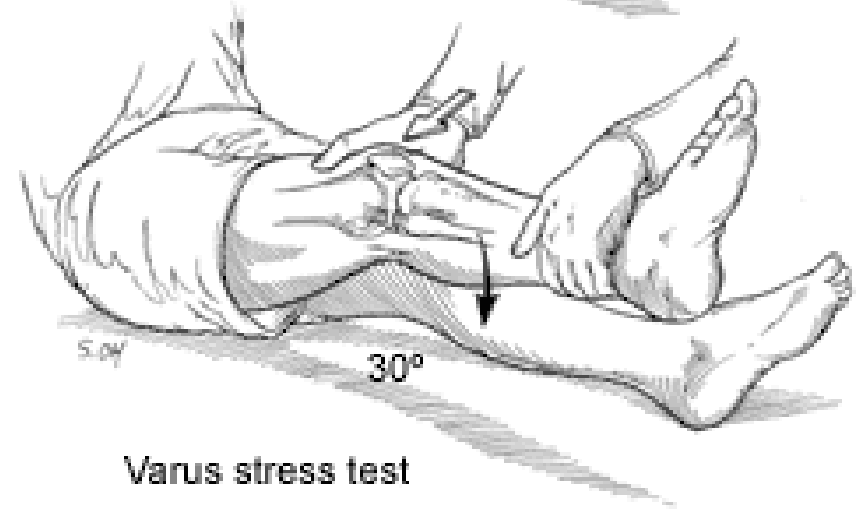
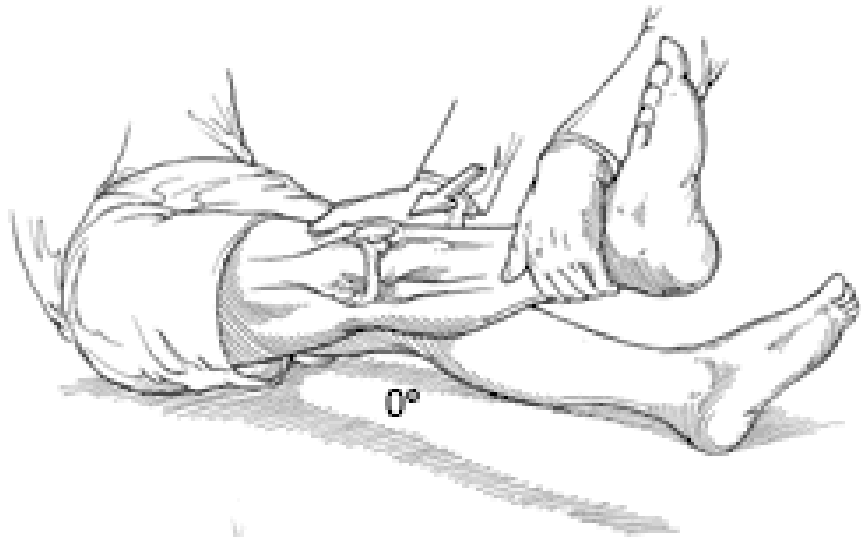
The commonest derangement met with is injury to the medial collateral ligament.

The medial meniscus and anterior cruciate ligament are next in frequency.

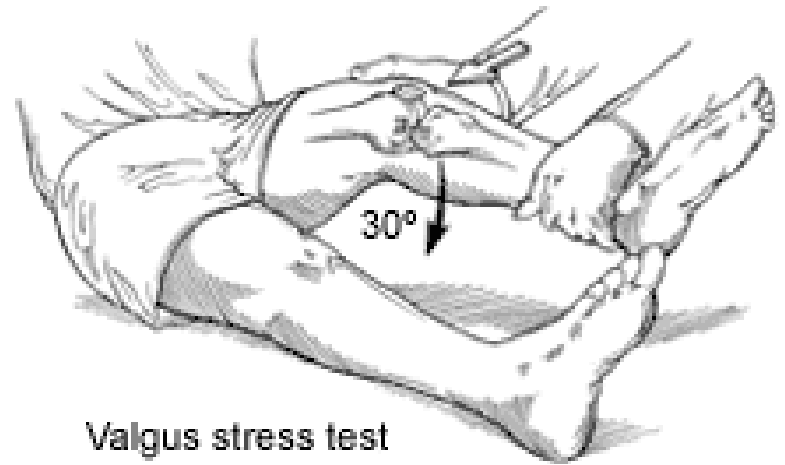
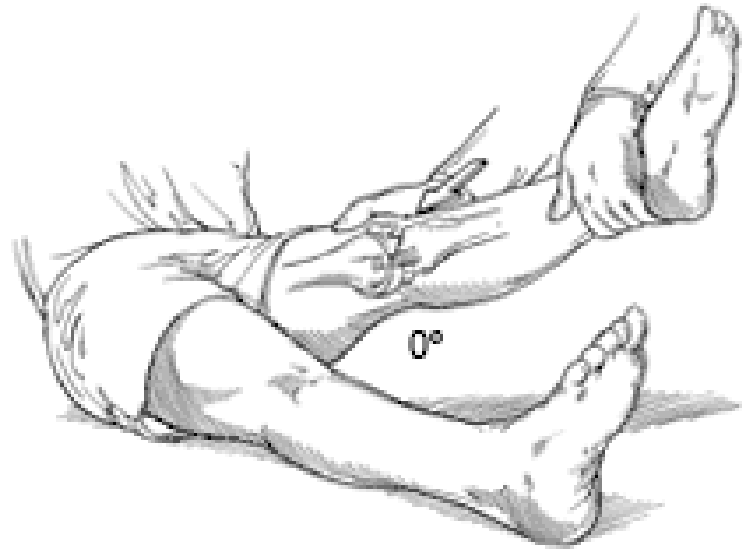
The lateral ligament, lateral meniscus and posterior cruciate ligament are less liable to damage.

Medial Collateral Ligament (MCL) Tear





Varus stress test

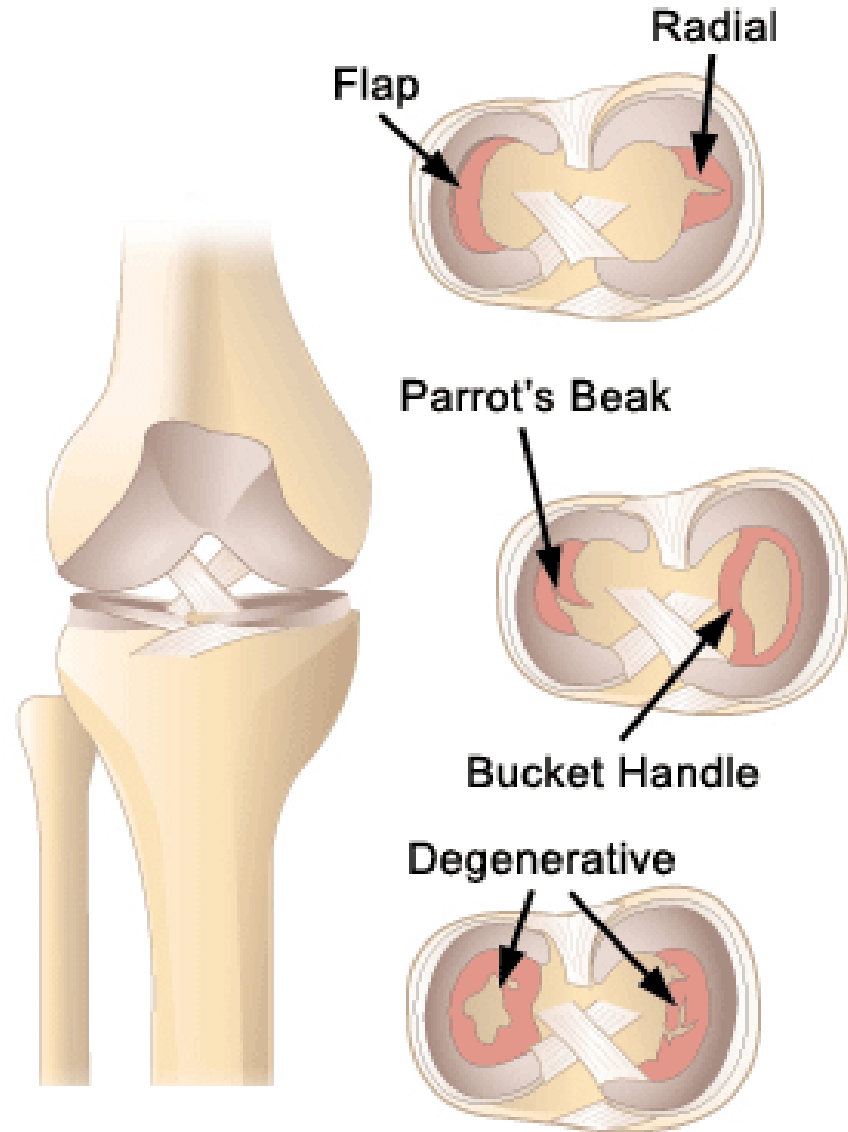


Valgus stress test


Atraumatic Degenerative IDK

Age-related degeneration of a semilunar cartilage may be met with in an older patient, say over age 50.

It may present as spontaneous occurrence of knee pain without any history of injury.



Types of Meniscus Tears




- **Internal derangement of the knee** is the term used to describe the various types of disruption of the ligaments and cartilages of the knee.
- By far the most frequent cause is **sports injury**, with footballers especially at risk.
- Some disorders of the cartilages may occur without evidence of prior injury.
- **Osteoarthritis of the knee** is commonly a late sequel of cartilage or cruciate ligament damage.

Question?

How do you manage internal derangement of the knee?

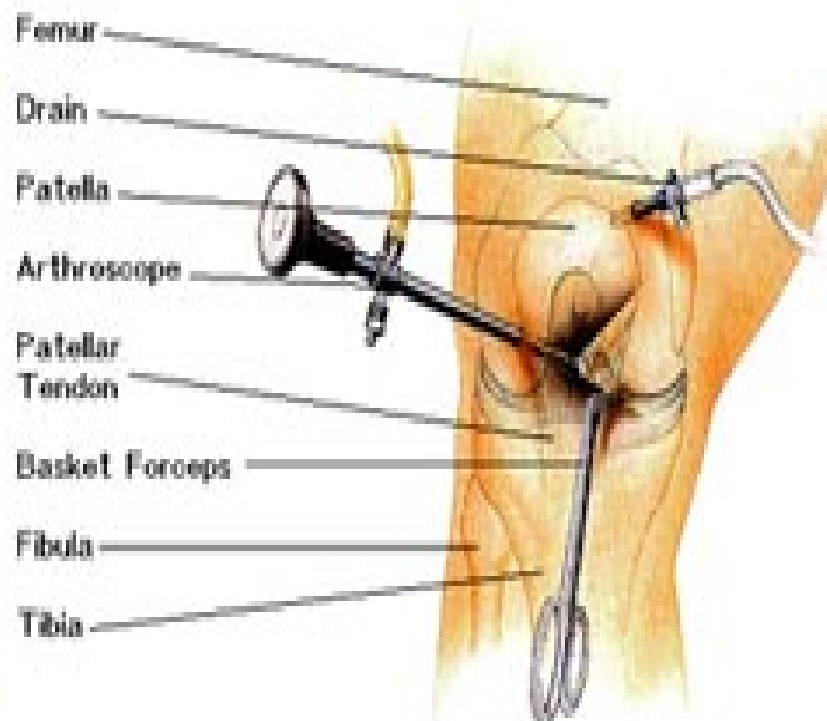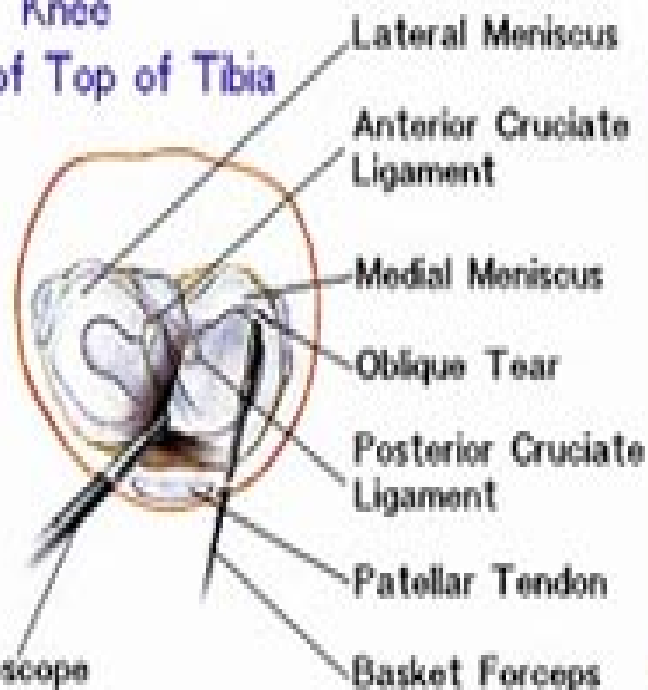




Arthroscopy: Knee I

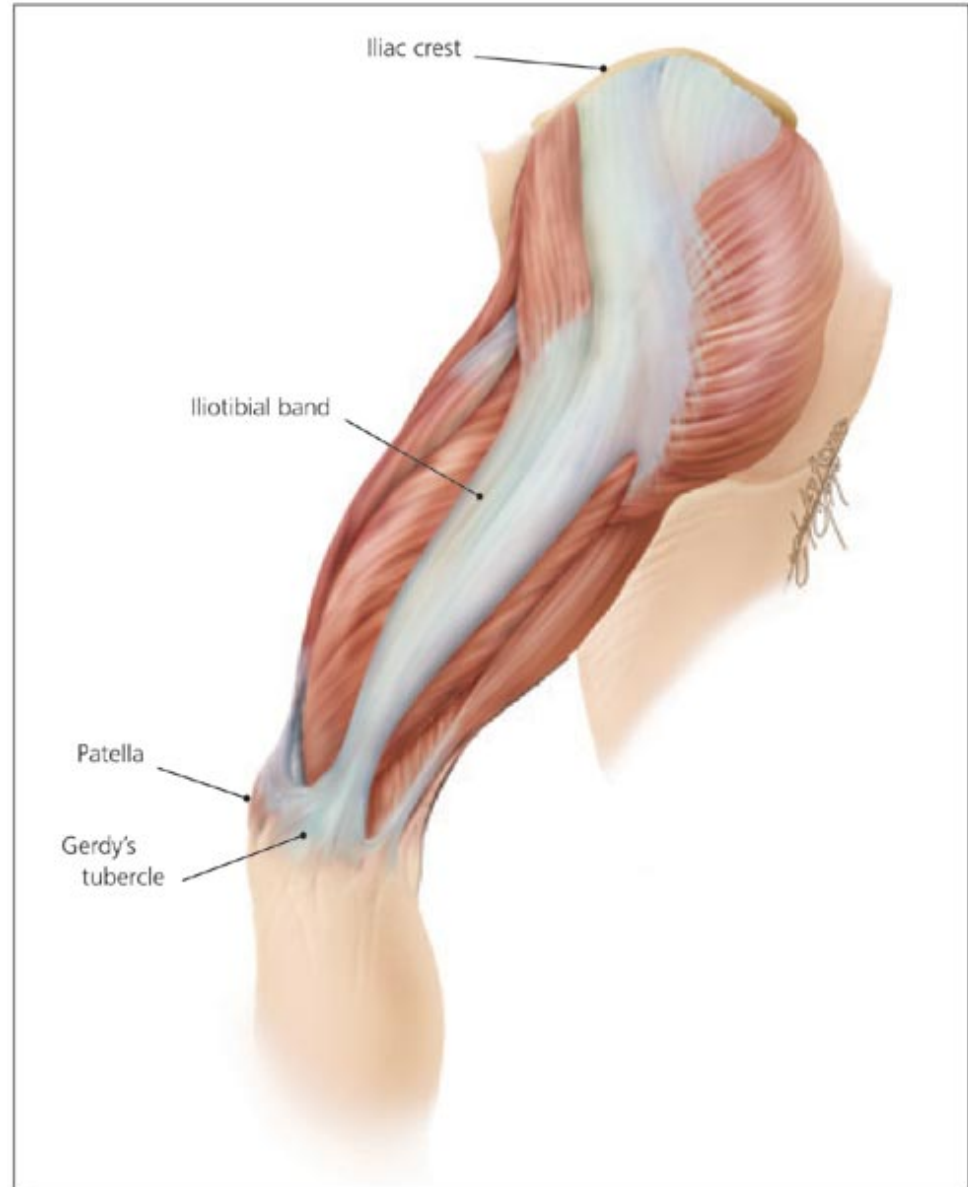
Arthroscopy: Knee II

Knee
View of Top of Tibia



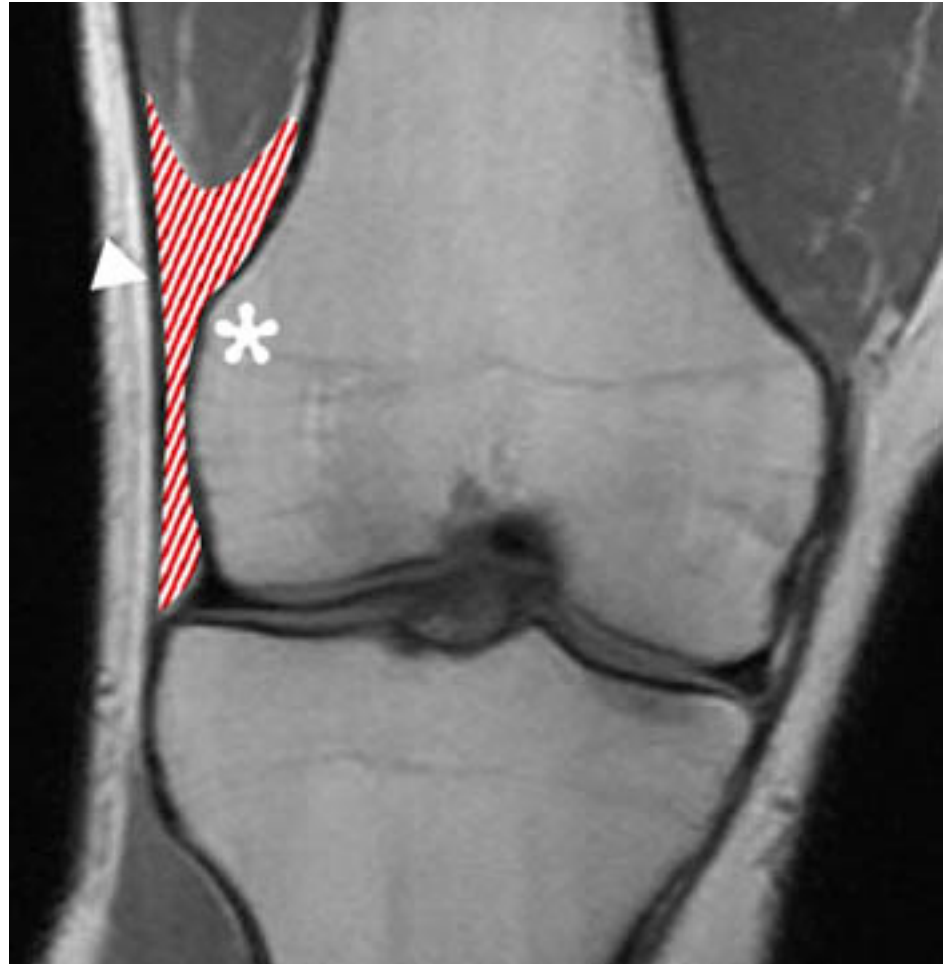Iliotibial Band Syndrome

The iliotibial band is a thick band of fascia that extends along the lateral thigh from the iliac crest to the knee.



Iliotibial Band Syndrome

Iliotibial band friction syndrome (ITBFS) is a frequently encountered overuse injury caused by repetitive friction between the iliotibial band and the lateral femoral epicondyle during active flexion and extension at the knee.



History

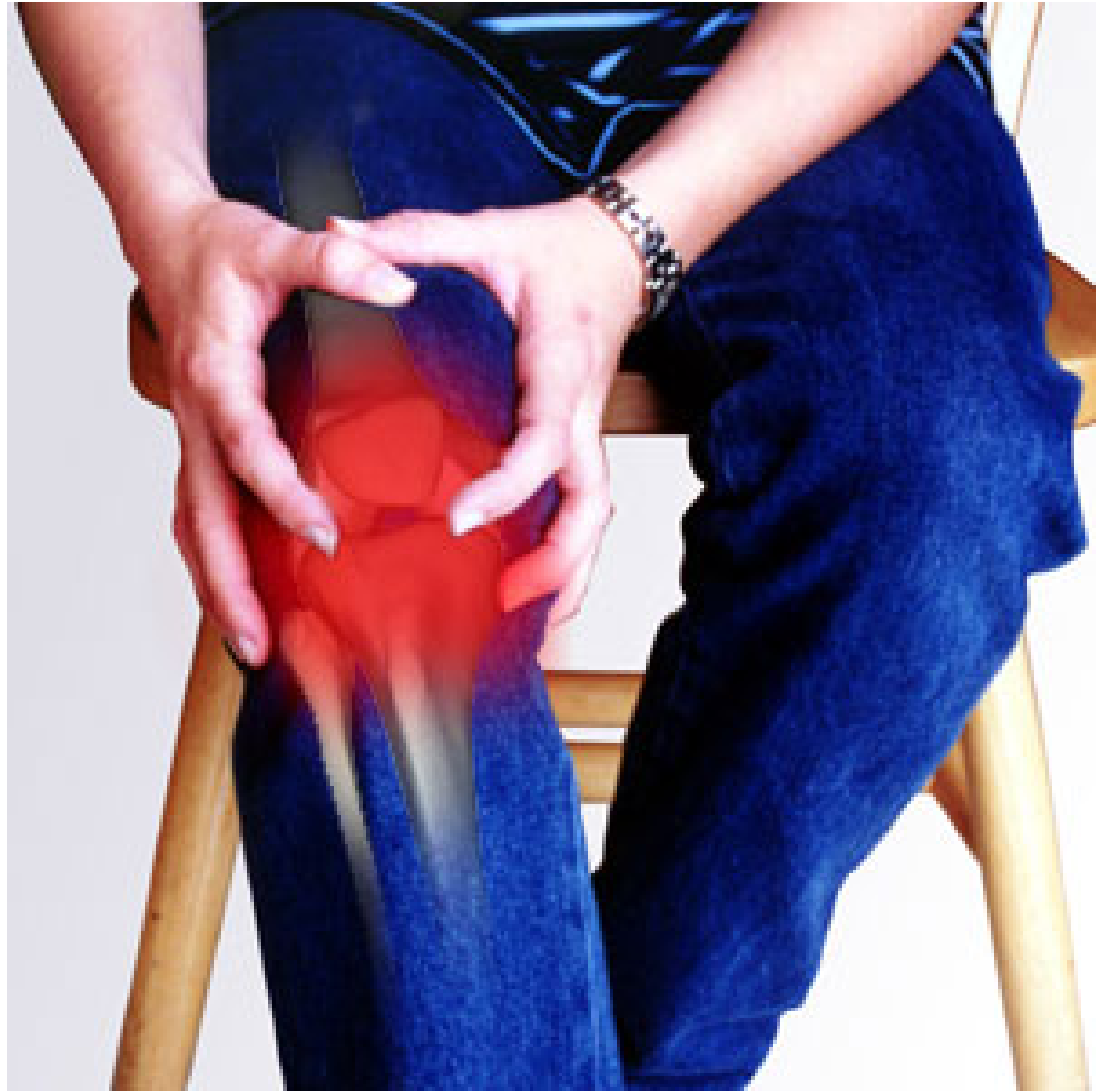PAIN

CHARACTERISTICS

The patient's description of knee pain is helpful in focusing the differential diagnosis.

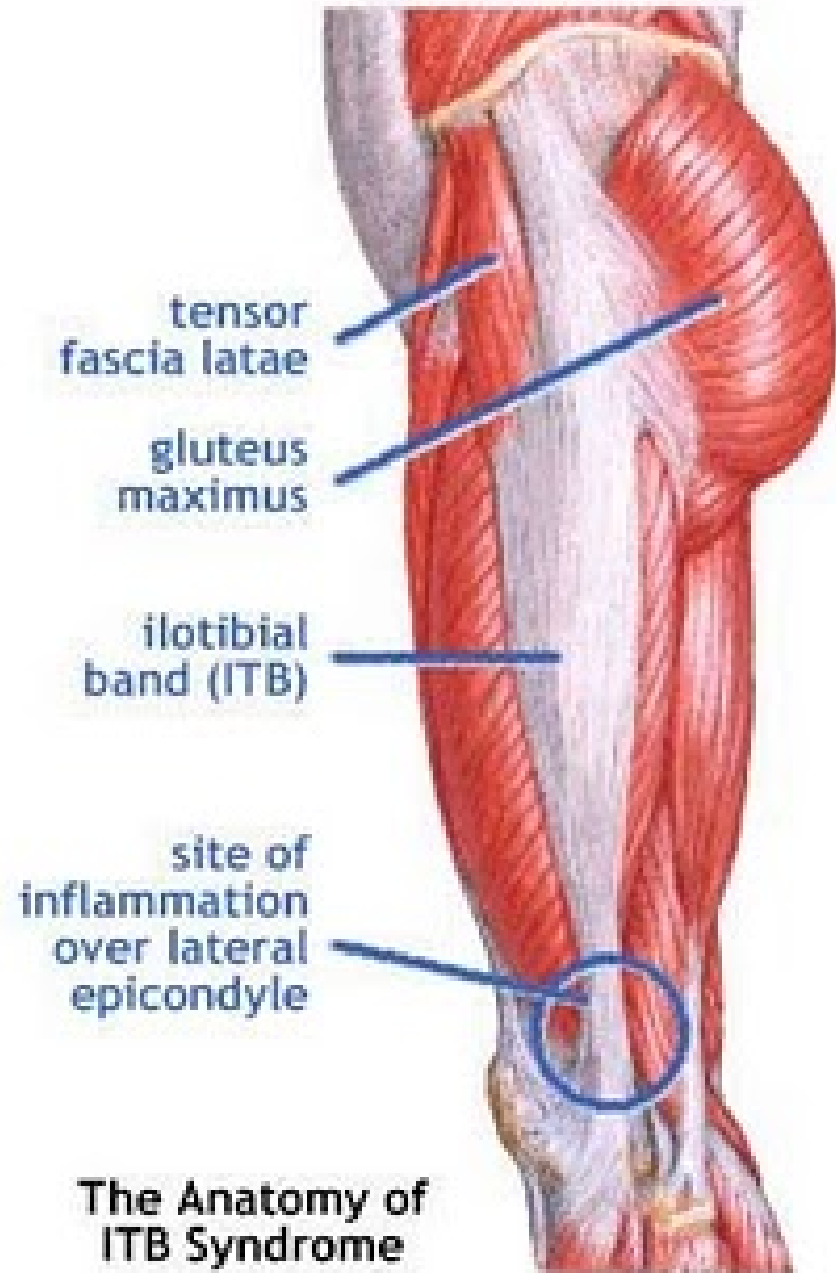
It is important to clarify the characteristics of the pain, including its onset (rapid or insidious), location (anterior, medial, lateral, or posterior knee), duration, severity, and quality (e.g., dull, sharp, achy).

Bergfeld J, Ireland ML, Wojtys EM, Glaser V. Pinpointing the cause of acute knee pain. *Patient Care*. 1997;31(18):100–7.



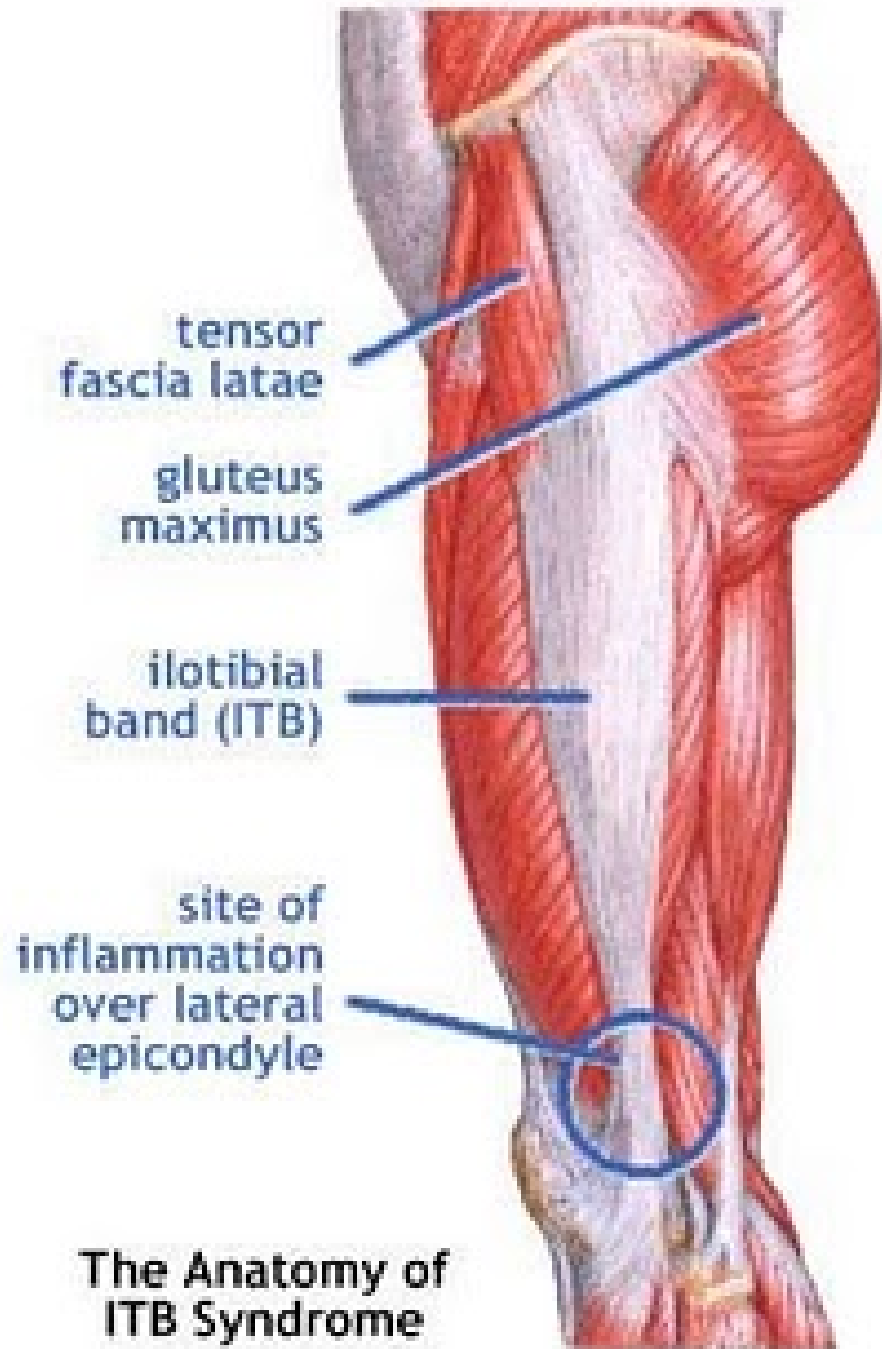
Iliotibial Band Syndrome


The primary initial complaint in patients with iliotibial band syndrome is diffuse pain over the lateral aspect of the knee.



Iliotibial Band Friction Syndrome

Patients with iliotibial band syndrome often demonstrate tenderness on palpation of the lateral knee approximately 2 cm above the joint line.





Ober's Test



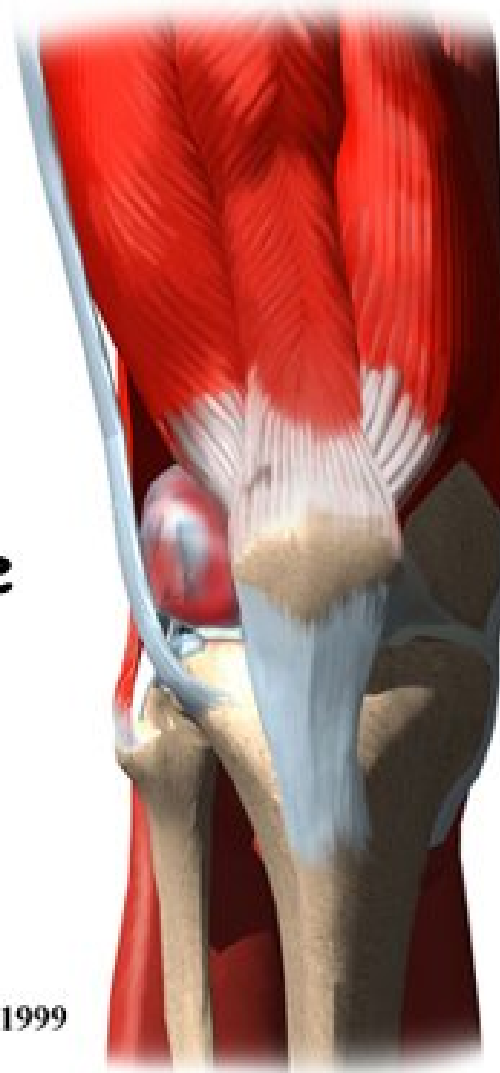- Failure to descend smoothly indicates a positive test for contracture of the TFL or ITB.

Iliotibial Band Syndrome

Swelling may be noted at the distal iliotibial band and thorough palpation of the affected limb may reveal multiple trigger points in the vastus lateralis, gluteus medius, and biceps femoris.

Palpation of these trigger points may cause referred pain to the lateral aspect of the affected knee.

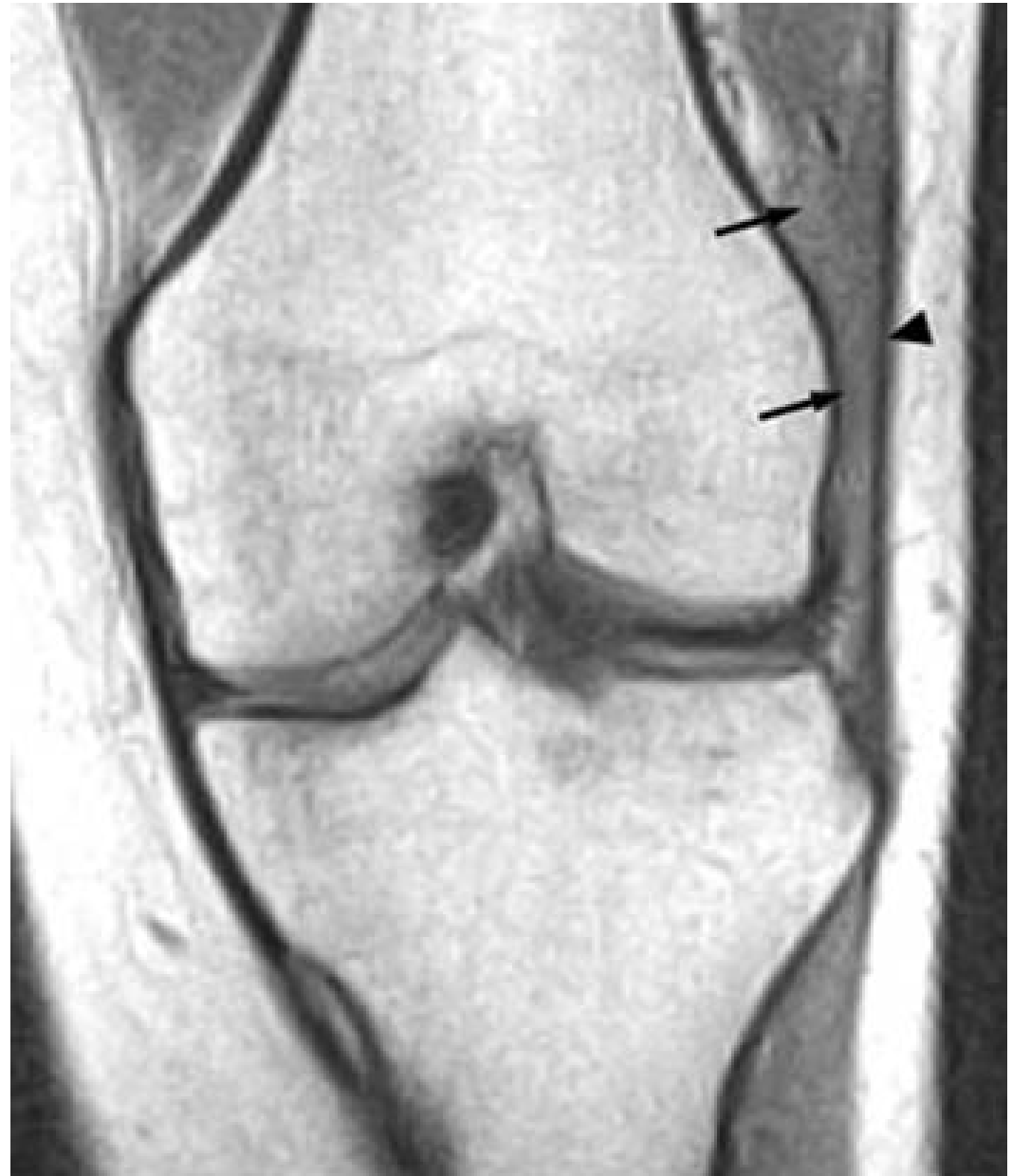Iliotibial Band Syndrome



©MMG 1999

Iliotibial Band Syndrome

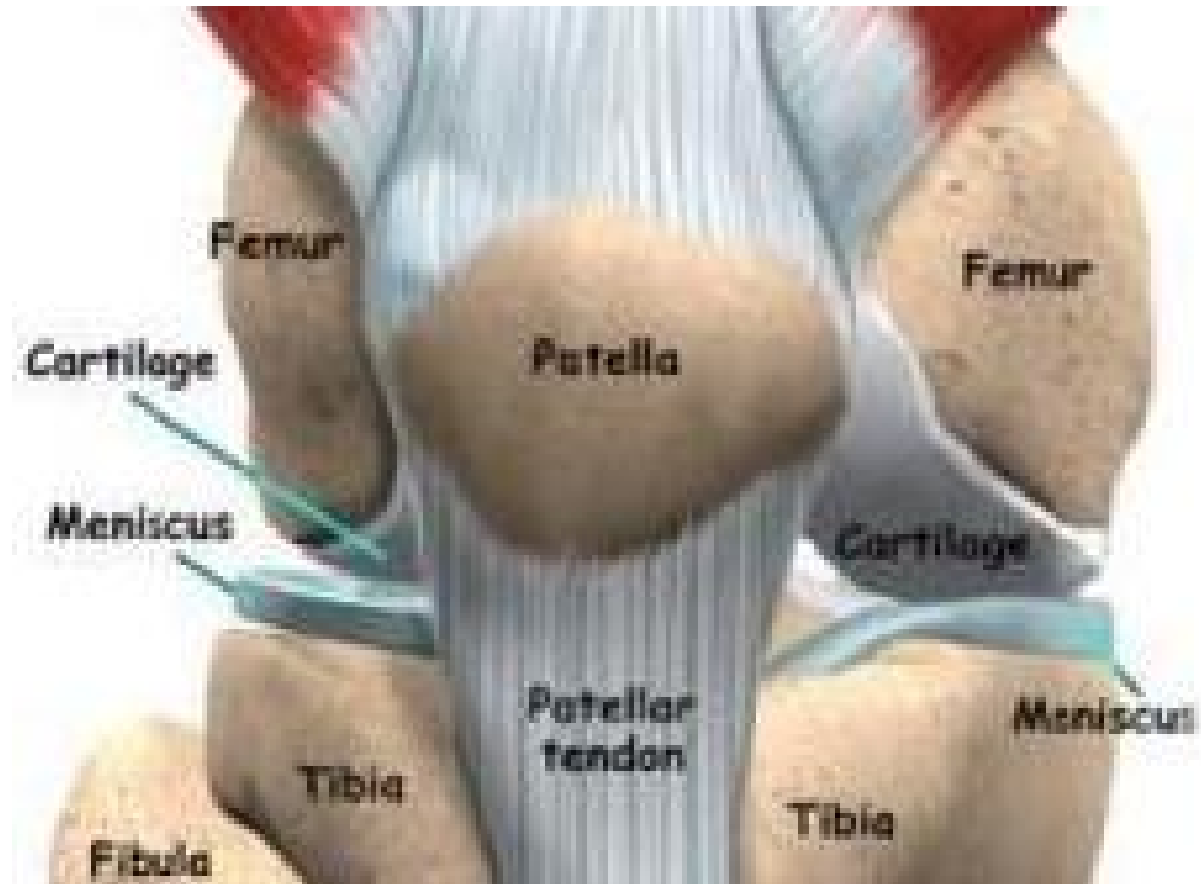
The T1-weighted coronal image demonstrates intermediate signal intensity (arrows) replacing normal fat signal intensity deep to the iliotibial band (arrowhead).



Patellofemoral Arthralgia

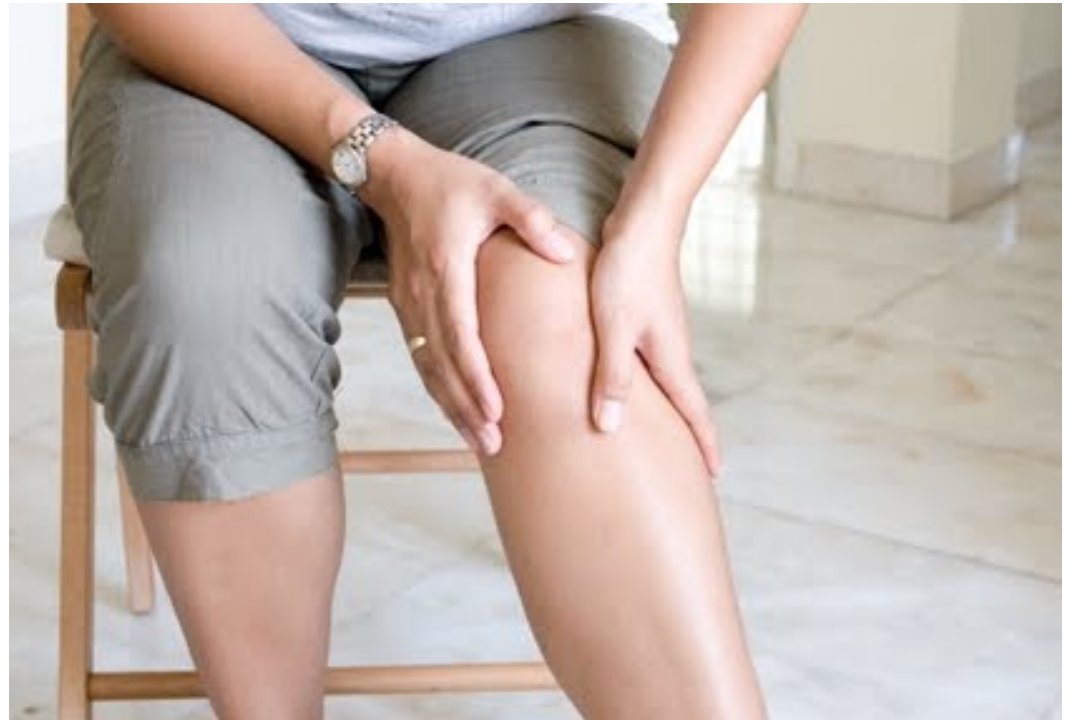Fortunately, true chondromalacia patella is relatively rare, but crepitus and subpatellar pain are probably the most common complaints seen in a sports medicine clinic, where most knee problems will have some associated patellofemoral dysfunction.

Welsh RP. Can Fam Physician. 1985 March; 31: 573–576.



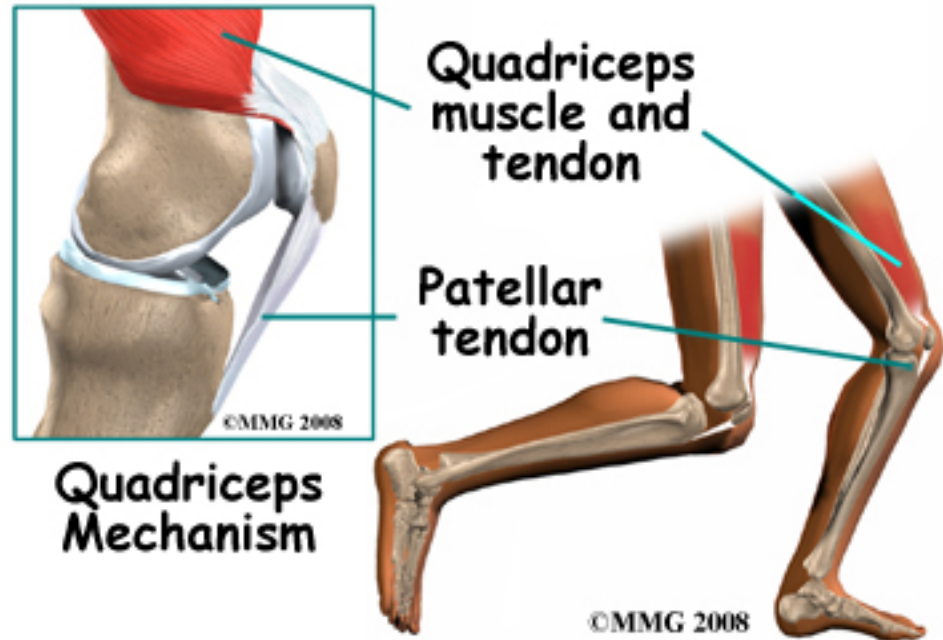
Patellofemoral Arthralgia

Anterior knee
pain, pain with
stair climbing,
prolonged sitting,
absence of
radiographic
pathology



Mechanism

The cause of pain and dysfunction often results from either abnormal forces (e.g. increased pull of the lateral quadriceps retinaculum with acute or chronic lateral PF subluxation/dislocation) or prolonged repetitive compressive or shearing forces (running or jumping) on the PF joint.



Patellofemoral Arthralgia

- Magnetic resonance imaging determination of tibial tubercle lateralization and patellar tilt correlates positively with the clinical diagnosis of anterior knee pain, suggesting that patellofemoral pain is caused by subtle malalignment.
- LEVEL OF EVIDENCE: Level III, development of diagnostic criteria on basis of nonconsecutive patients.
 - Arthroscopy. 2007 Mar; 23(3):333-4; author reply 334.

Patellofemoral Arthralgia

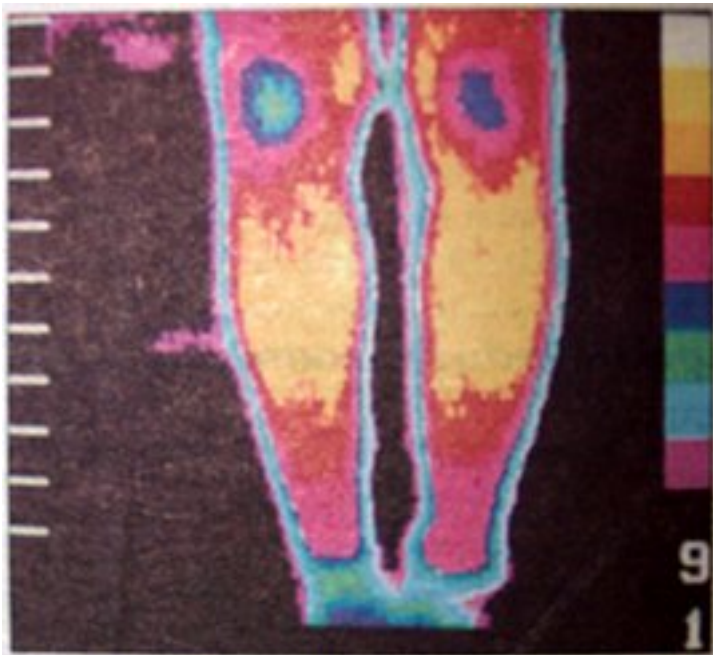
- ❖ 28 of 30 athletic patients demonstrated positive thermography findings.
- ❖ Exercise and faradic stimulation to the vastus medialis
- ❖ 3 months post treatment produced normal thermographic findings in all 28 patients

Thermography was performed on 30 patients if all the following symptoms and physical signs were present: (a) retropatellar pain related to exercise and aggravated by using stairs or by prolonged sitting with flexed knees; (b) pain on patellar compression against the femoral condyles with the knee extended; (c) medial patellar tenderness; and (d) pain on resisted patellar movement when the quadriceps was contracted whilst the patella was forcibly held downwards. Patients were excluded if they had any history of direct trauma to the patella or had had an episode of patellar dislocation.

M. D. DEVEREAUX, G. R. PARR, S. M. LACHMANN, D. P. PAGE THOMAS, B. L. HAZLEMAN THERMOGRAPHIC DIAGNOSIS IN ATHLETES WITH PATELLOFEMORAL ARTHRALGIA. *Journal of Bone and Joint Surgery*
<http://web.jbjs.org.uk/cgi/reprint/68-B/1/42>

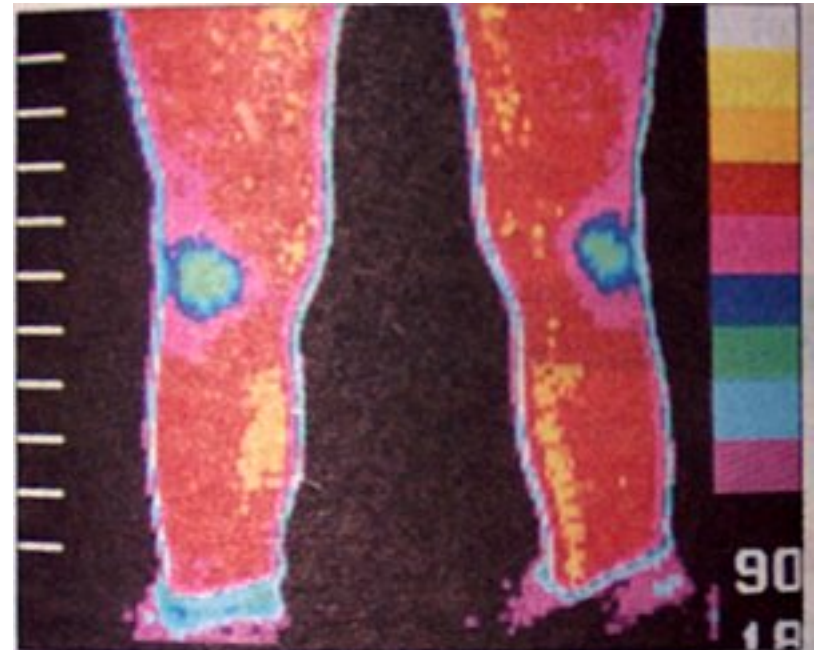
Patellofemoral Arthralgia

Abnormal findings



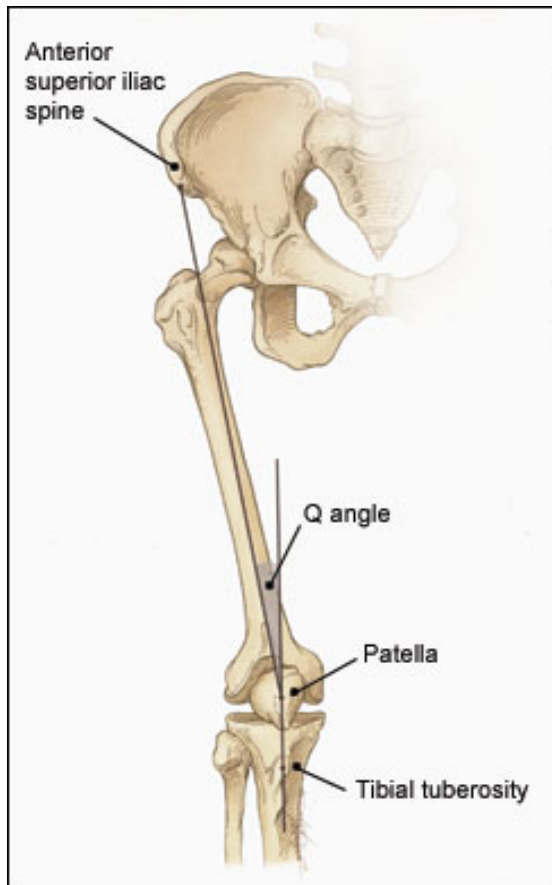
1B: Thermography scan of the anterior knees showing thermal asymmetry in a patient with patellofemoral pain syndrome.

Normal Symmetry



1A: Thermography scan of the anterior knees showing thermal symmetry (normal).

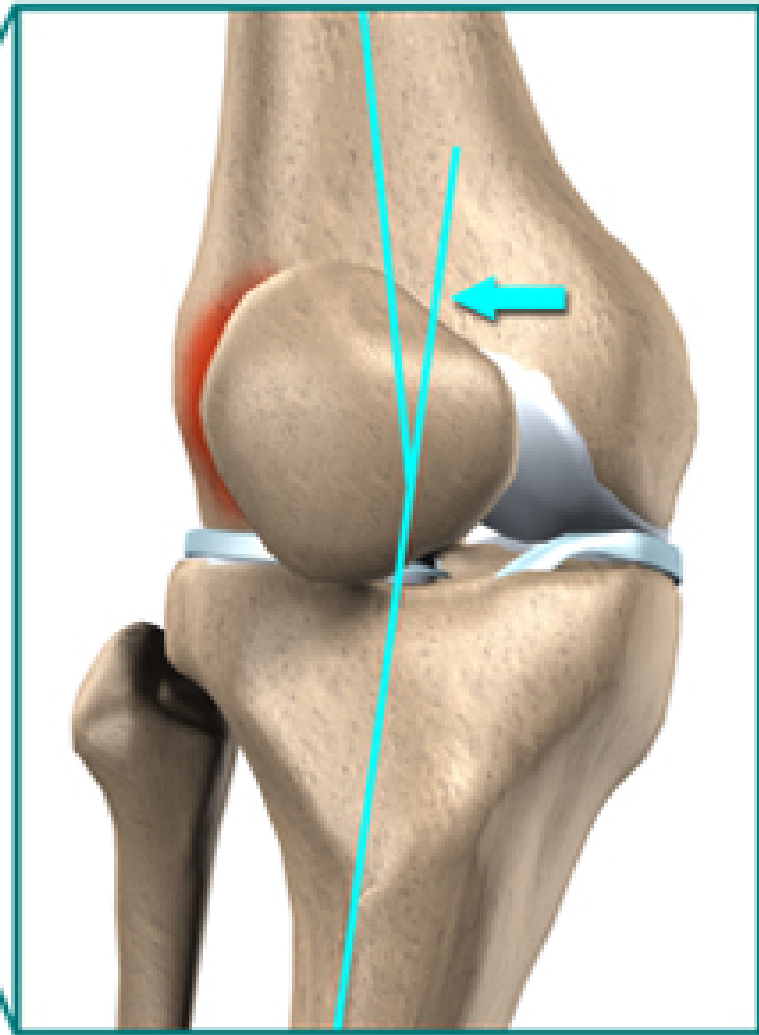
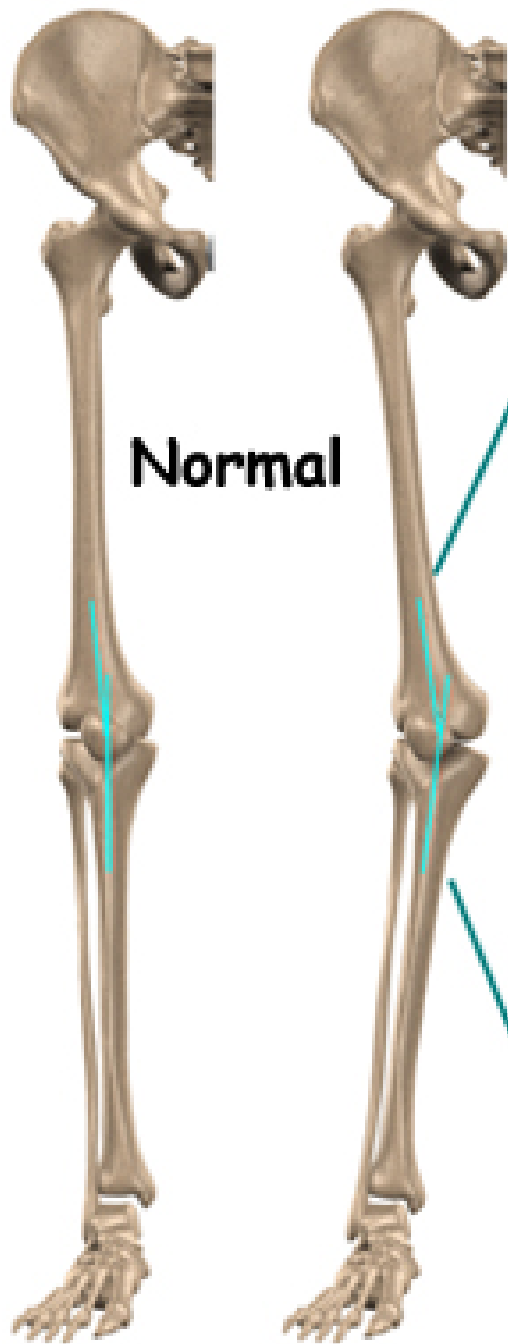
Quadriceps Angle “Q Angle”



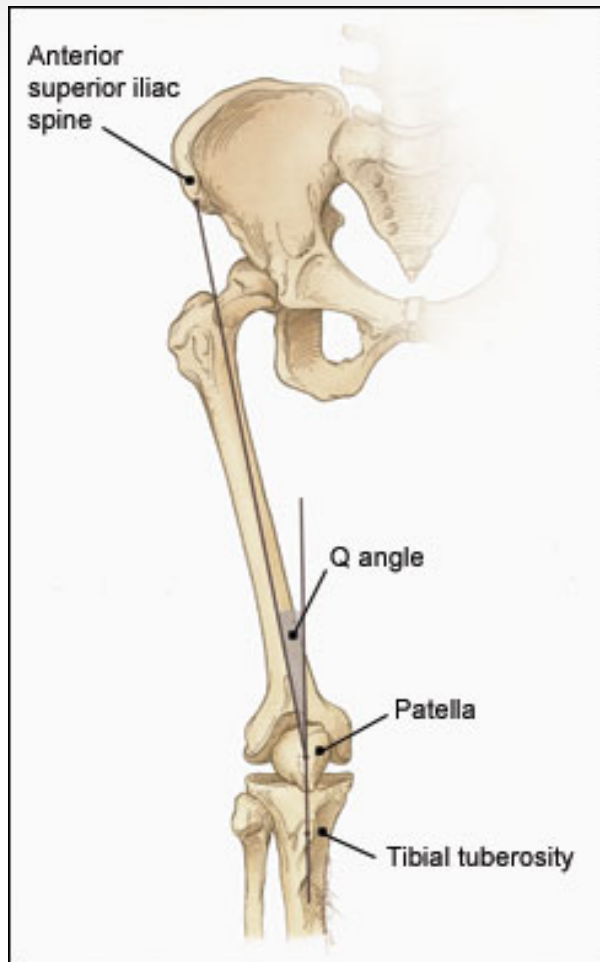
Copyright © 2003 Floyd E. Hosmer

- Adults typically 15 degrees
- Increases or decreases in the q-angles are associated in cadaver models with increased peak patellofemoral contact pressures (Huberti & Hayes, 1984).



Abnormal Q angle



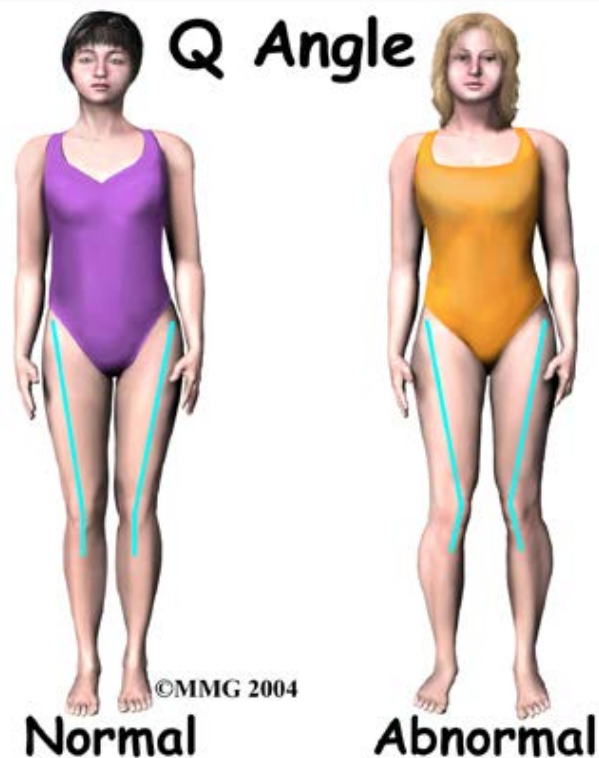Increased Q Angle




- Femoral anteversion
- External tibial torsion
- Laterally displaced tibial tubercle
- Genu valgus



Quadriceps Angle “Q Angle”



- Insall, Falvo, & Wise (1976) implicated increased q-angle, along with patella alta, in a prospective study of patellofemoral pain.



Patellofemoral Dysfunction

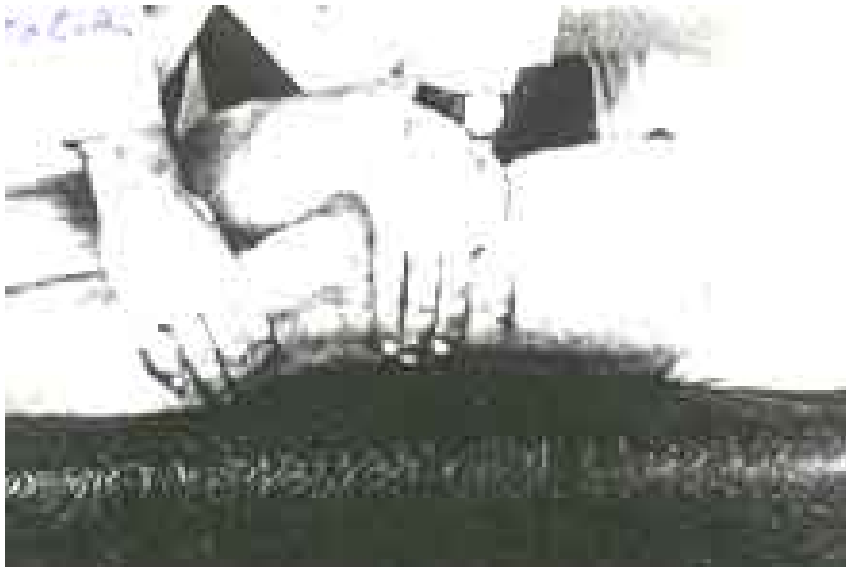Patella Grinding Test



- Chondromalacia patellae
- Patellofemoral arthralgia
- Chondral fracture

Patellofemoral Dysfunction

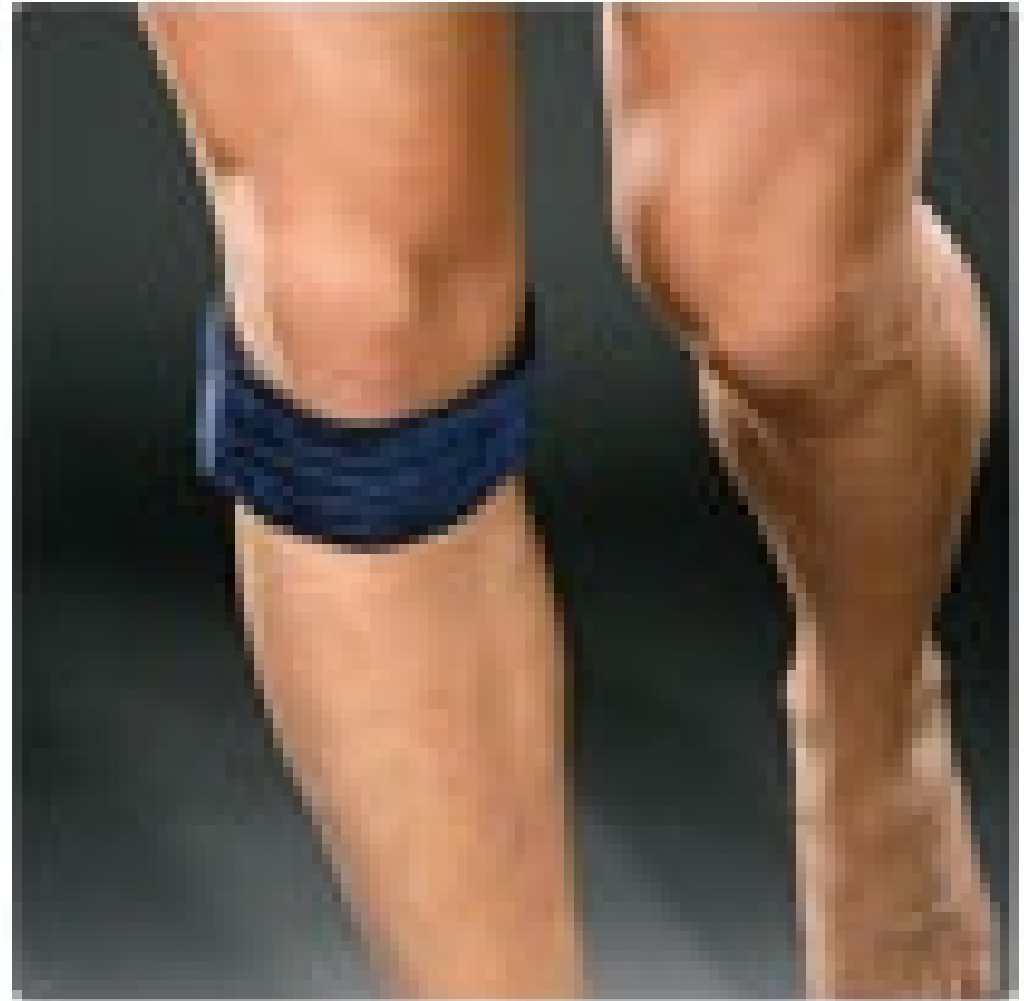Clarke's Patellar Scrape Test



- Pain and crepitation may indicate patellofemoral arthralgia or chondromalacia patellae

M-Brace® Jumper's Knee Brace


- For apophysitis, patellar chondromalacia, patellofemoral arthralgia, or jumper's knee.
- Alleviates pain by diminishing tension on muscles and ligaments.




Management

1. PRICEMM
2. NSAIDS
3. HVG with ice
4. PRE: Vastus medialis last 20-30 degrees of extension
5. Spinal manipulation
6. Myofascial trigger point pressure release
7. Orthotics







Did I mention...




- Diagnosis is the key to successful treatment!






Thank You!





Persistent Anterior Knee Pain

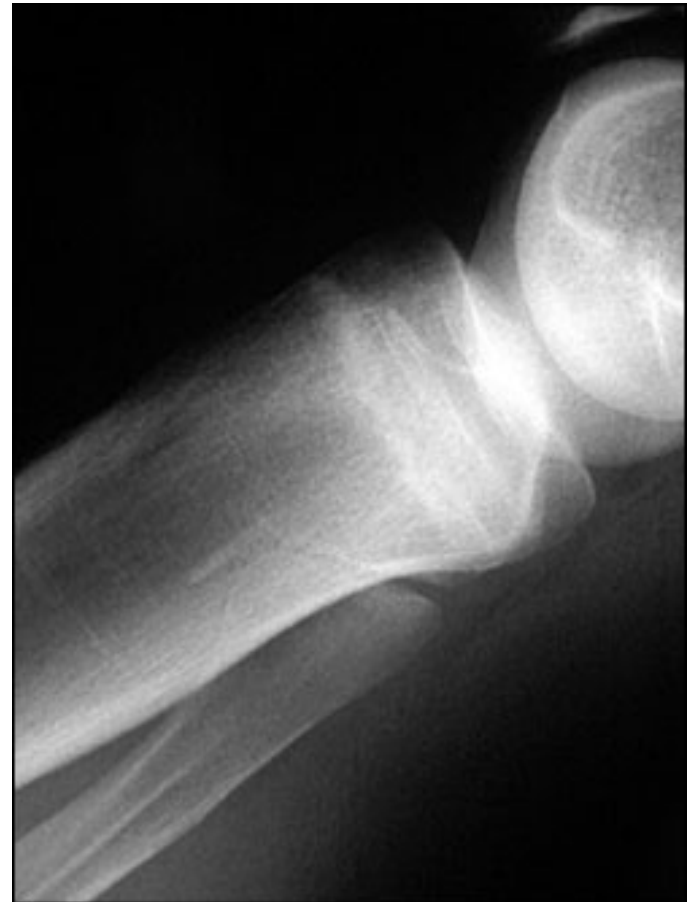- A 20-year-old military recruit presented for follow-up of anterior knee pain. Previously, he presented with three weeks of right knee pain without trauma, swelling, locking, or instability. At that visit, he was referred for physical therapy, but the knee did not improve during treatment. On recent examination, the patient had a positive “theater sign” (i.e., knee pain upon arising after prolonged sitting), positive patellar compression and inhibition tests, stable ligaments, pain with McMurray's test, and tenderness of the medial tibial plateau.



Question

- Based on the patient's history, physical examination, and radiography results, which one of the following is the most likely diagnosis?
- A. Medial plica syndrome.
- B. Patellar tendinopathy.
- C. Patellofemoral pain syndrome.
- D. Pes anserine bursitis.
- E. Proximal tibial stress fracture.

Atraumatic, Persistent, Anterior Knee Pain




Discussion

- The answer is E: proximal tibial stress fracture. Most tibial stress fractures occur in the tibial diaphysis. However, proximal tibial stress fractures, typically involving the medial condyle, can occur in athletes. Stress fractures may result from weaker bone that fails under normal loading (i.e., an insufficiency fracture) or normal bone that fails under new or increased repetitive loading (i.e., a fatigue fracture). Athletes are more likely to experience a fatigue fracture; military recruits are also at risk.


Drabicki RR, Greer WJ, DeMeo PJ. Stress fractures around the knee. *Clin Sports Med.* 2006;25:105–15.

Raasch WG, Hergan DJ. Treatment of stress fractures: the fundamentals. *Clin Sports Med.* 2006;25:29–36.



Discussion


- Medical history that suggests a stress fracture will include persistent pain following an acute increase in physical activity (i.e., time, distance, or pace). Physical examination may reveal tenderness at or near the medial joint line, tenderness with a leverage motion, and tenderness with hopping on the affected leg. A joint effusion may also be present.




Discussion

- Plain radiographs can appear normal for weeks or even months. Because the metaphyseal portions of long bones are mostly cancellous bone, the typical periosteal/endosteal reaction will not be visible. In this type of bone, the features of a stress fracture manifest as a **band-like area of sclerosis**. If a stress fracture is suspected but radiographic results are normal, then magnetic resonance imaging (MRI) or a bone scan is the next diagnostic study. Of the two, MRI is more sensitive for diagnosing stress fracture.






One Final Thought...






- Diagnosis is the key to successful treatment!




American Association of Family Practic Journal

- <http://www.aafp.org/afp/2005/0315/p1169.html>
- <http://www.aafp.org/afp/20000415/2391.html>




<http://www.aafp.org/afp/20000315/1795.html>

- **Management of Osteoarthritis of the Knee** Nonpharmacologic treatment (e.g., patient education and support, exercise, weight loss, joint protection) *plus* Acetaminophen (Tylenol) in a dosage of up to 4 g per day to control pain and other symptoms, and before activity Add topical capsaicin cream (e.g., ArthriCare) applied four times daily, if needed.
- If joint effusion is present, consider aspiration and intra-articular injection of a corticosteroid, such as 40 mg of triamcinolone (Aristocort).
- If more pain or symptom control is needed, add an NSAID in a low dosage, such as 400 mg of ibuprofen (e.g., Advil) taken four times daily, or a nonacetylated salicylate such as choline magnesium trisalicylate (Trilisate) or salsalate (Disalcid).
- If more pain or symptom control is needed, use the full dosage of an NSAID, plus misoprostol (Cytotec) or a proton pump inhibitor if the patient is at risk for upper gastrointestinal tract bleeding or ulcer disease, or substitute a cyclo-oxygenase-2 inhibitor for the NSAID; some patients may benefit from intra-articular injections of a hyaluronic acidlike product.
- If the response is inadequate, consider referring the patient for joint lavage, arthroscopic debridement, osteotomy or joint replacement.



MUA tkr

- http://xnet.kp.org/permanentejournal/NIR/Publications/Articles/Early_Late_Manipulations_TKA.pdf



Evaluation and Management of PFA by Hammer

- <http://www.dynamicchiropractic.com/mpacms/dc/article.php?id=44165>
- <http://www.dynamicchiropractic.com/mpacms/dc/article.php?id=44278>
- <http://www.dynamicchiropractic.com/mpacms/dc/article.php?id=44232>
- <http://www.dynamicchiropractic.com/mpacms/dc/article.php?id=17905>