

Differential Diagnosis Functional vs Structural Scoliosis

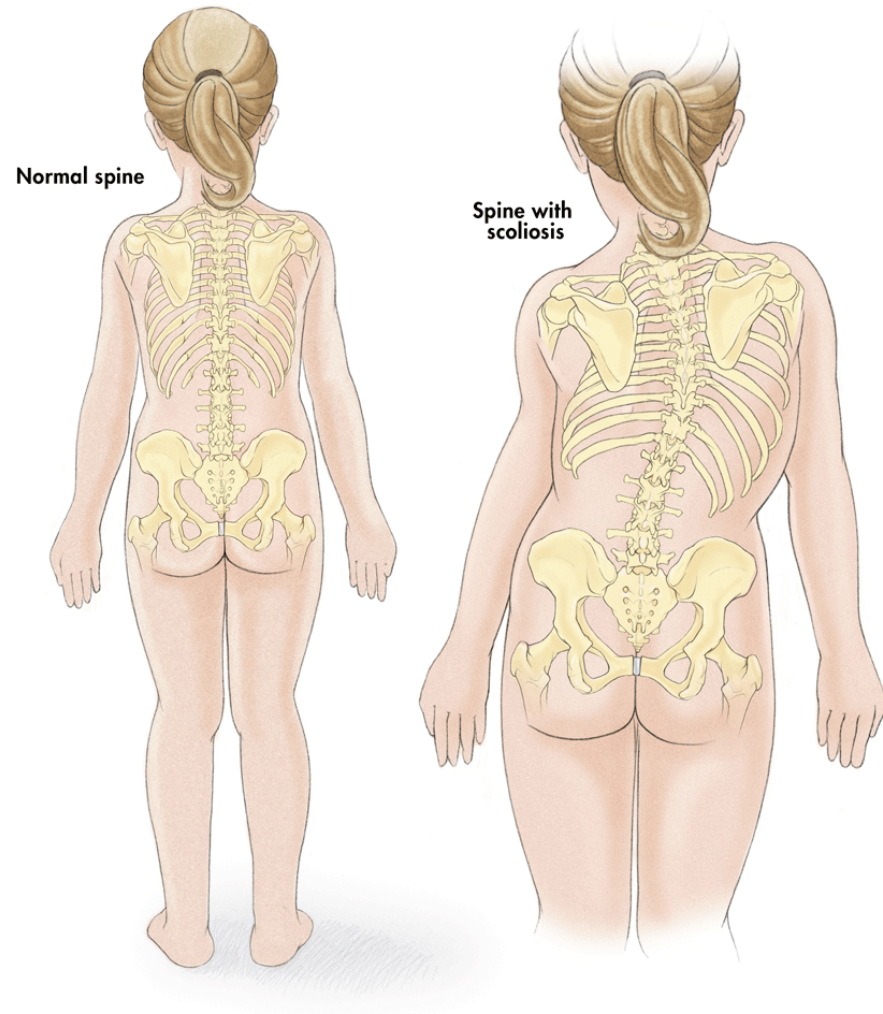
James J. Lehman, DC, MBA, FACO
Associate Professor of Clinical Sciences
University of Bridgeport College of Chiropractic
Director
Community Health Clinical Education
University of Bridgeport

Diagnosis is the key to successful
treatment



Scoliosis Classification

Based upon the findings with this postural presentation, what physical examination procedures would you perform to determine your working diagnosis for the child with scoliosis?



Classification of Scoliosis

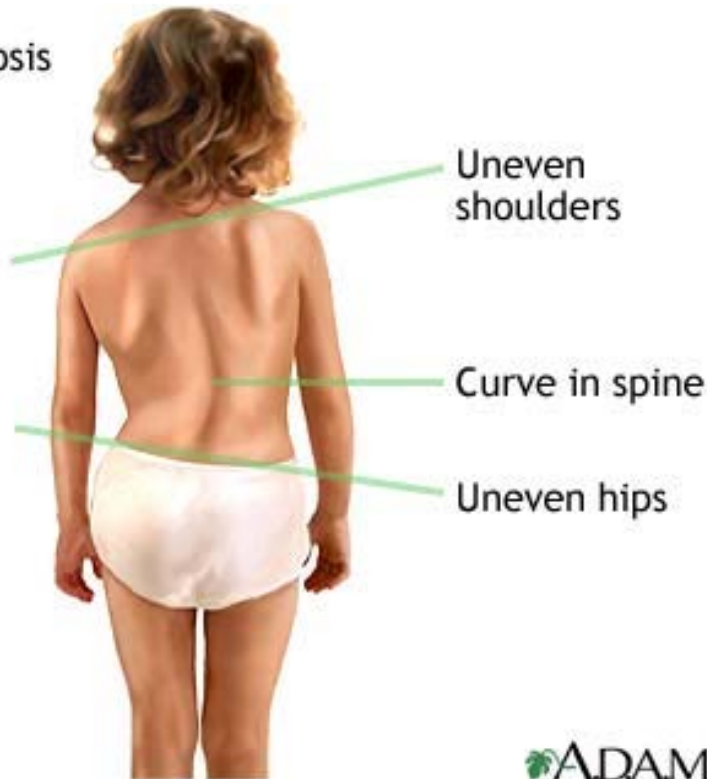
Structural or Nonstructural (functional)



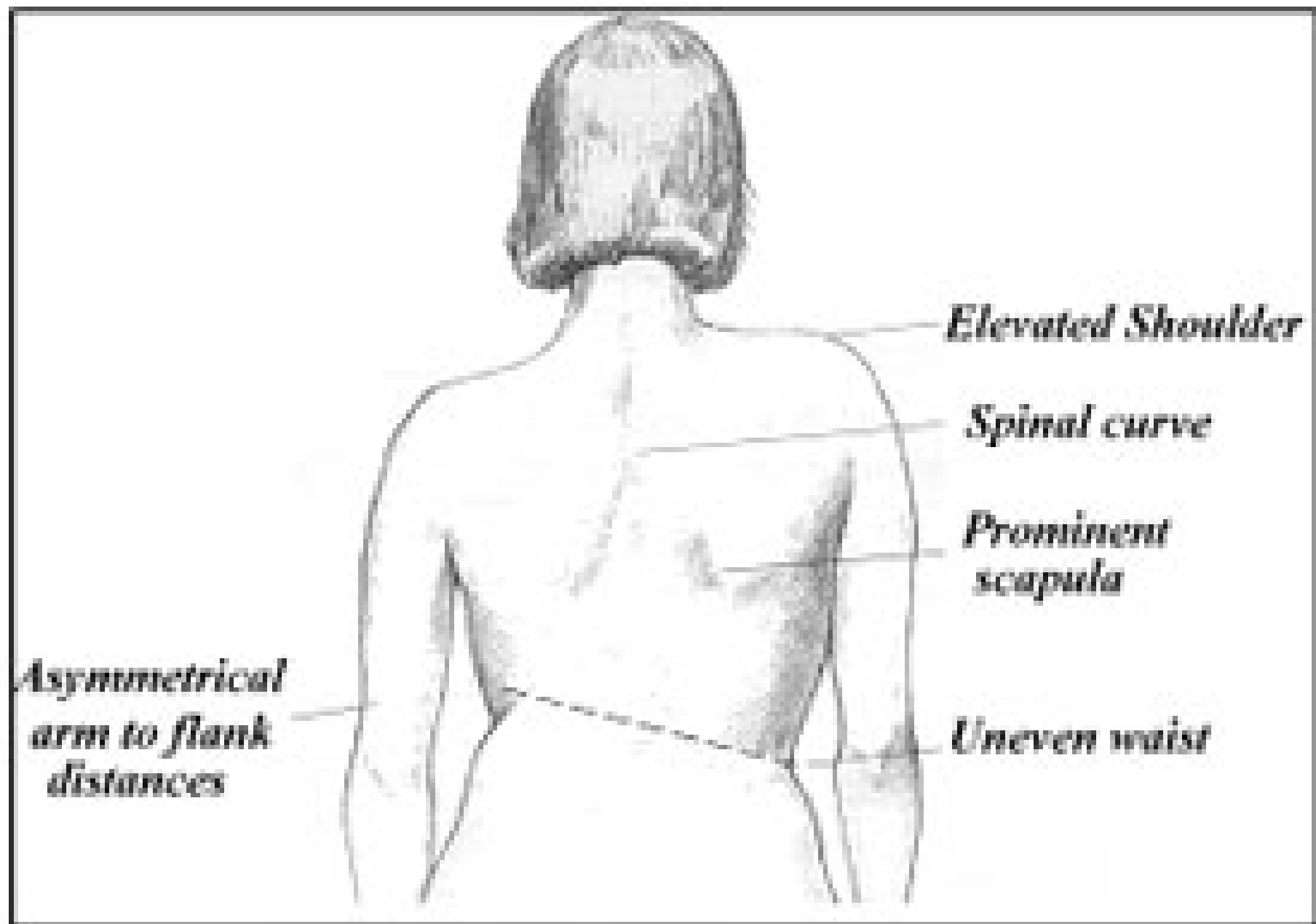
1. Structural curves are fixed, nonflexible, and fail to correct with bending.
2. Nonstructural curves are not fixed but flexible and readily correct with bending.

Postural Evaluation of Spine

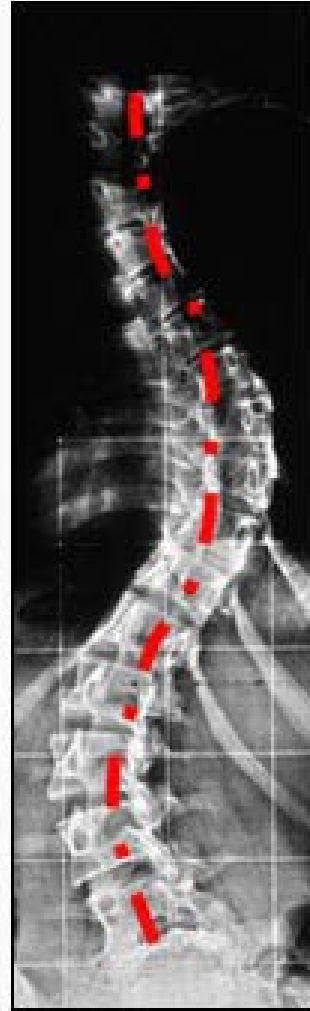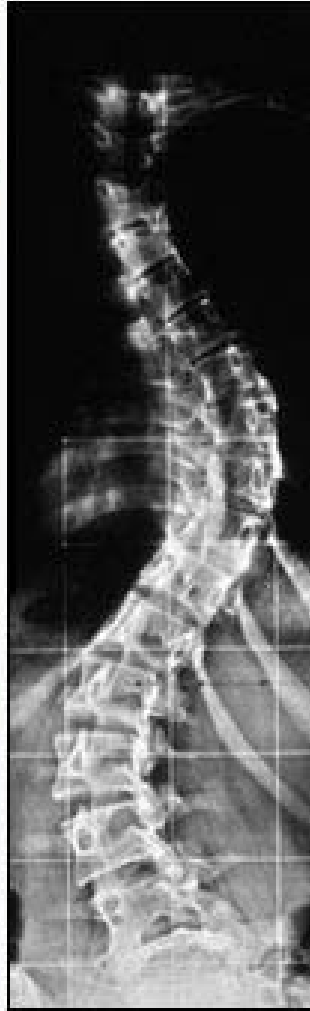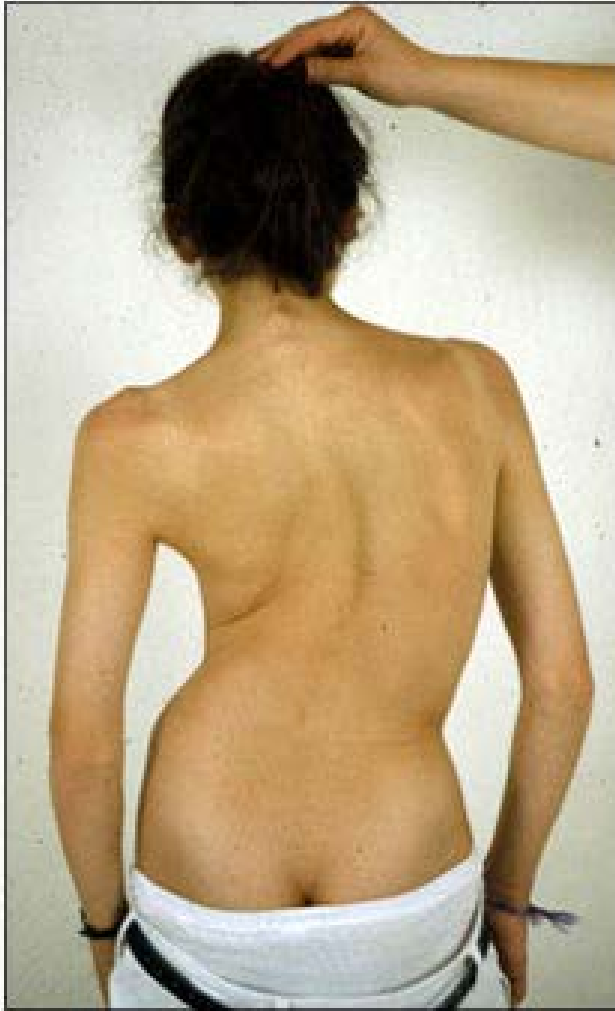Signs of scoliosis



- Observation of standing posture
- Right thoracic curve is most common with best prognosis



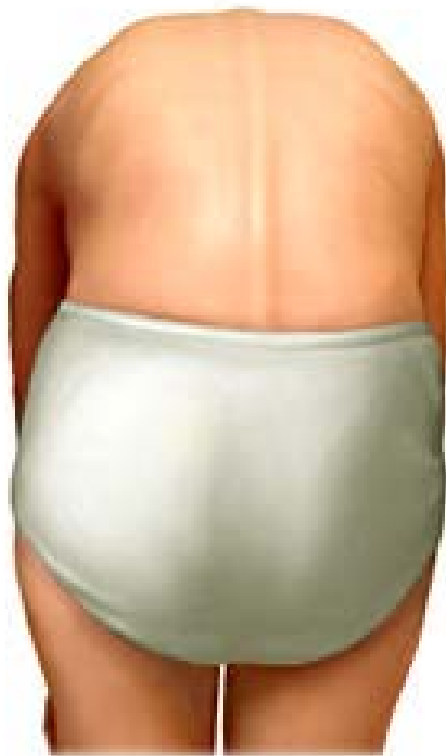Important physical exam findings in scoliosis



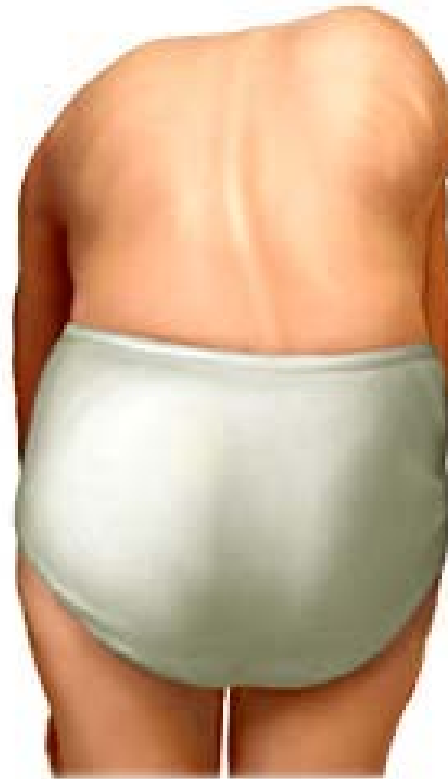Scoliosis is a lateral deviation in the frontal plane associated with rotation.

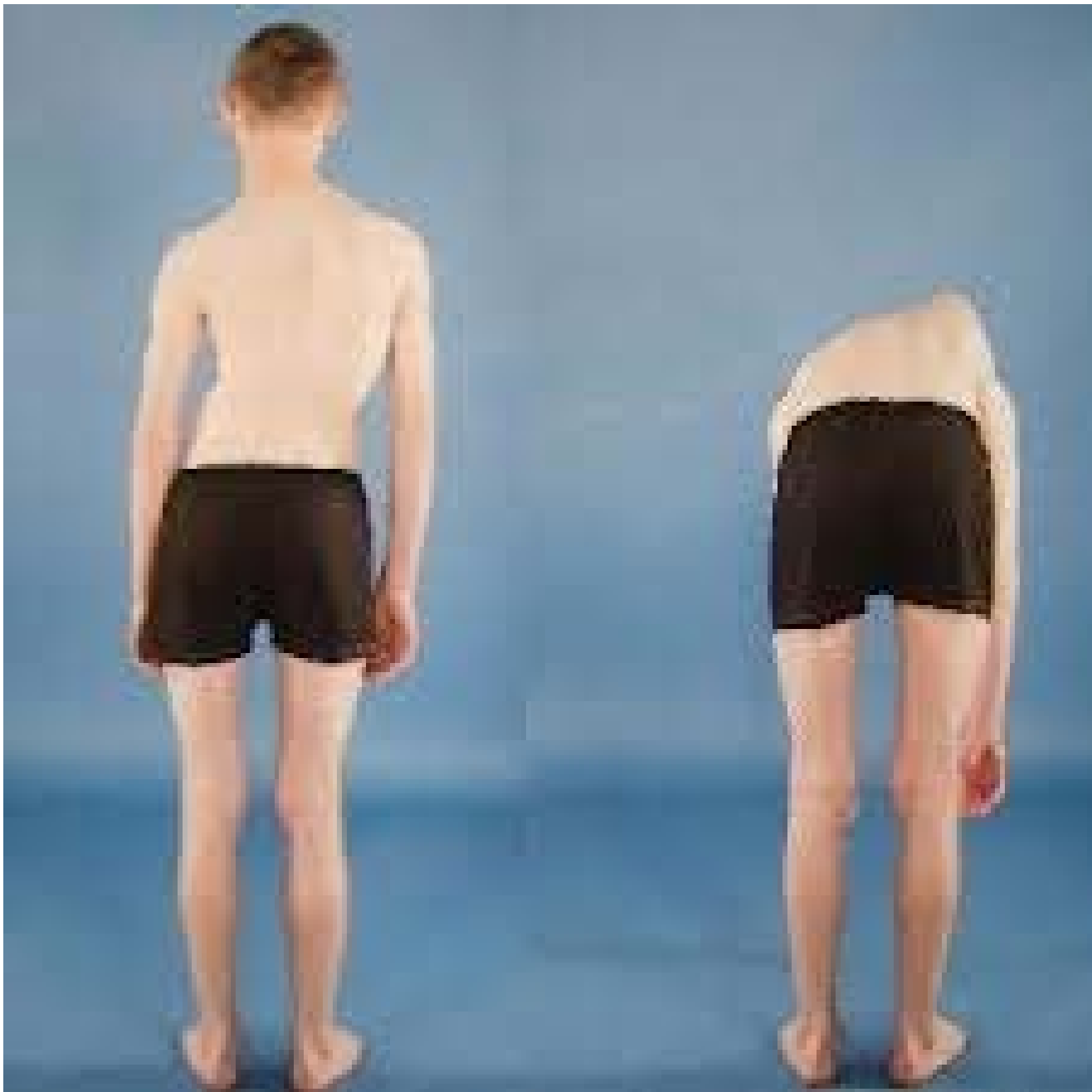Adam's Position

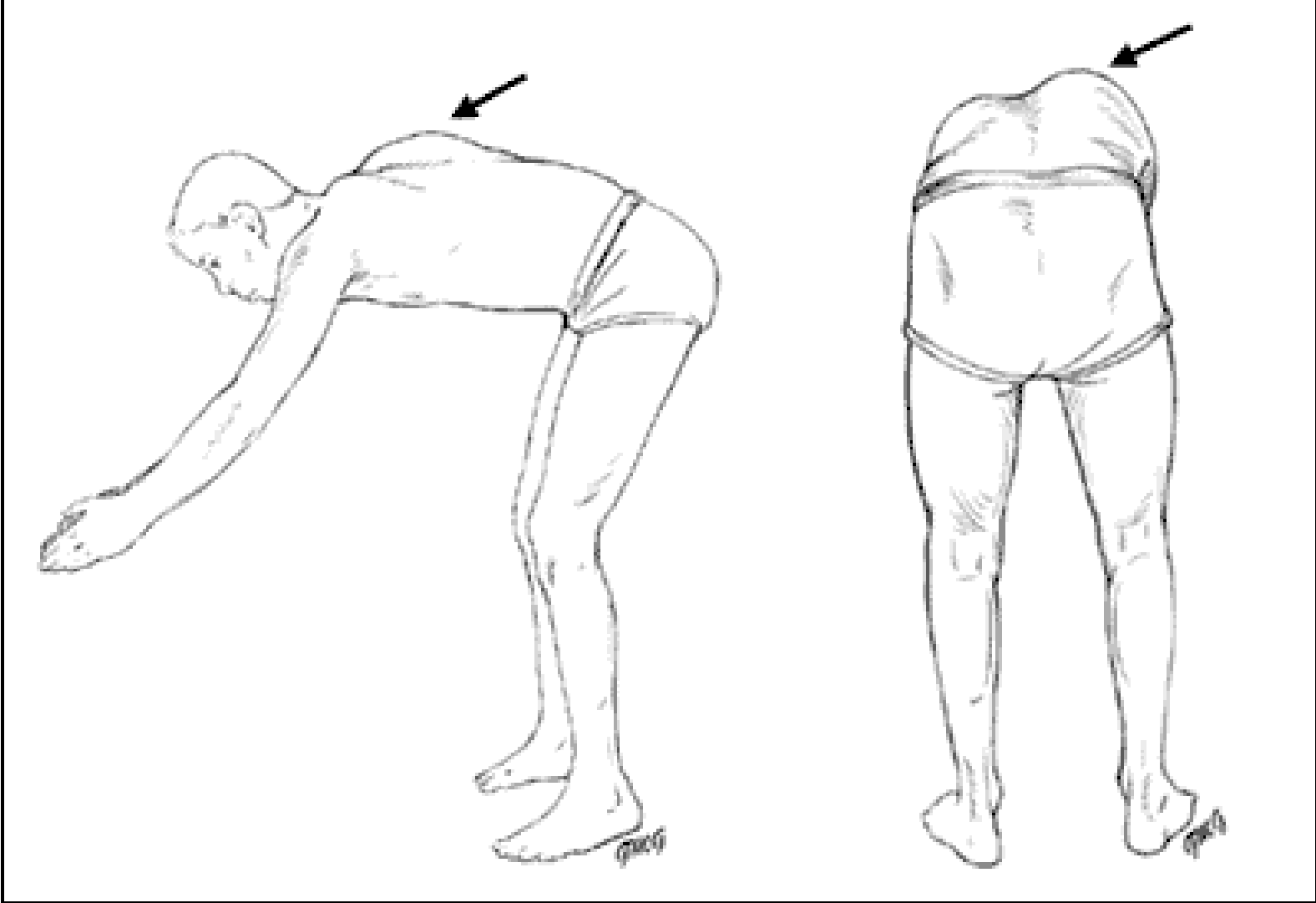
Normal spine



Deformity from scoliosis



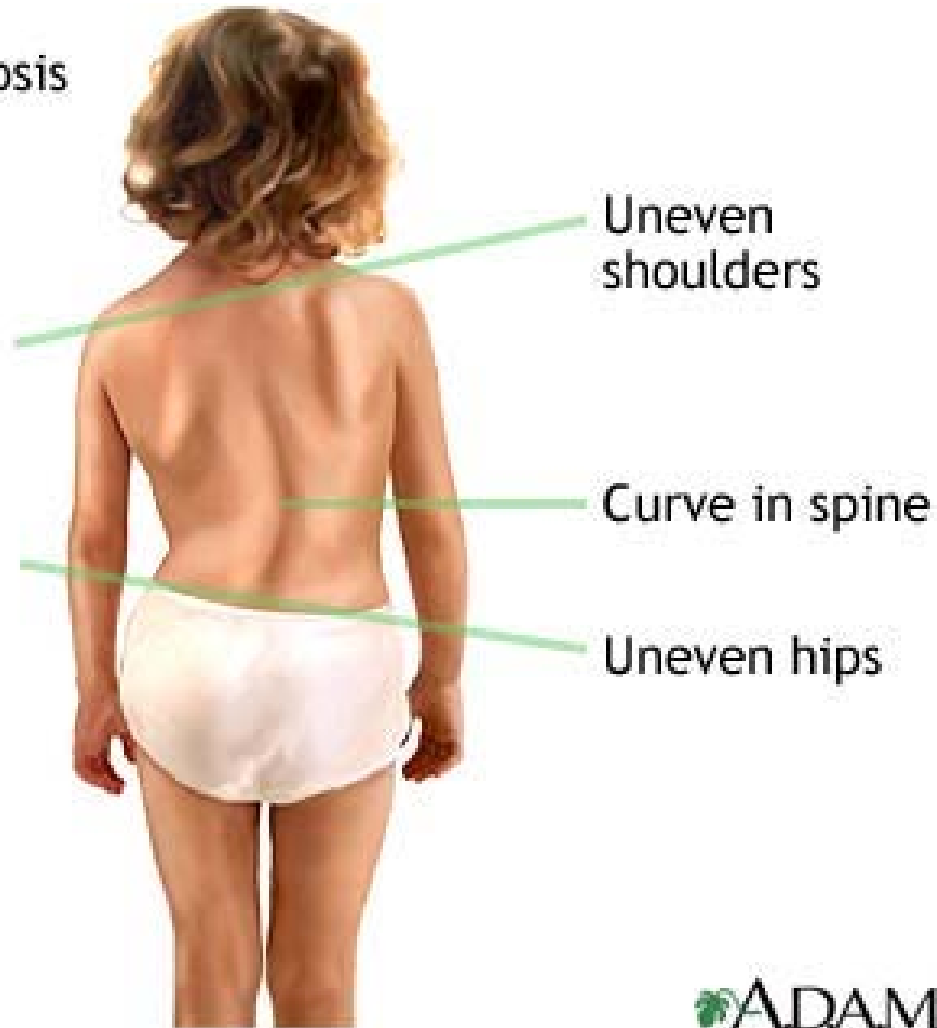




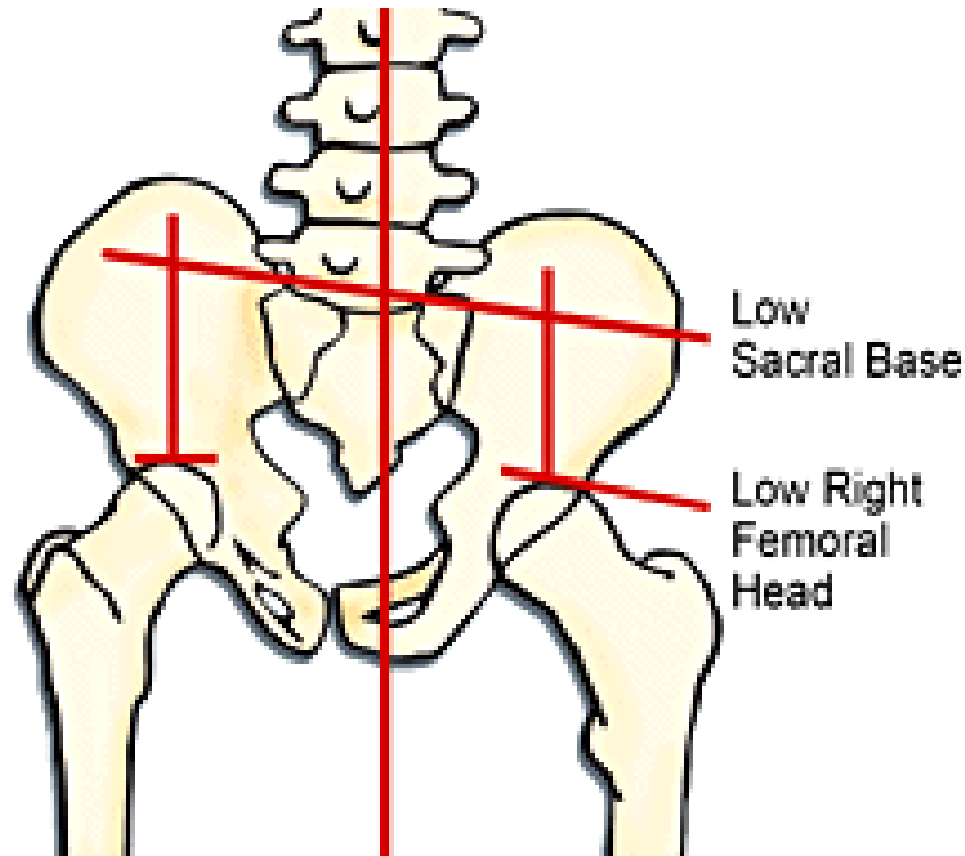
Differential Diagnosis

Functional Scoliosis/Postural Imbalance

Signs of scoliosis

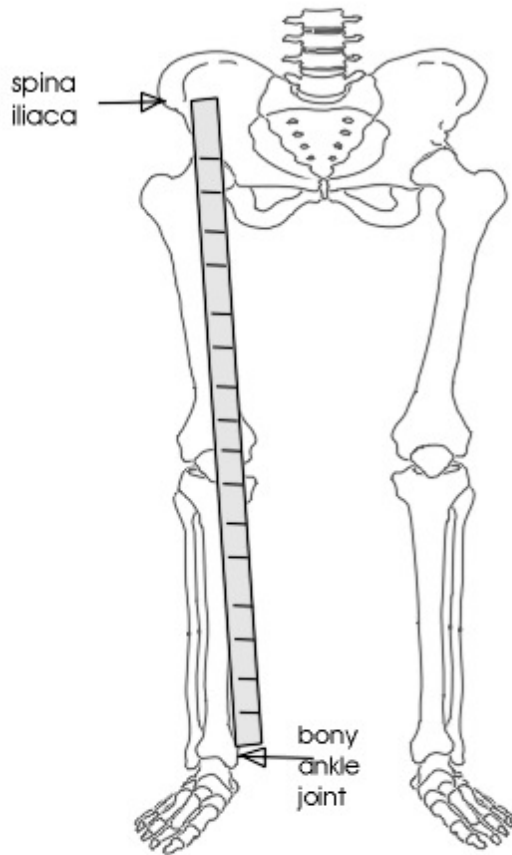


Pelvic Obliquity and Postural Imbalance



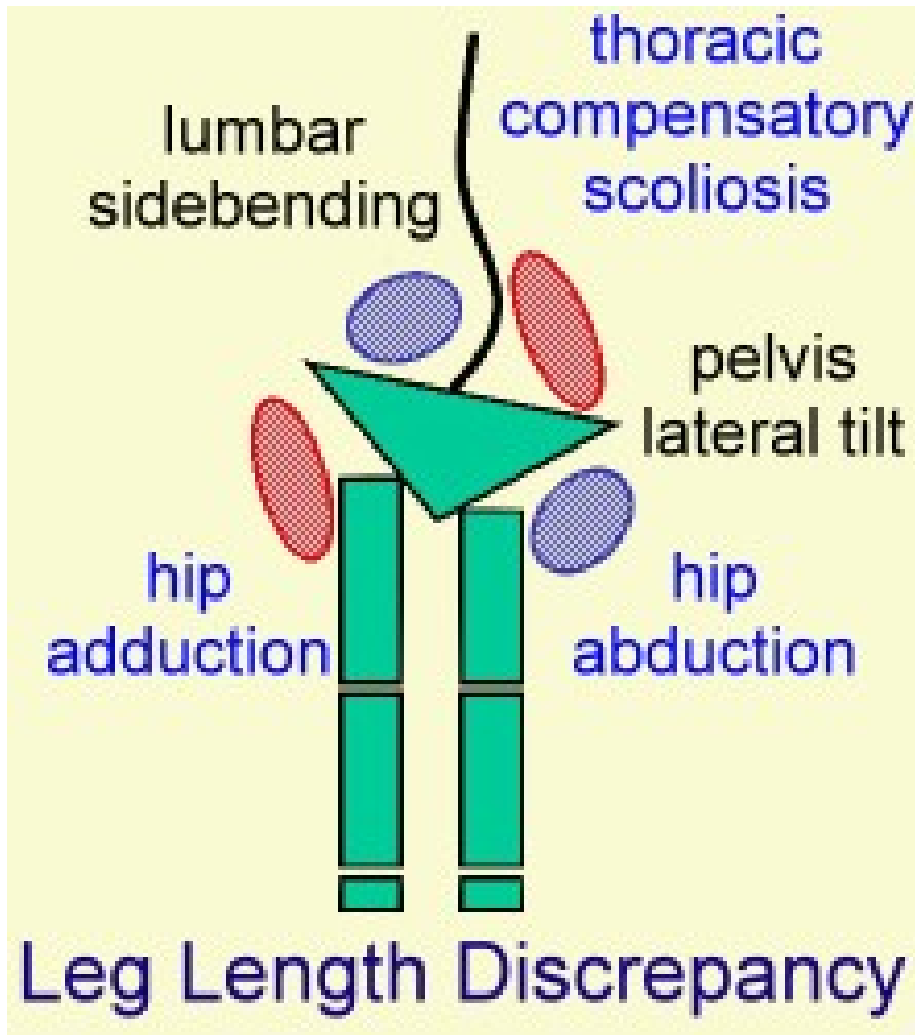
- You must determine whether the leg length discrepancy is anatomical or functional

Actual Leg-Length Test



- This is a tape measurement that tests for anatomical leg length discrepancy.
- ASIS and medial malleolus are the landmarks identified

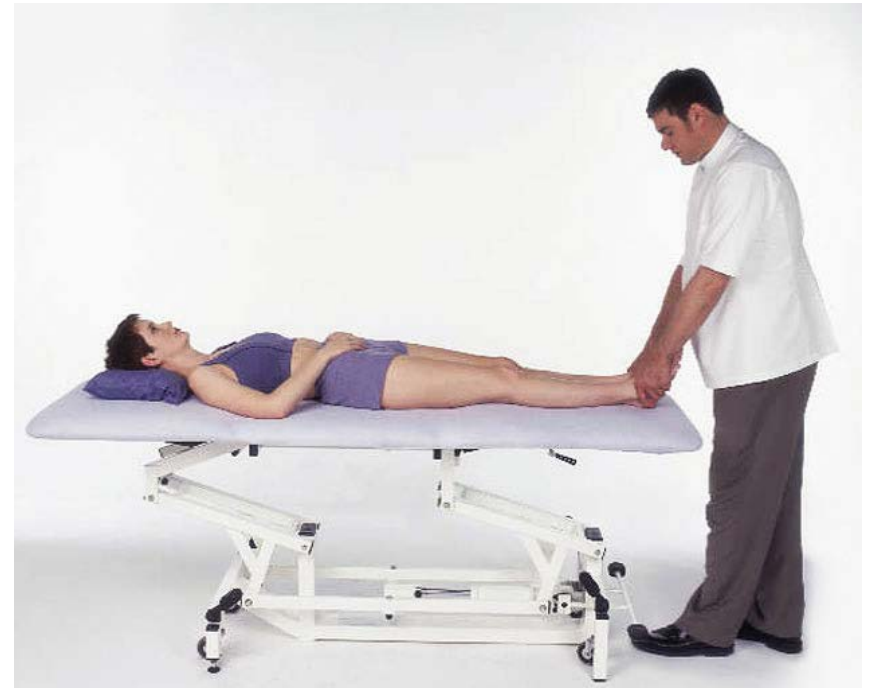Apparent Leg-Length Test



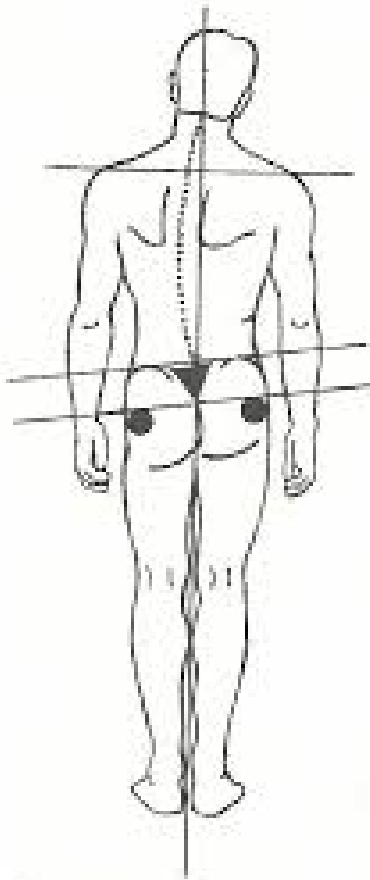
- Reveals functional leg length discrepancy
- Umbilicus and medial malleolus are landmarks
- Evans

Functional Leg-Length Measurement

- Measure length of both lower extremities supine and seated
- Inferior medial malleoli are used as landmarks
- Read the body language



Functional Leg-Length Measurement

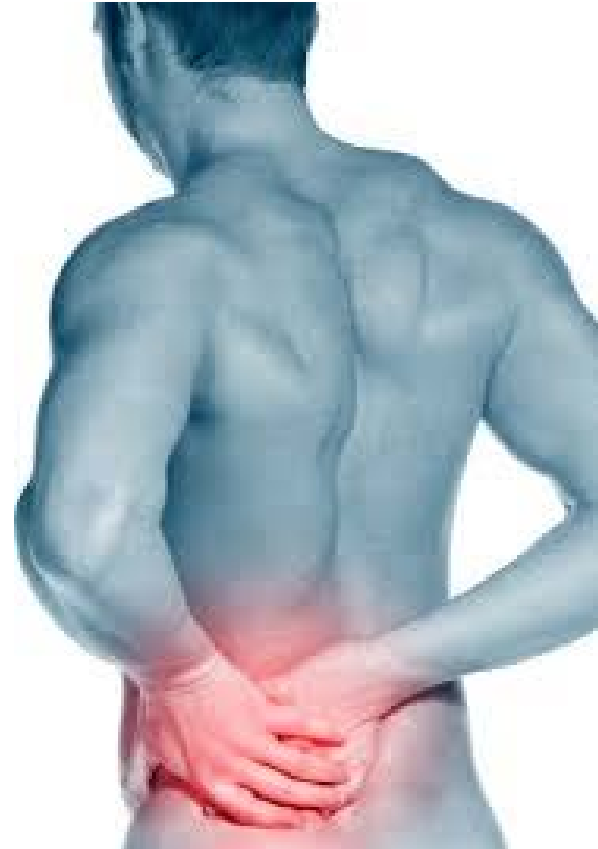

- Usually the ipsilateral malleolus will measure short when supine if the superior iliac crest appears inferior when standing and long when seated

Figure 13.23. Muscular distortion pattern 1.

Clinical Value of Long Sit Test

- Pelvic Obliquity
- Leg Length Discrepancy
 - Functional
 - Anatomical
- SIJ Dysfunction
- Spinal manipulation



VIDEO: SUPINE TO LONG SIT TEST

[HTTP://WWW.THESTUDENTPHYSICALTHERAPIST.COM/SUPINE-TO-LONG-SIT-TEST.HTML](http://www.thestudentphysicaltherapist.com/supine-to-long-sit-test.html)

LEVANGIE PK. "FOUR CLINICAL TESTS OF SACROILIAC JOINT DYSFUNCTION: THE ASSOCIATION OF TEST RESULTS WITH INNOMINATE TORSION AMONG PATIENTS WITH AND WITHOUT BACK PAIN." PHYS THER. 1999 NOV;79(11):1043-57.

An Alternative Conclusion

Michael T Cibulka, Kady Aslin

<http://ptjournal.apta.org/content/80/4/414.long>

- Levangie's conclusion that the “data do not support the value of these tests in identifying innominate torsion” appears to be correct, based on her calculations of the odds ratios.
- However, an alternative conclusion could also be obtained from her published performance characteristics (eg: sensitivity, specificity).
- In Table 4, Levangie reports the specificity of the Gillet test as 93% and of the sitting flexion test also as 93%. A high test result (90% or higher) effectively rules in the target disorder or conditions.¹
- Therefore, according to the data, the Gillet test and the sitting flexion test are effective tests to detect (rule in) innominate torsion.
- Thus, we believe that Levangie may have inadvertently left out this important interpretation of her data.

Etiology

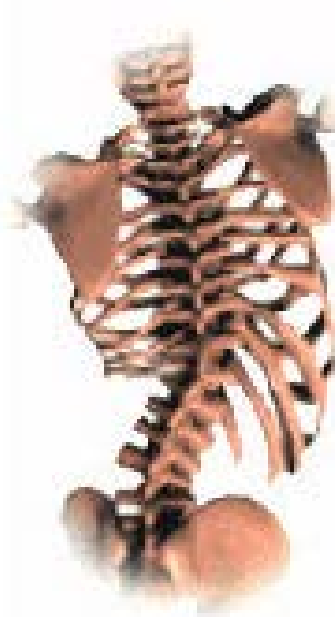Adolescent Idiopathic Scoliosis (AIS)

- The exact pathophysiologic mechanism for AIS is unknown.
- A genetic factor has been implicated in the development and progression of scoliosis.

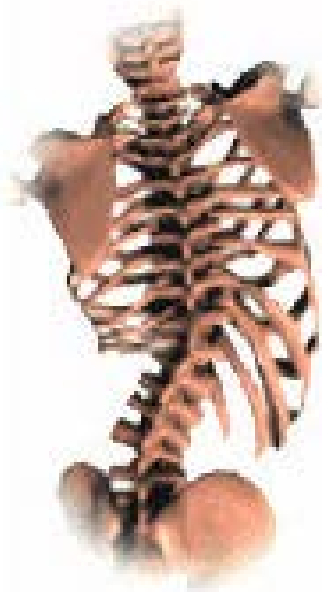- Reamy BV, Slakey JB. Adolescent idiopathic scoliosis: review and current concepts. *Am Fam Physician*. 2001;64(1):111–116.
- Ogilvie J. Adolescent idiopathic scoliosis and genetic testing. *Curr Opin Pediatr*. 2010;22(1):67–70.

Etiology

- If both parents have idiopathic scoliosis, their children are 50 times more likely to require scoliosis treatment compared with the general population.
- Smith JR, Sciubba DM, Samdani AF. Scoliosis: a straightforward approach to diagnosis and management. *JAAPA*. 2008;21(11):40-45.



- Adolescent idiopathic scoliosis (AIS) is the most common spinal deformity affecting 2% of the population.



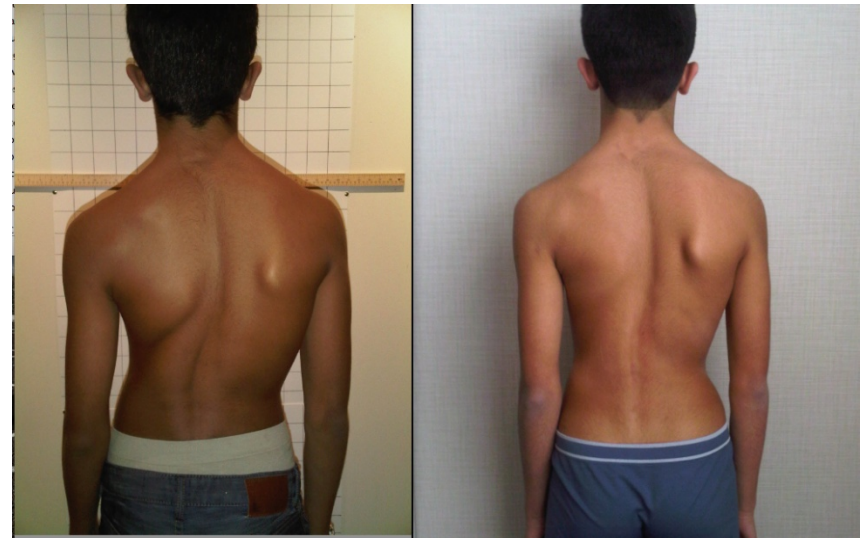- Ogilvie J. Adolescent idiopathic scoliosis and genetic testing. *Curr Opin Pediatr.* 2010 Feb;22(1):67-70.

Adolescent Idiopathic Scoliosis

- Adolescent idiopathic scoliosis is present in 2 to 4 percent of children between 10 and 16 years of age.
- It is defined as a lateral curvature of the spine greater than 10 degrees accompanied by vertebral rotation.

Adolescent Idiopathic Scoliosis

- Initial diagnosis is straightforward.
- Determining which curves will progress and warrant intervention is still problematic.
- Ogilvie J. Adolescent idiopathic scoliosis and genetic testing. *Curr Opin Pediatr.* 2010 Feb;22(1):67-70.



Differential Diagnosis

Back Pain

- Back pain is fairly prevalent in healthy children and adolescents.
- When children or adolescents seek medical care for back pain, it is highly likely that underlying pathology will be identified.

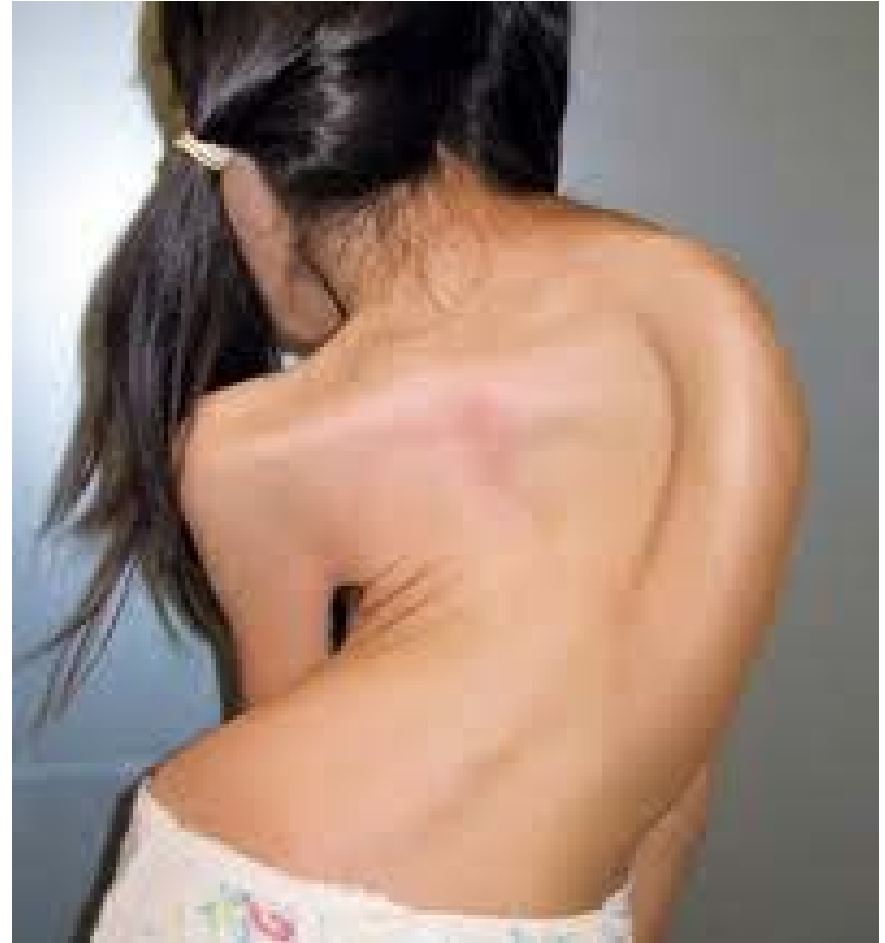Differential Diagnosis

Back Pain

- Common causes of back pain include nonspecific pain or muscle strain, herniated disk, spondylolysis, scoliosis, and Scheuermann's kyphosis.
- Bernstein RM and Cozen H. Evaluation of Back Pain in Children and Adolescents. *Am Fam Physician*. 2007 Dec 1;76(11):1669-1676.

Scoliosis

- Six million people have scoliosis in one form or another.
- National Scoliosis Foundation



Idiopathic Scoliosis

- The primary age range for onset of idiopathic scoliosis is 10-15, occurring equally in both genders but females are eight times more likely to progress to curve magnitude that requires intervention.
- National Scoliosis Foundation

Idiopathic Scoliosis

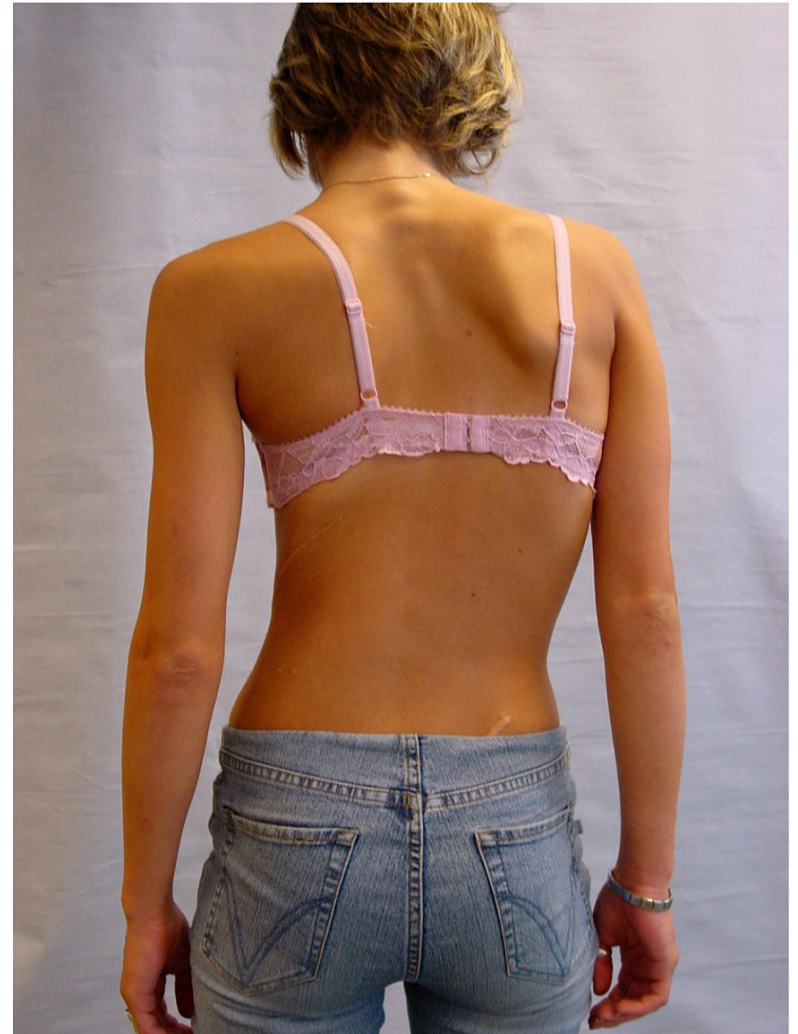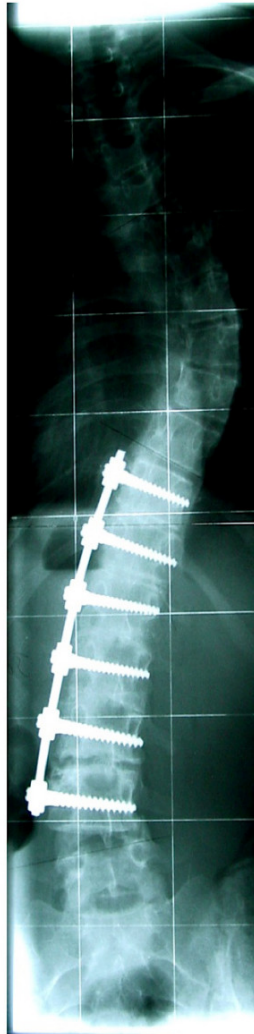
Idiopathic or degenerative scoliosis is the cause of:

600,000 physician visits annually

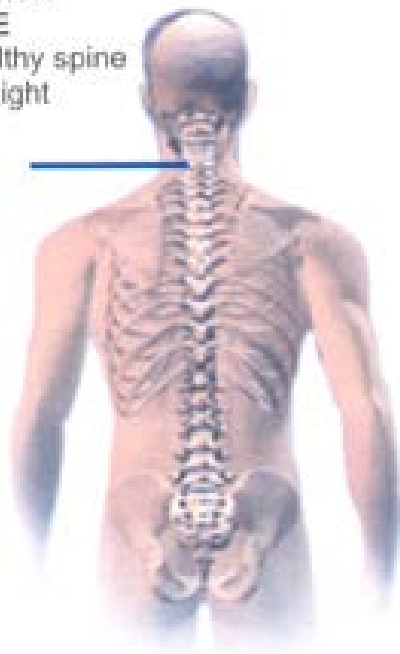30,000 children put in braces

38,000 spinal fusion surgeries

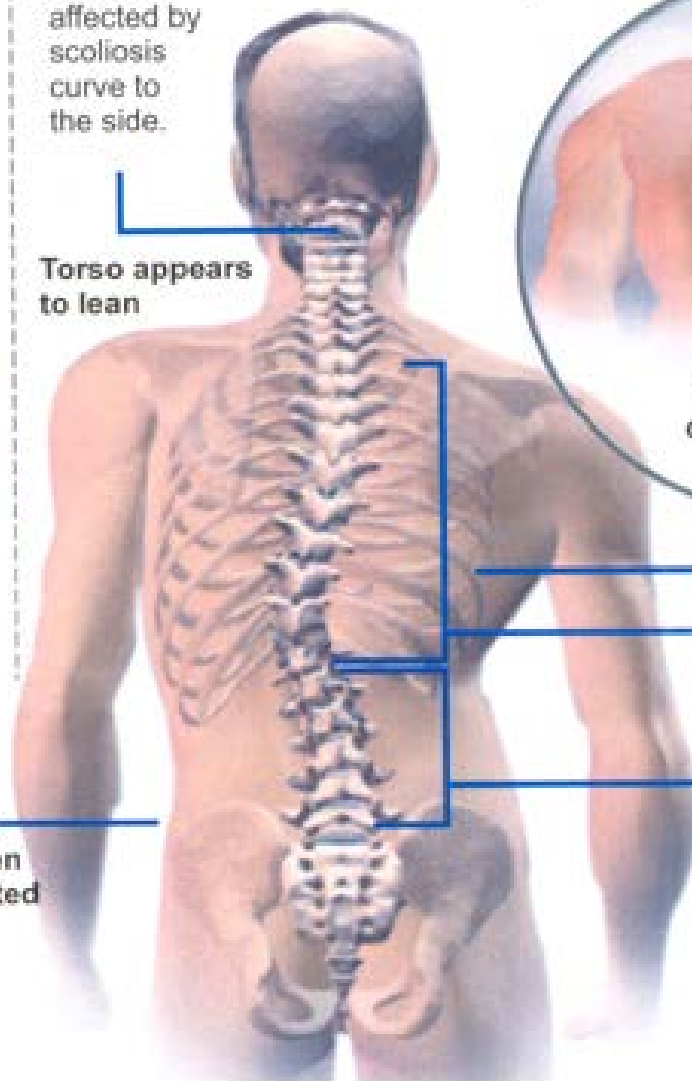(Source: National Scoliosis Foundation)



HEALTHY SPINE
A healthy spine is straight



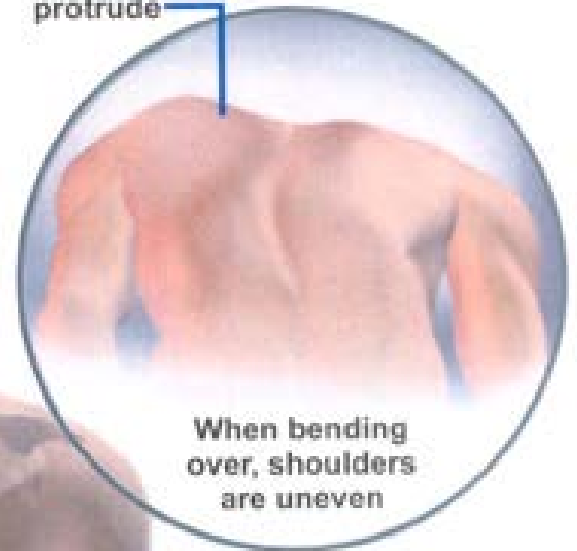
SYMPTOMS OF SCOLIOSIS
A spine affected by scoliosis curve to the side.



Torso appears to lean

Waist may appear uneven or hips elevated

One or both shoulder blades protrude



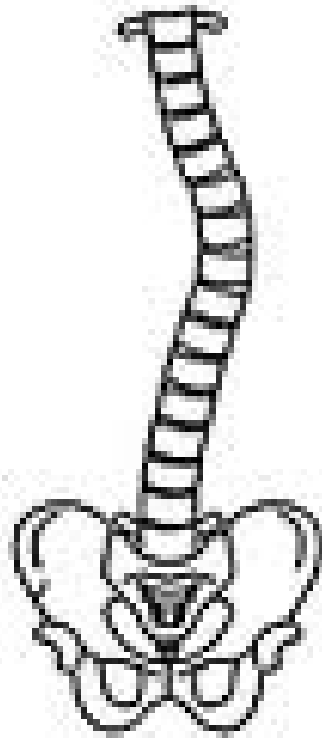
When bending over, shoulders are uneven

Misshaped rib cage

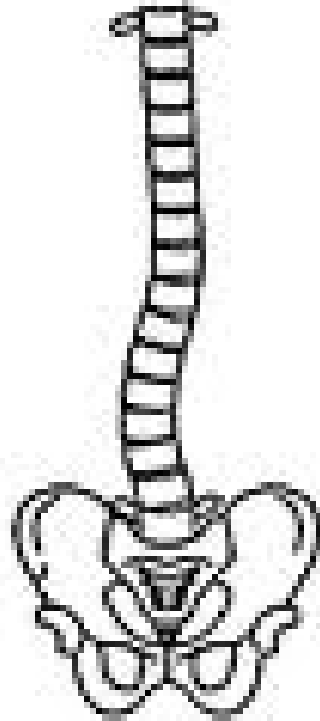
A curvature may be seen in the mid back (thorax) ...

... Or it may be seen in the lower back (lumbar).

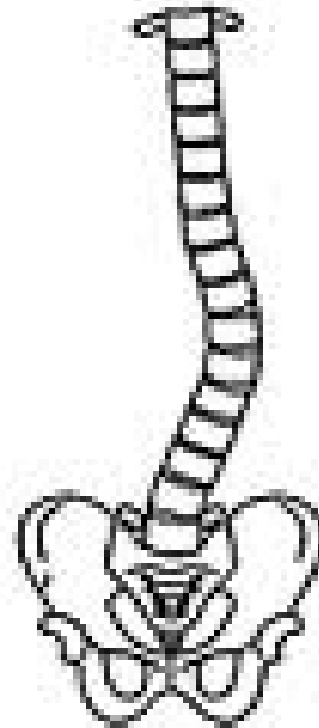
Curve Patterns



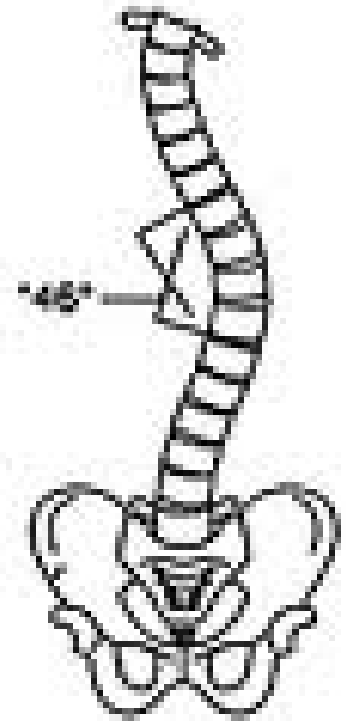
Thoracic



Lumbar



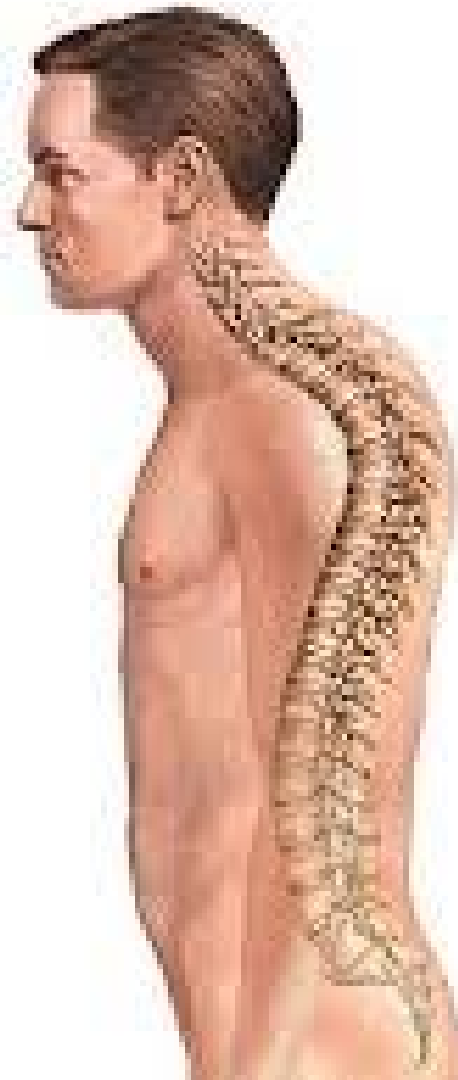Thoracolumbar



Double



Normal spine



Kyphotic spine

Scoliometer

- The Mizuho OSI Scoliometer™ provides a safe and efficient way to measure the degree of rotation of a deformity of the spine found on routine spinal examination.

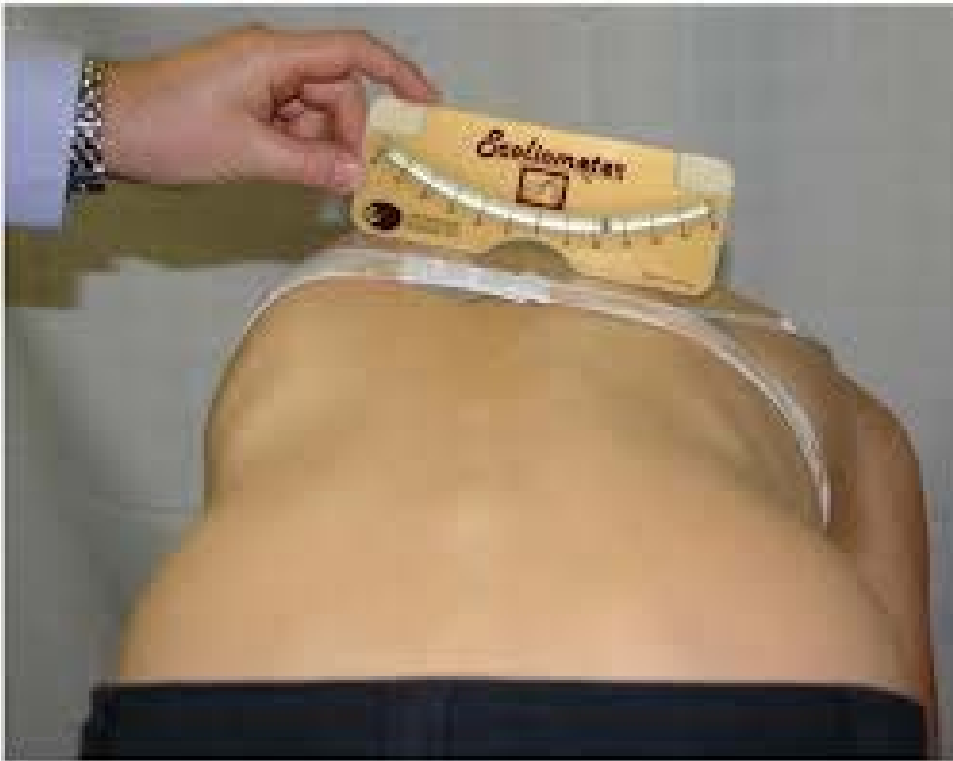

VIDEO: SPINE EXAMINATION WITH INCLINOMETER

BOSTON CHILDREN'S HOSPITAL

[HTTPS://WWW.YOUTUBE.COM/WATCH?V=RBWVRPKM-QE](https://www.youtube.com/watch?v=RBWVRPKM-QE)

Scoliometer

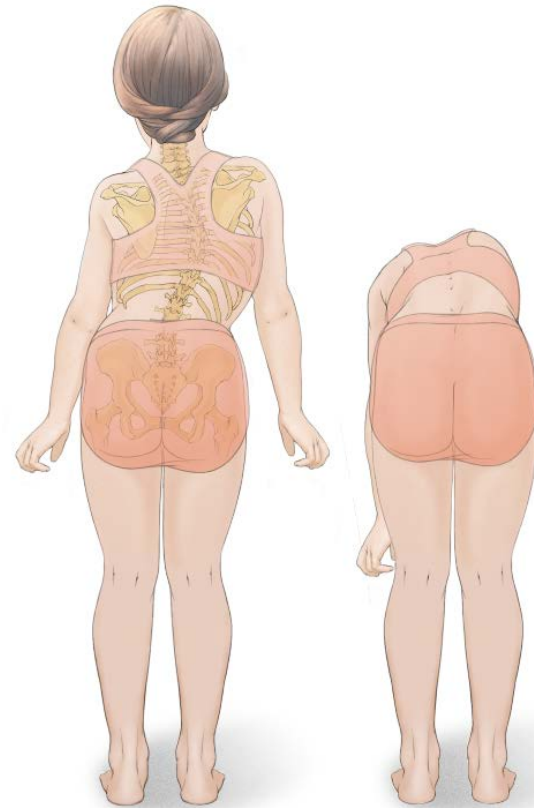

- An inclinometer (Scoliometer) measures distortions of the torso.

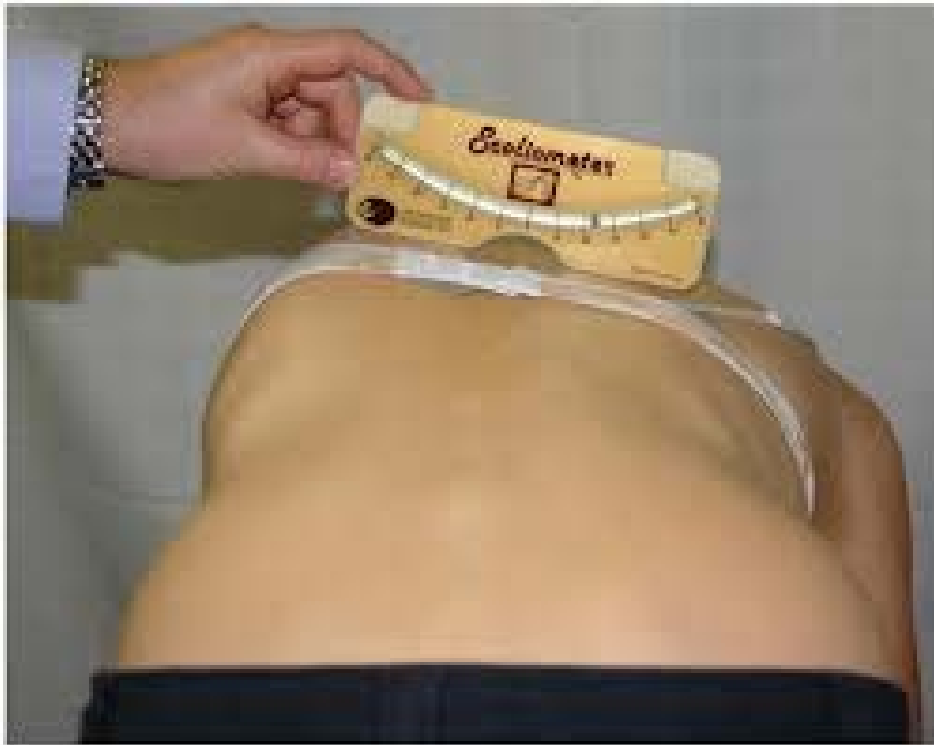- Scoliometer measurements, following the methodology proposed in this study, showed good correlation with the Cobb angle, the gold standard measurement.
- It had good intra- and interrater reliability and was sensitive in detecting curvatures greater than 10° Cobb using a referral criterion of 5° ATR, indicating its potential for screening individuals with idiopathic scoliosis.
- Coelho DM, Bonagamba GH, Oliveira AS. Scoliometer measurements of patients with idiopathic scoliosis. Braz. J. Phys. Ther. vol.17 no.2 São Carlos Apr. 2013.

Scoliometer Examination

- The patient is asked to bend over, with arms dangling and palms pressed together, until a curve can be observed in the thoracic area (the upper back).



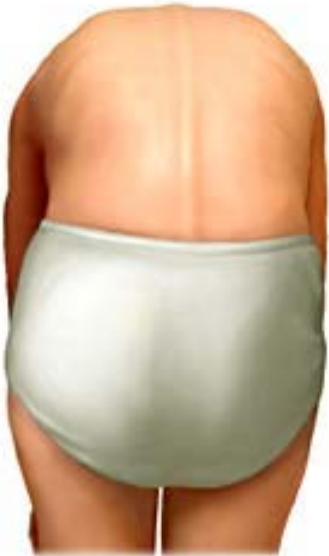Scoliometer Examination



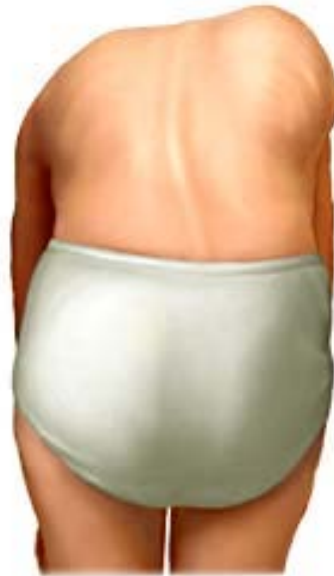- The Scoliometer is placed on the back and used to measure the apex (the highest point) of the curve.

Scoliometer Examination

Normal spine



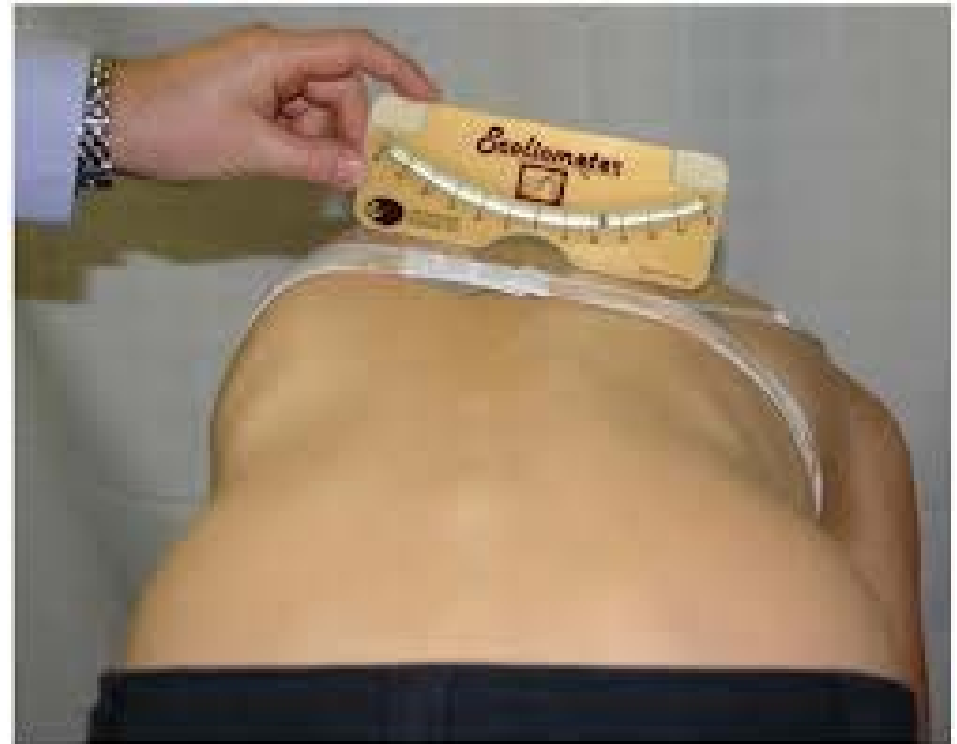Deformity from scoliosis



- The patient is then asked to continue bending until the curve in the lower back can be seen; the apex of this curve is then measured.

Scoliometer Examination

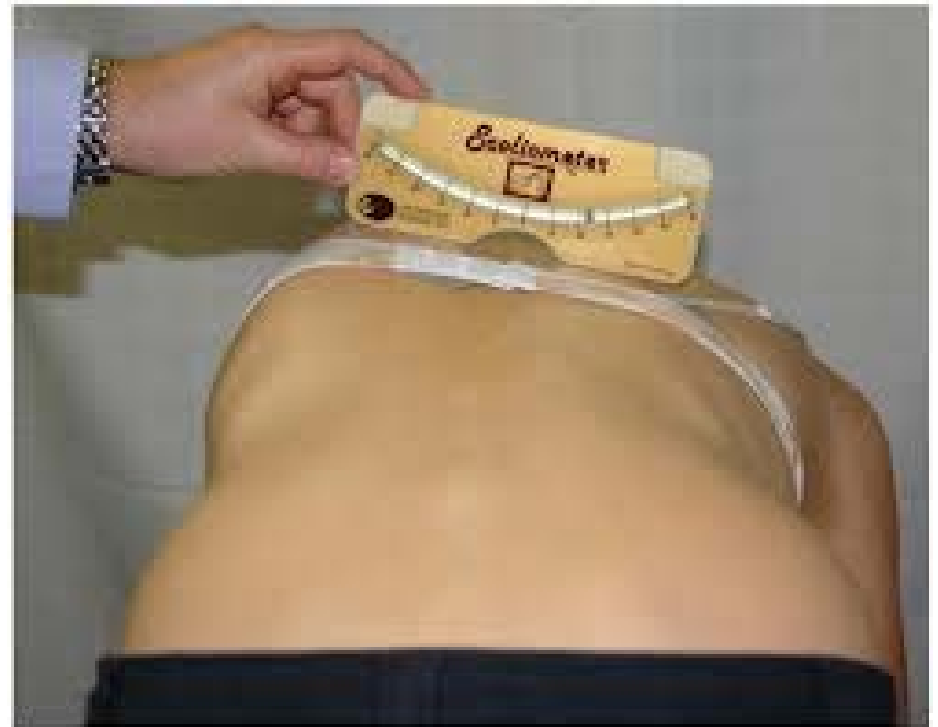- The measurements are repeated twice, with the patient returning to a standing position between repetitions.



- National Scoliosis Foundation

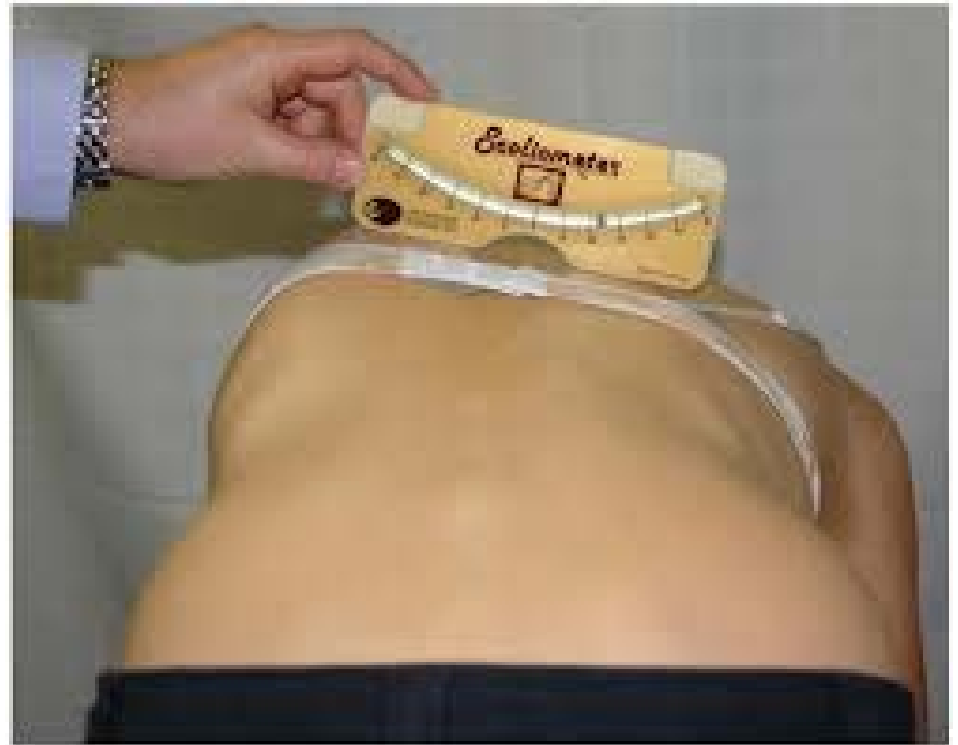Scoliometer Examination

- The results of the Scoliometer can indicate problems, and some experts believe it is a useful device for widespread screening.
- National Scoliosis Foundation



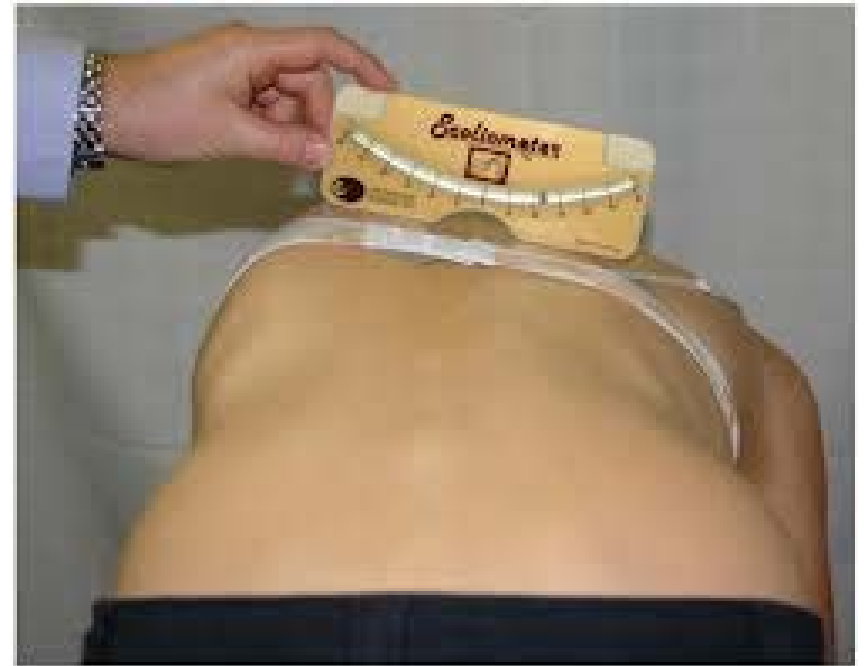Scoliometer Examination

- This screening device measures angle of rotation.
- It provides objective guidelines for referral and reduces x-ray exposure.
- National Scoliosis Foundation



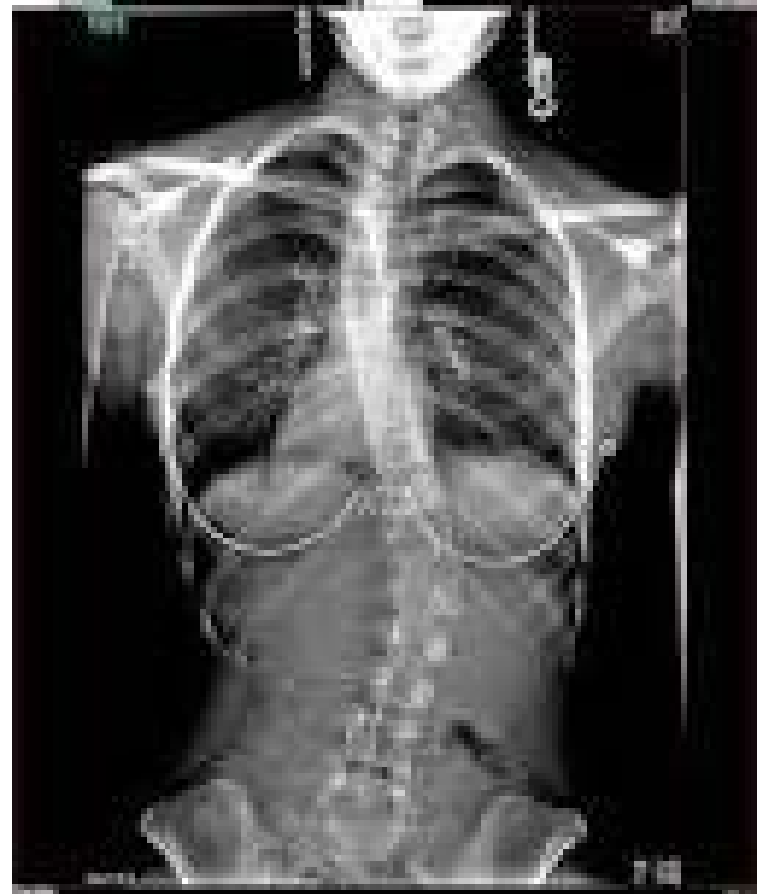Scoliometer Examination

- Scoliometers, however, measure rib cage distortions in more than half of children who turn out to have very minor or no sideways curves.
- National Scoliosis Foundation



Scoliometer Examination

- Scoliometers are not accurate enough to guide treatment, and, if results show a deformity, x-rays need to be performed.
- National Scoliosis Foundation



Using a Scoliometer

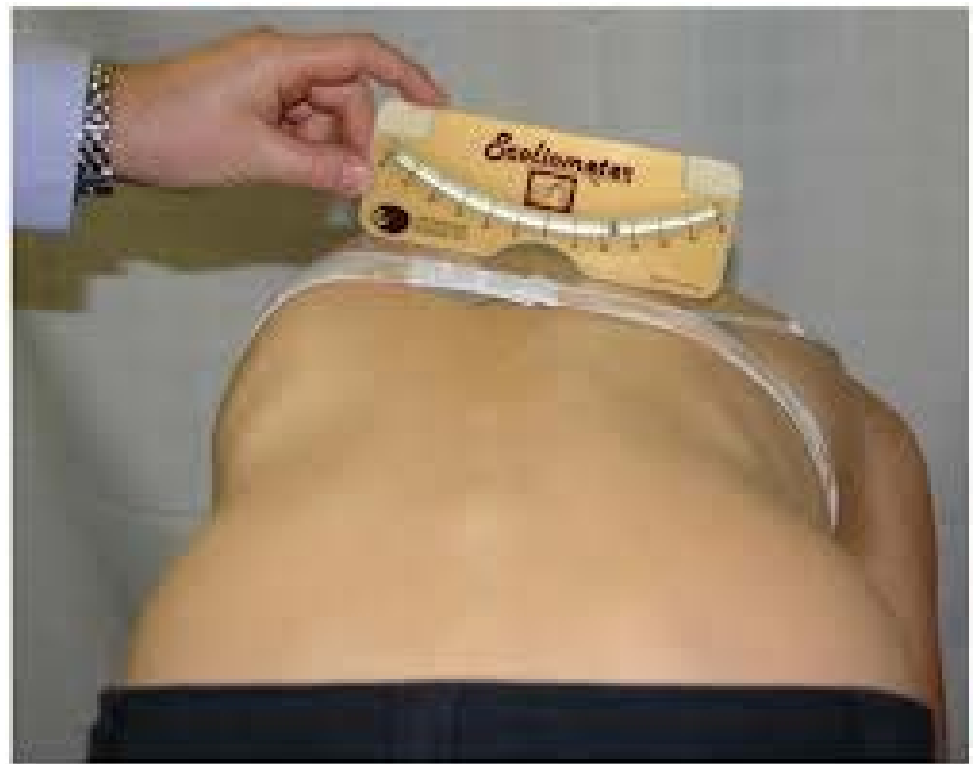- Ask the child to slowly bend forward until the shoulders are level with the hips. The examiner should view the child from the back with eyes at the same level as the back.
- Adjust the bending position height so the deformity of the spine is most pronounced.
- Gently lay the scoliometer across the deformity at right angles to the body, with the marking centered over the curve. Observe the scoliometer reading.

- Texas Scottish Rite Hospital
- <http://www.tsrhc.org/scoliosis-soliometer>

Scoliometer Examination

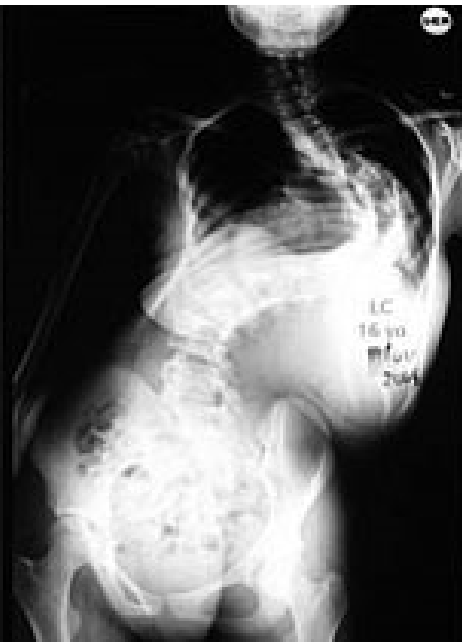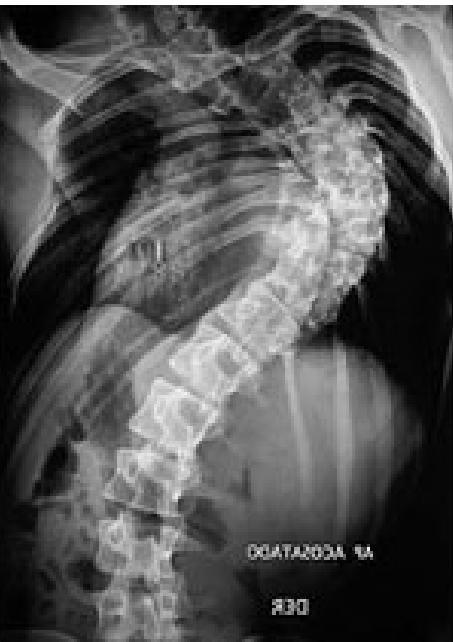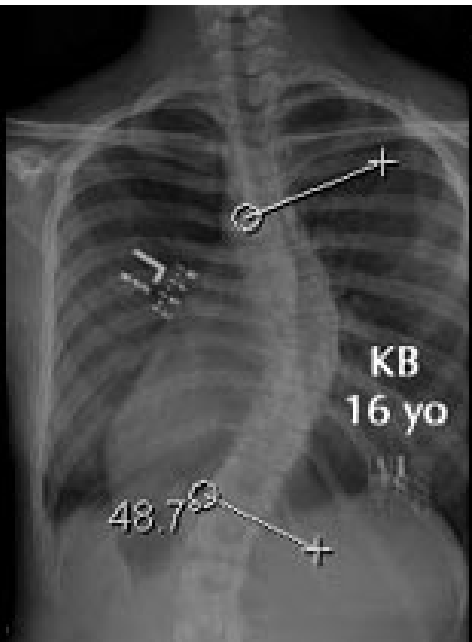
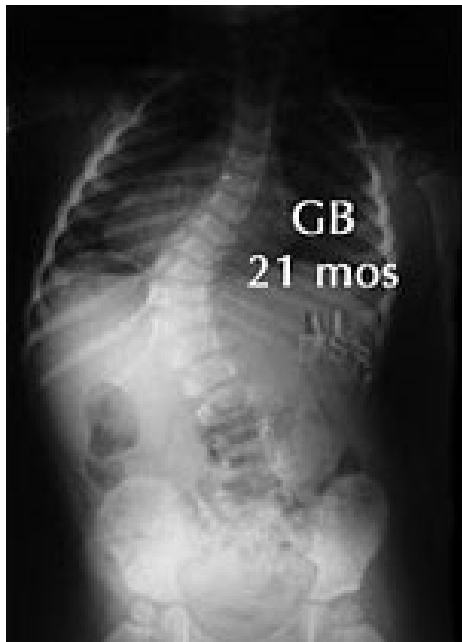Seven (7) degrees is the threshold for diagnosis of scoliosis using the Scoliometer.

Texas Scottish Rite Hospital



Evaluation of Adolescent Idiopathic Scoliosis (AIS)

- Presently, AIS is diagnosed and then treated almost entirely by a time lapse series of x-rays which form the basis for measuring the patient's curve magnitude (the only caveat being that brace treatment is thought to be effective only in patients who are still growing).

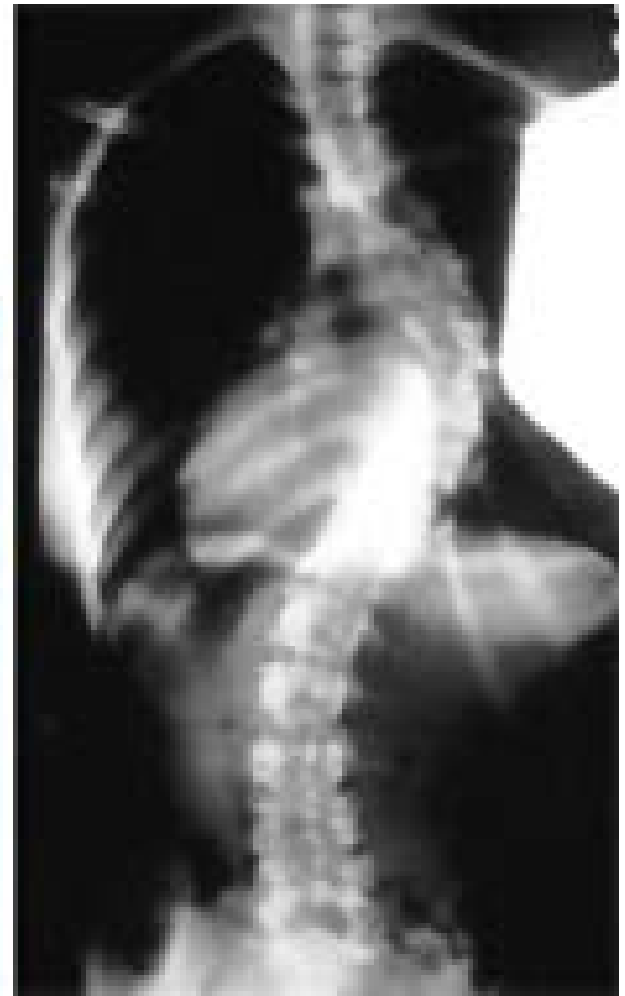
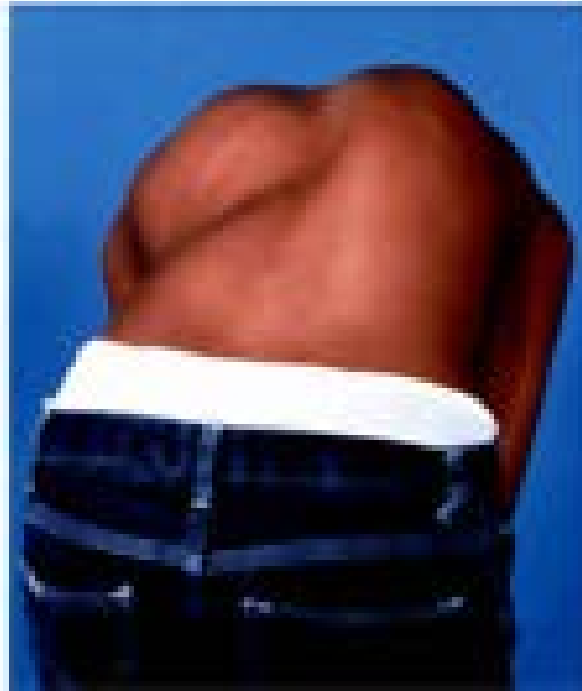
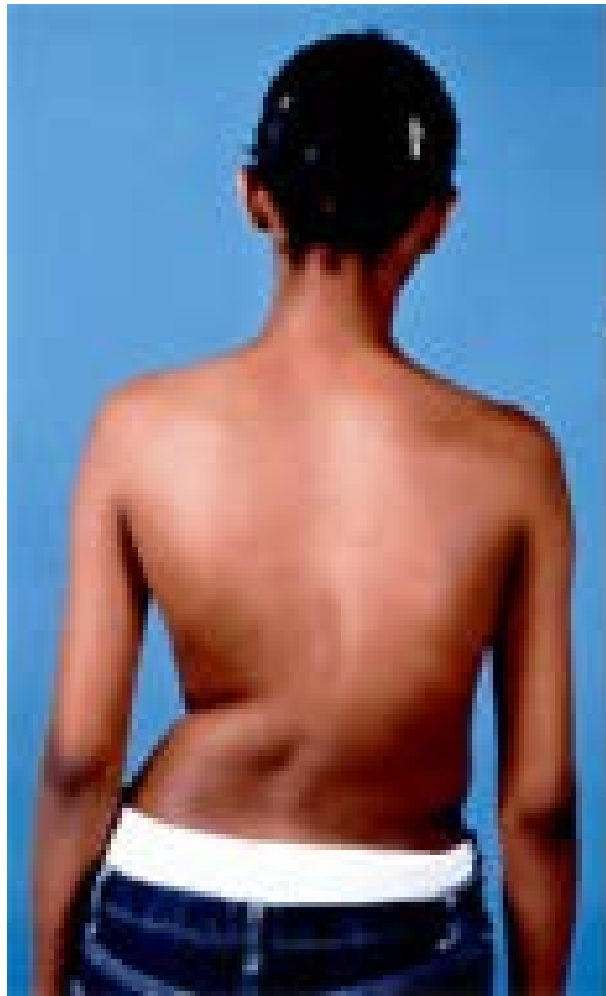Traditional Protocol for Scoliosis Evaluation and Management

- A young patient presents with parents who have noticed excessive spine curvature or the patient complaining of back pain.
- A radiographic series with 14X36 radiographs and measurements are performed

Scoliosis Management

- If AIS is diagnosed, a treatment plan follows:
- Observe (via 14X36" radiographs) curves less than 30°
- Brace curves in the 30°–40° range
- Perform surgery if curves exceed 40°



Scoliosis Management

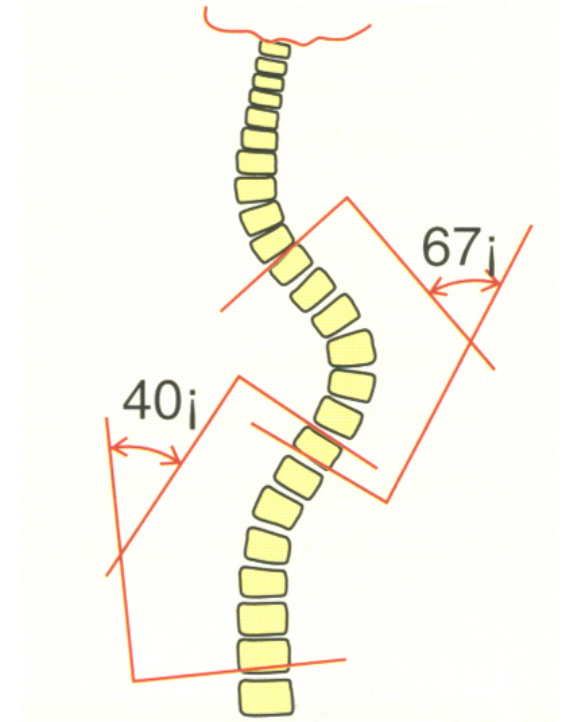
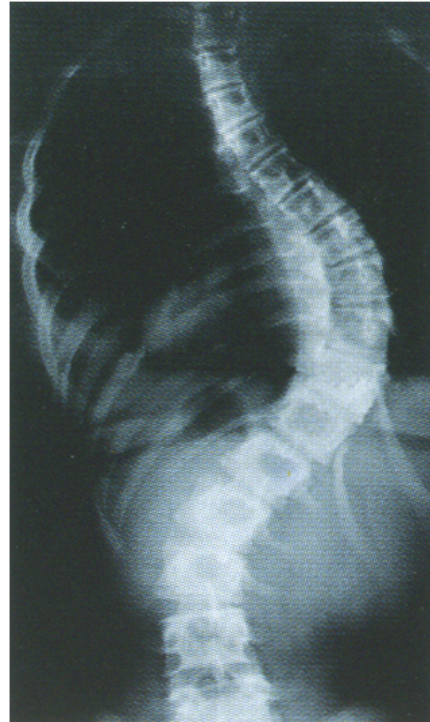- Each decision point rests on a 10° increment—including between observation and major spinal surgery.
- Realize that 10° is also the commonly discussed margin of error for measuring scoliotic curves.

Adolescent Idiopathic Scoliosis Management

- *It is important to monitor the curves with x-rays until approximately 15 years of age in girls, and 18 years of age in boys. When curves reach 25-30 degrees, we consider bracing. Surgery may be indicated in curves over 40-45 degrees.*
- Illinois Spine and Scoliosis Center
- http://www.myissc.com/spine_problems/scoliosis/idiopathic_scoliosis.htm

Question?

Can you name the radiographic view?



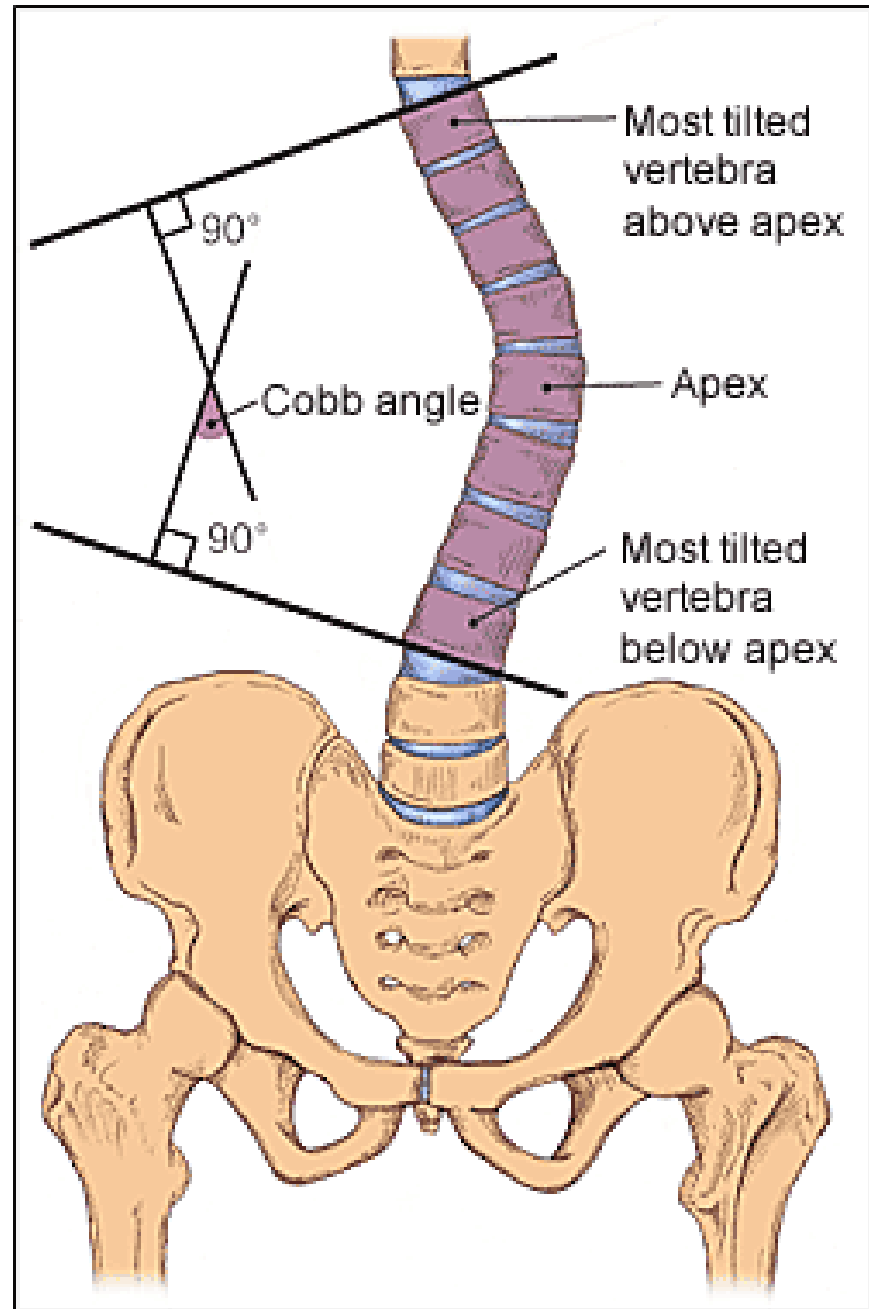
Radiographic Examinations for AIS

The physician takes a series of X-rays and measurements and if AIS is diagnosed, begins a treatment plan as follows:

Observe (via X-ray) curves less than 30°

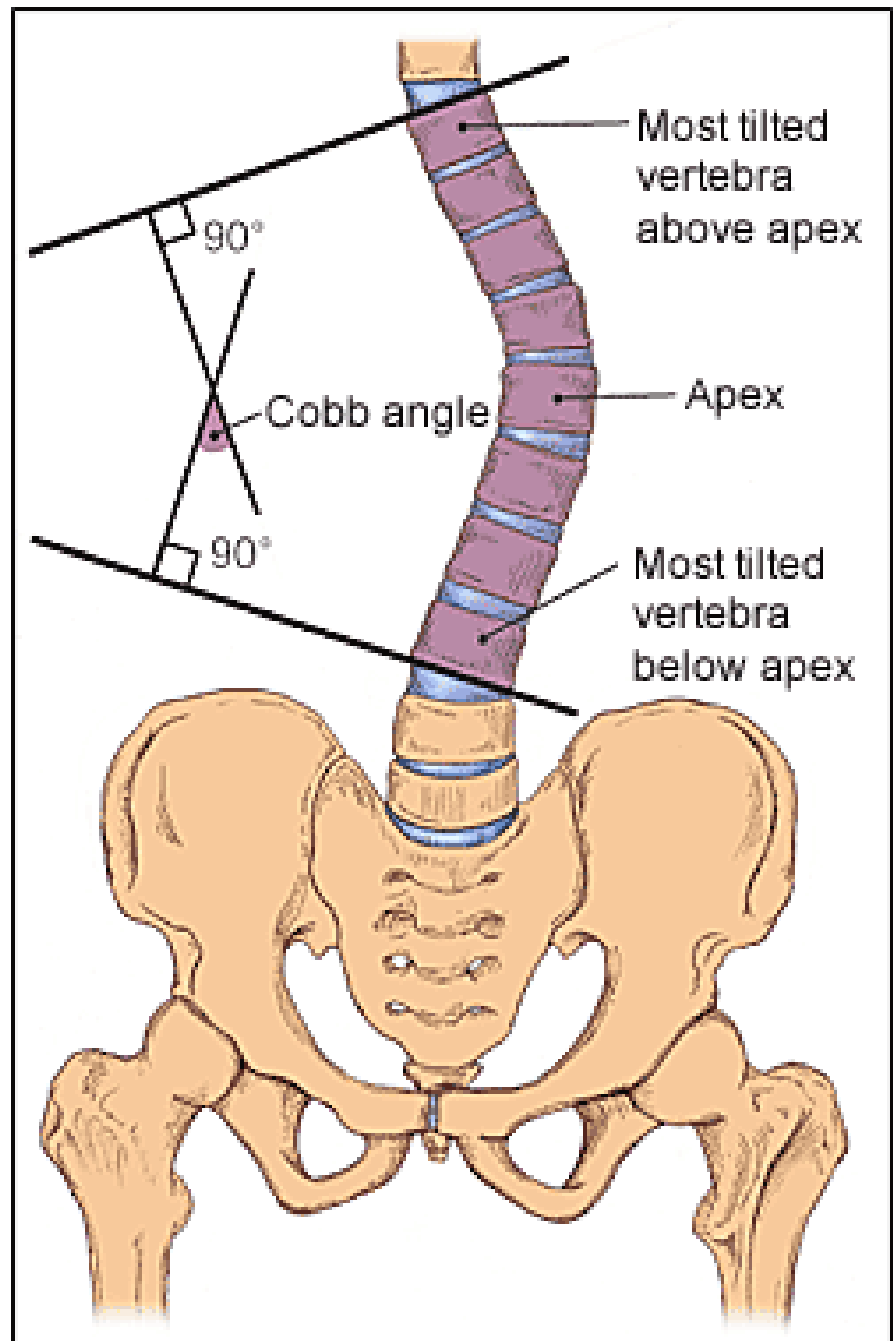
Brace curves in the 30° – 40° range

Perform surgery if curves exceed 40°



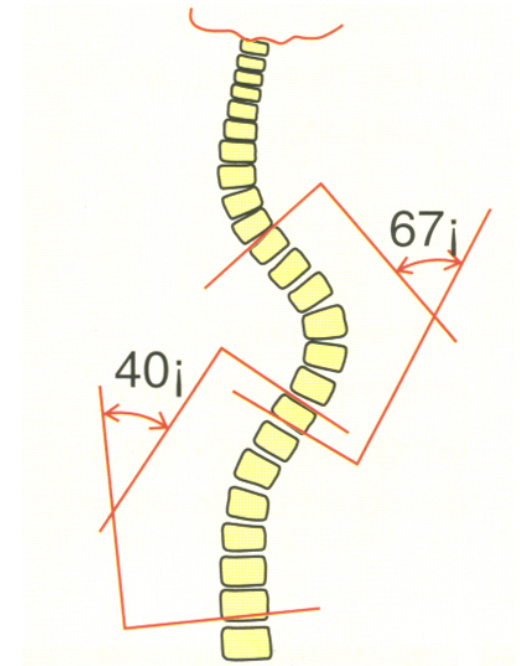
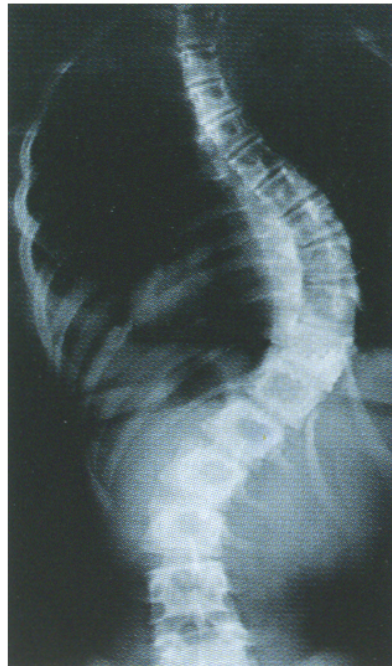AIS Management

Does it concern you that each decision point rests on a 10° increment—including between observation and major spinal surgery?



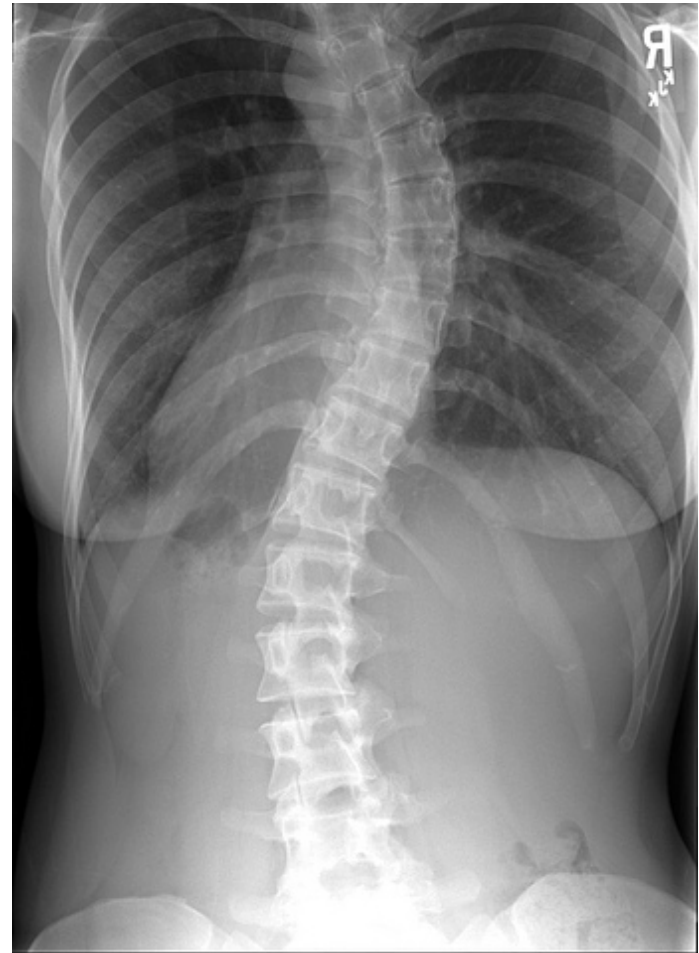
AIS Management

- Remember that 10° is also the commonly discussed margin of error for measuring scoliotic curves.



AIS Management Complication

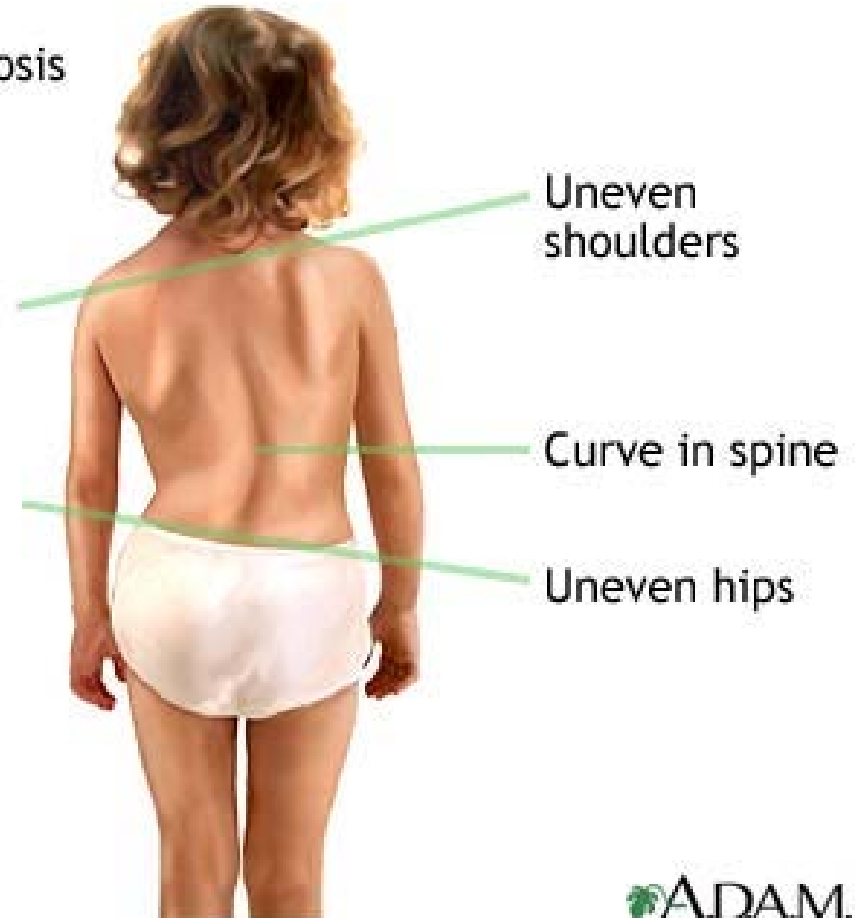
- A rapidly growing 13-year-old child can suddenly hit a growth phase and go from 16°–26° literally overnight.



Adolescent Idiopathic Scoliosis

A typical case would be a young patient whose parents have noticed excessive spine curvature or the patient complaining of back pain.

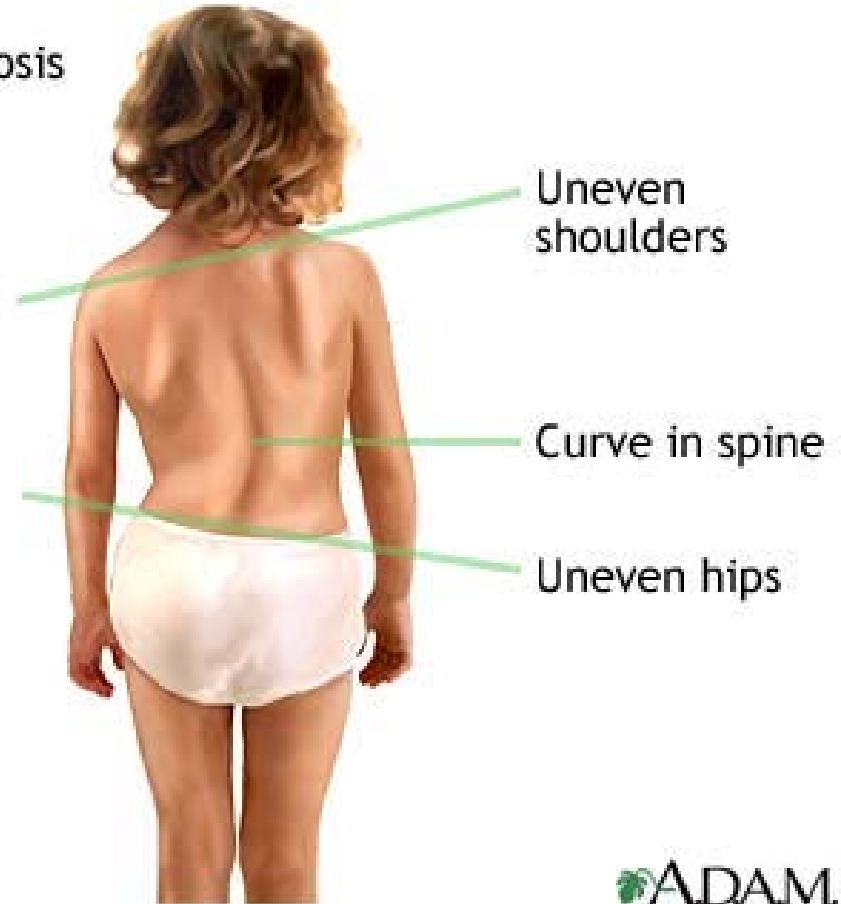
Signs of scoliosis



Question

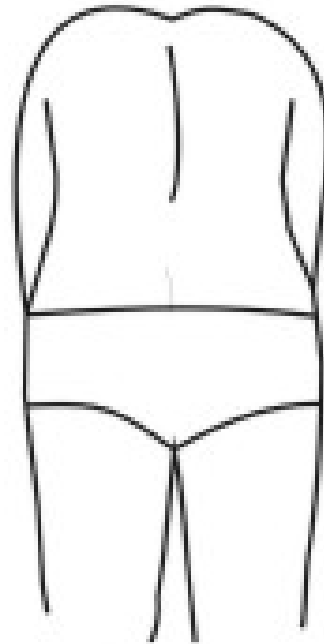
Does this child present with an idiopathic scoliosis requiring radiographic studies?

Signs of scoliosis

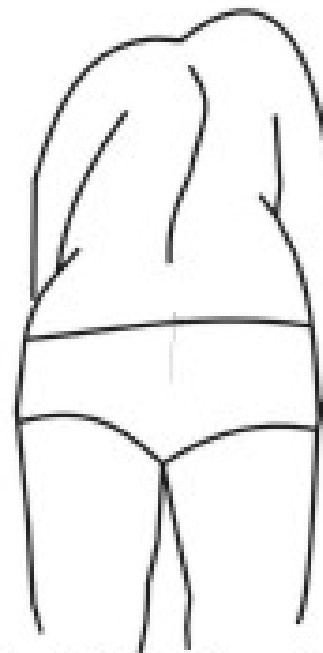


Adam's Positions

When bending forward



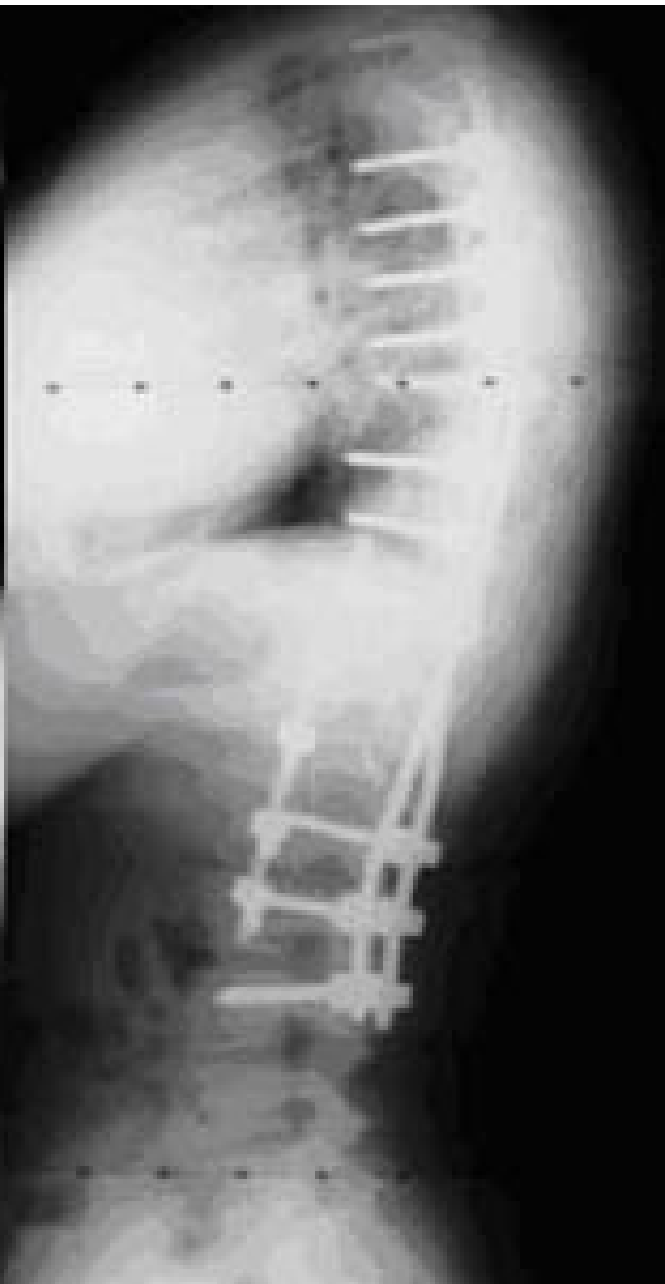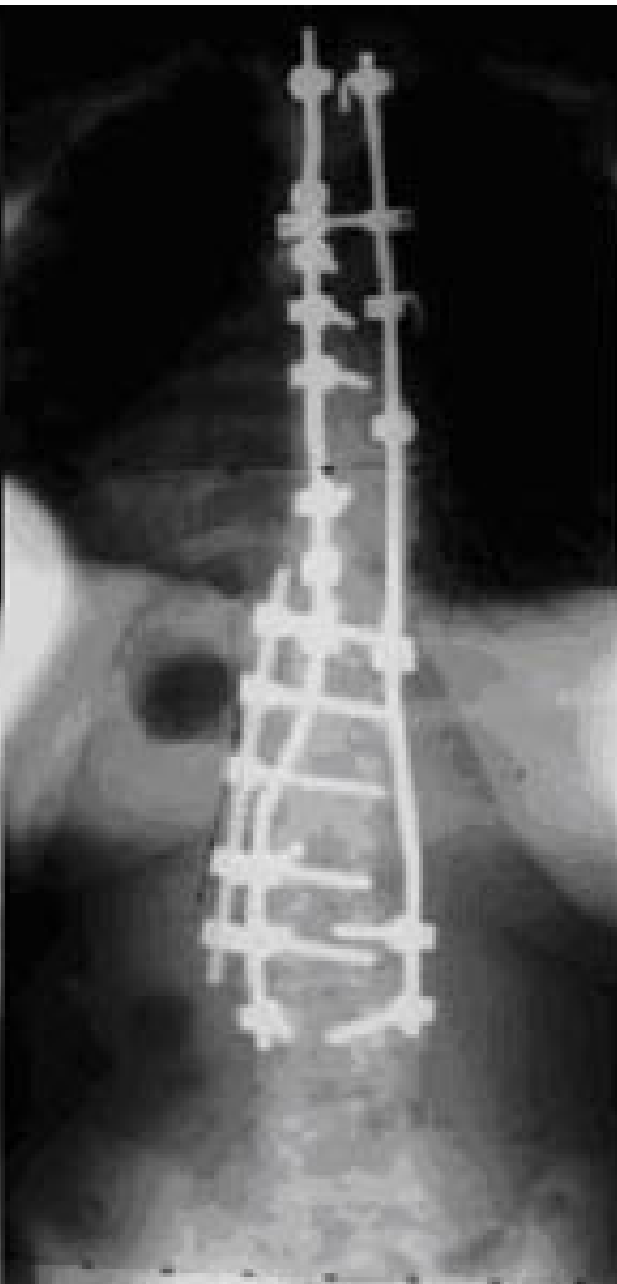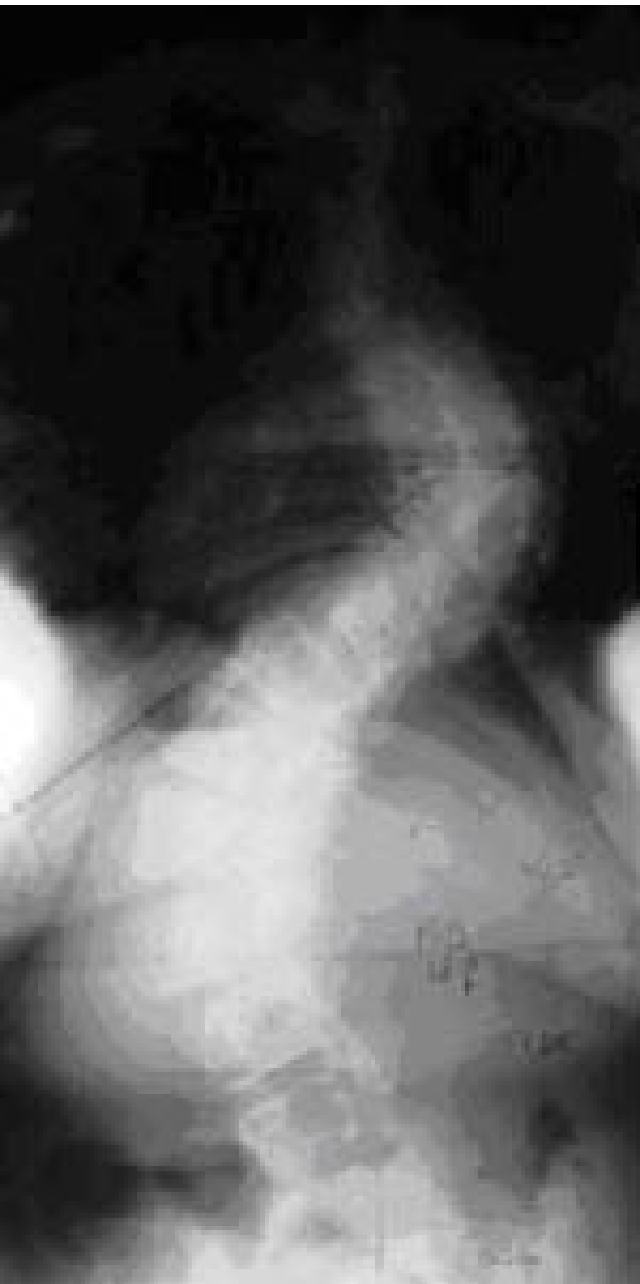Normal

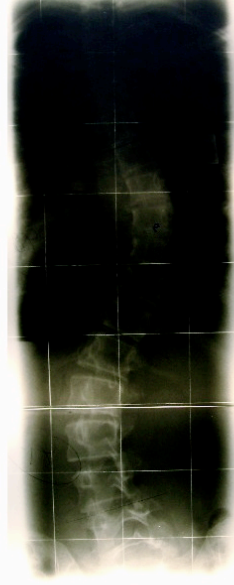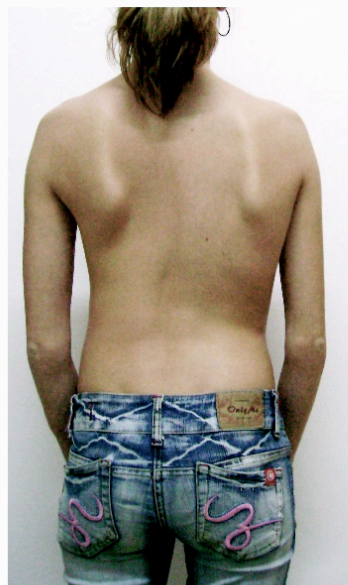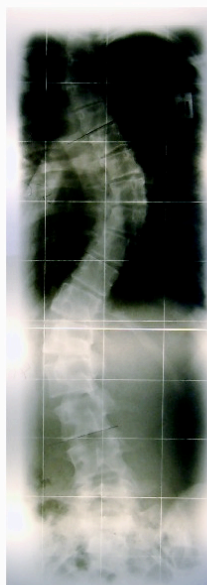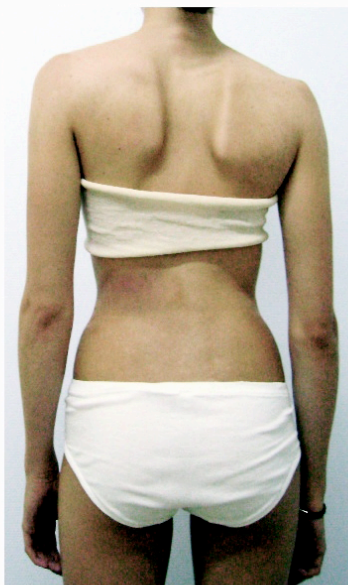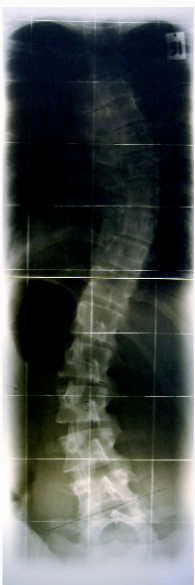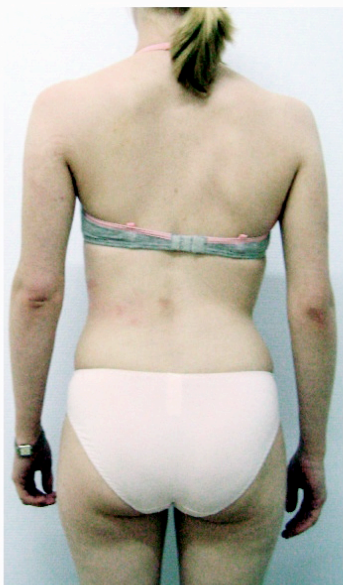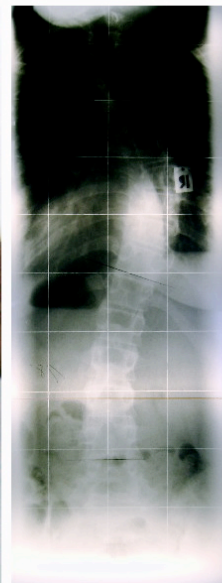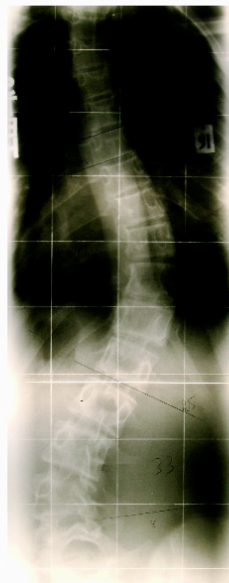


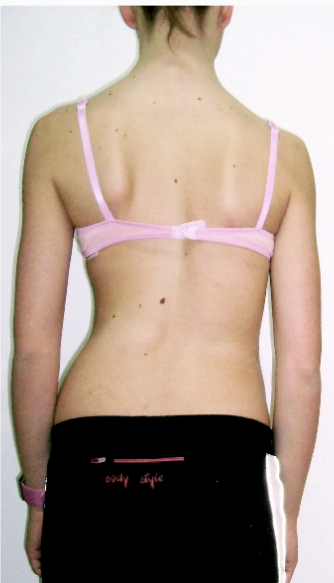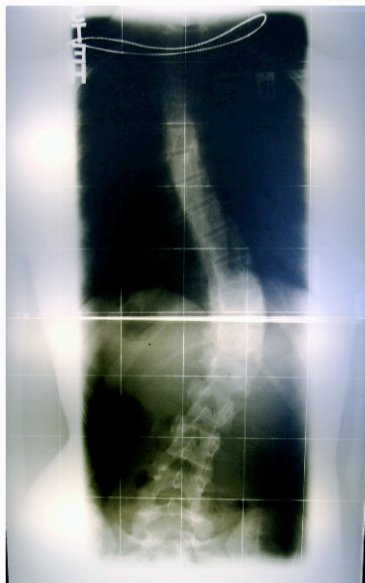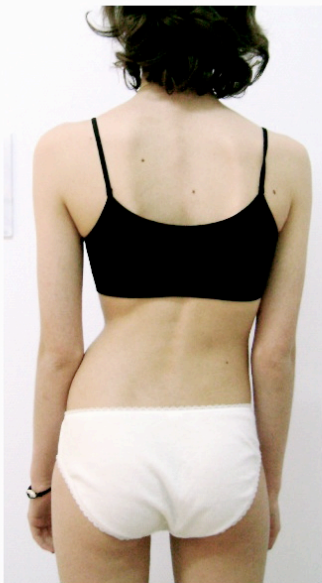A child with scoliosis

A scoliosis brace is usually worn under clothing and is one method used to try to improve the exaggerated curvature of the spine as seen in scoliosis



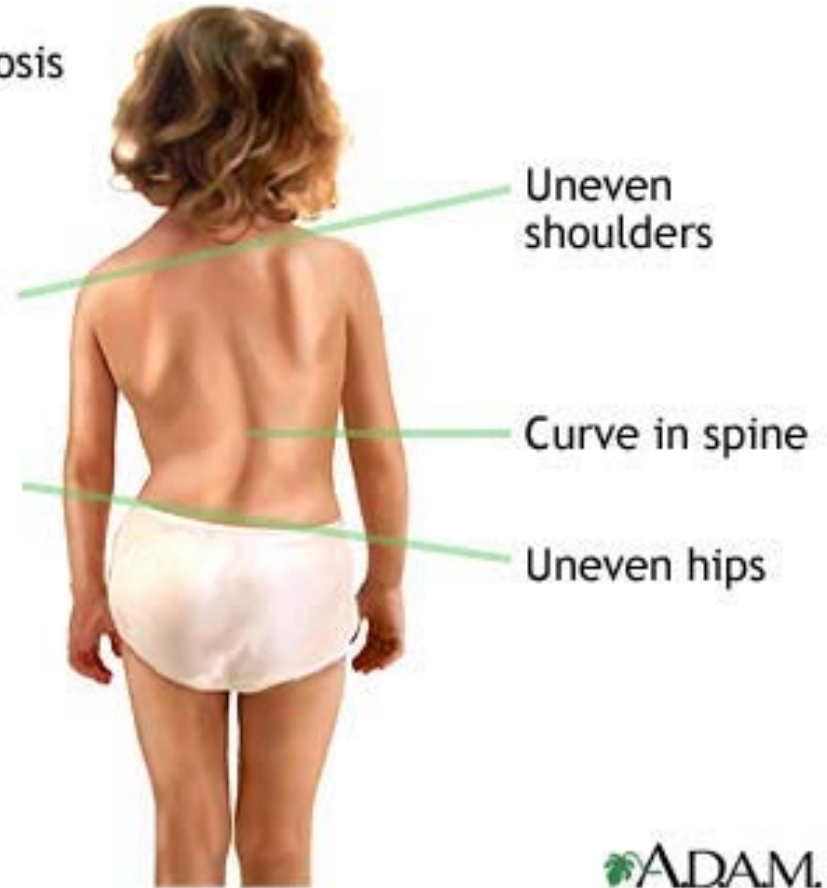


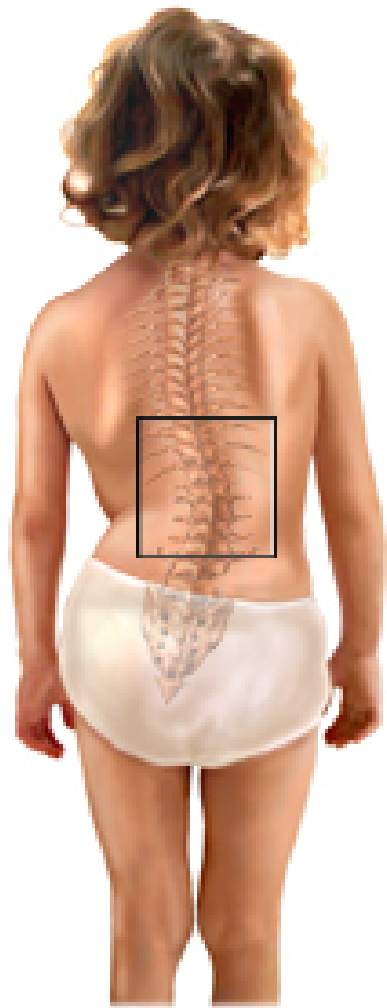


Adolescent Idiopathic Scoliosis (AIS)

Presently, AIS is diagnosed and then treated almost entirely by a time lapse series of x-rays which form the basis for measuring the patient's curve magnitude (the only caveat being that brace treatment is thought to be effective only in patients who are still growing).

Signs of scoliosis



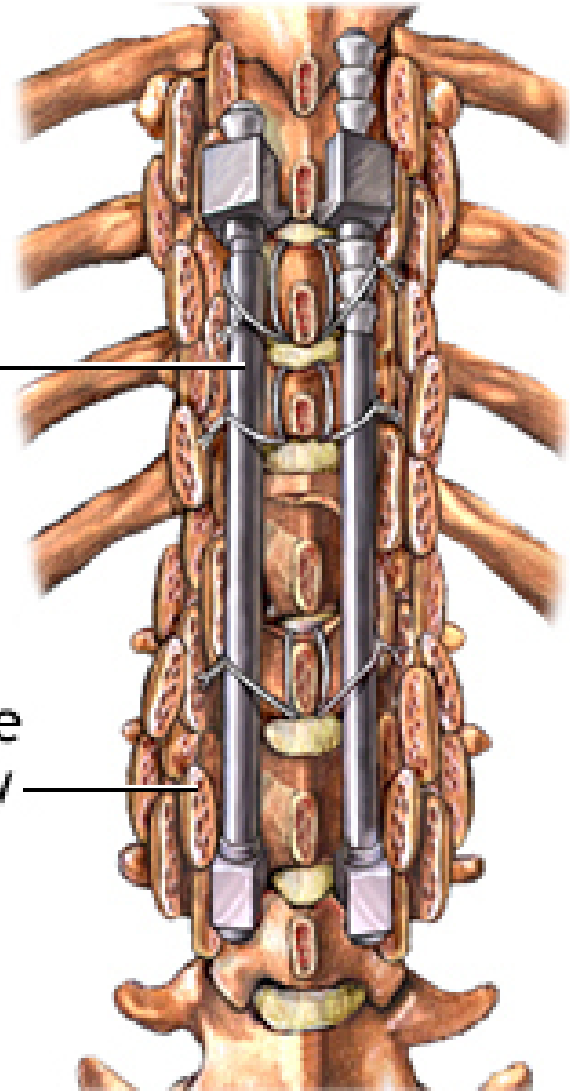


Scoliotic spine

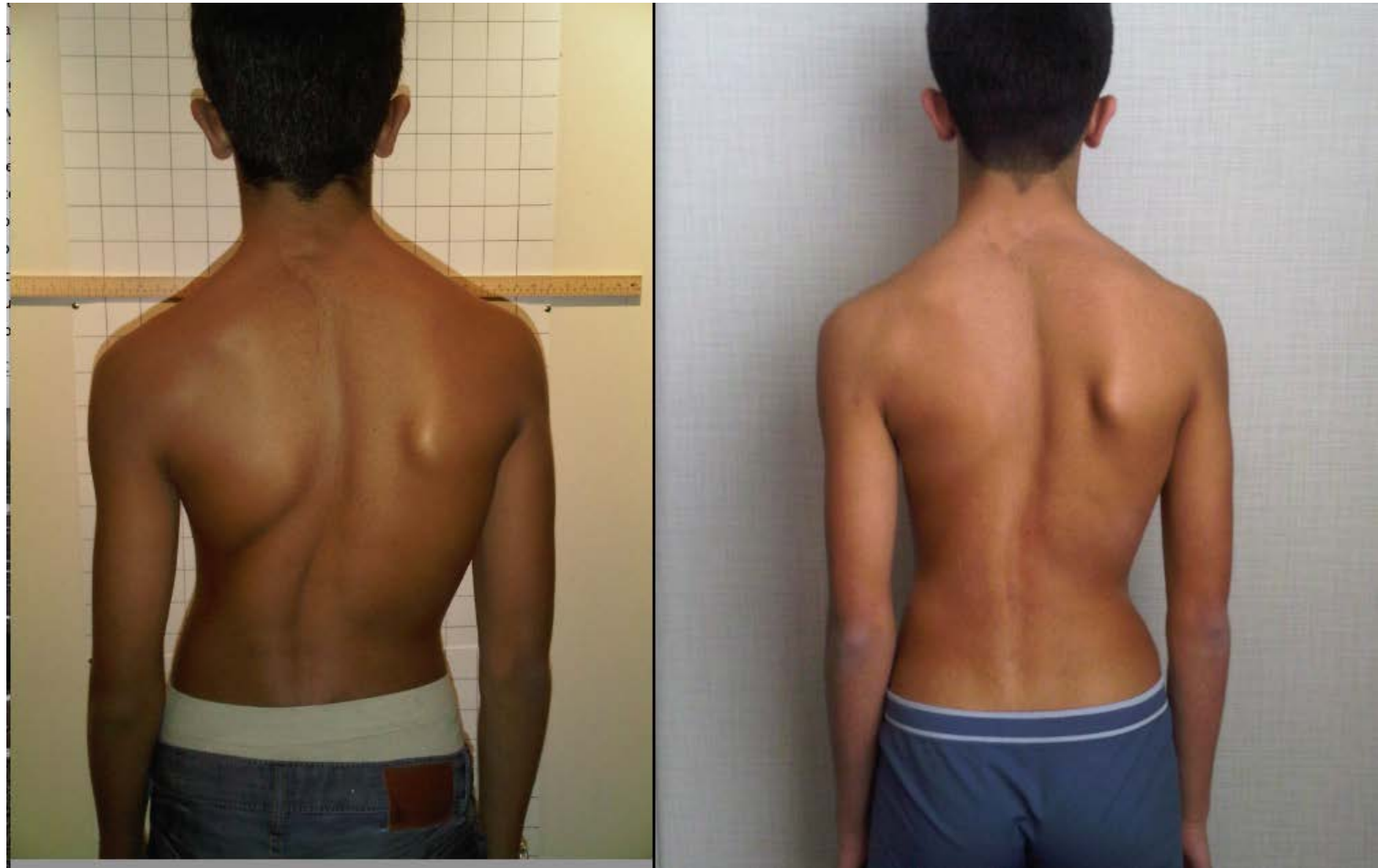Spinal fusion

Steel rods help support the fusion of the vertebrae

Bone grafts are placed to grow into the bone and fuse the vertebrae



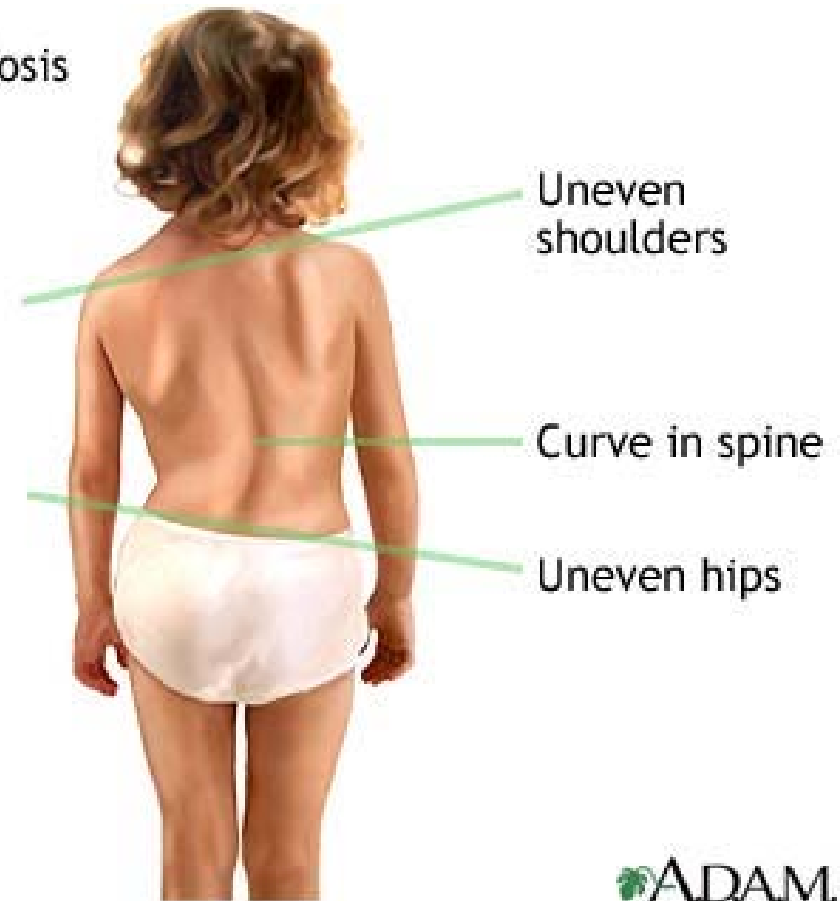
Pre and Post Surgical Fusion



Scoliosis is an inherited disease.

After four years of development, testing DNA samples from more than 9,000 patients, tracking billions of genotypes and making trillions of calculations, a company announced that it has found the specific, genetic markers for scoliosis.

Signs of scoliosis



The ScoliScore™ Test

- The first clinically validated and highly accurate genetic test for Adolescent Idiopathic Scoliosis curve progression.
- Scoliscore is a DNA test that can indicate the likelihood of progression into a severe curve for children diagnosed with idiopathic scoliosis.

The ScoliScore™ Test

- This test is appropriate for children nine to thirteen years of age with a mild to moderate curve who are self reported Caucasian males and females.
- The test is performed simply and pain-free by analyzing the patient's saliva which is collected in the office.

The Scoliscore™ Test

- The Scoliscore Test analyzes 53 genetic markers correlated with curve progression and has a 99% negative predictive value in determining the risk of progression.
- The test was developed in collaboration with over 110 clinicians worldwide, was designed through the analysis of over 10,000 patient samples and was validated in three multi-center independent clinical trials.

Progression

Brace Start


Correction

Brace End


Post-Op




12 yrs - 26"
Risser 0




12 yrs - 30"
Risser 0



13 yrs - 31"
Risser 0



14 yrs - 44"
Risser 3



14 yrs
Risser 4

The ScoliScore™ Test

- Scoliscore assigns a number from 1-200 to indicate a low, medium or high risk likelihood for curve progression.
- The assigned number is based upon the child's DNA and their current Cobb angle (angle of the curve on scoliosis x-rays).

The ScoliScore™ Test

- This test is revolutionary as it allows the child and parents to have a more reliable indicator of their child's future spinal health.

The ScoliScore™ Test

- Risk stratification combined with family history, current status and remaining growth left allows for a customized treatment discussion which may allow for reduced x-ray exposure and altered follow-up frequency.
- Virginia Spine Institute

Scoliscore Conclusions

- We demonstrate that a genetic test correlates with bracing outcome. It may be appropriate for future bracing studies to include analysis of genetic predisposition to limit potential confounding.
- [Bohl DD¹](#), [Telles CJ](#), [Ruiz FK](#), [Badrinath R](#), [DeLuca PA](#), [Grauer JN](#). A Genetic Test Predicts Providence Brace Success for Adolescent Idiopathic Scoliosis When Failure Is Defined as Progression to >45 Degrees. [Clin Spine Surg.](#) 2016 Apr;29(3):E146-50

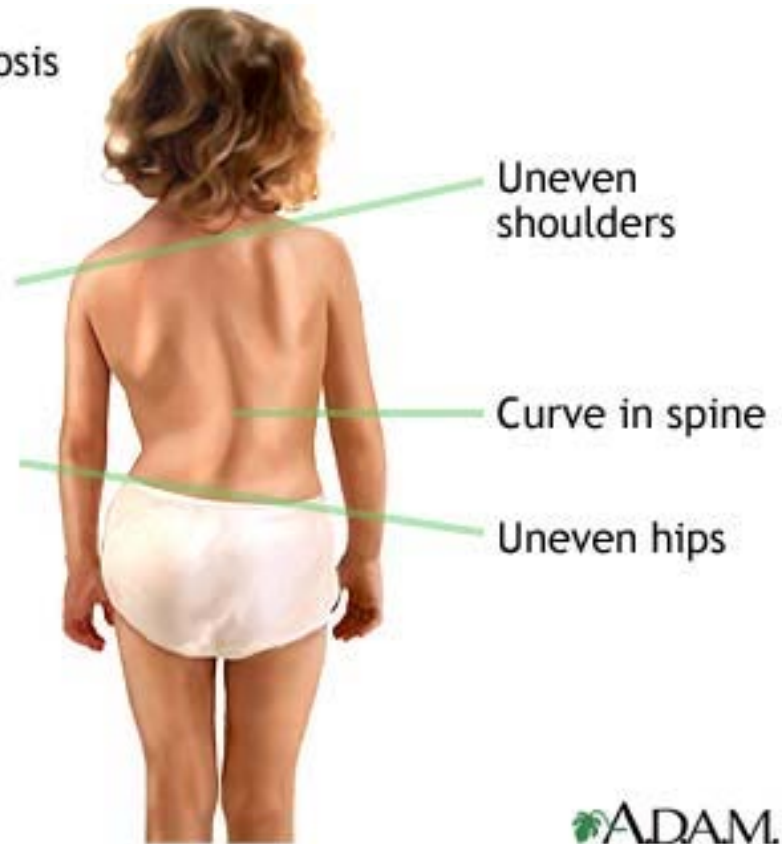
Scoliscore Conclusions

- Only Cobb angle showed significant correlation with ScoliScore among the socioclinical variables studied. The risk distribution of the 2 risk estimation systems examined differed markedly: ScoliScore predicted nearly 16 times more low-risk patients and more than 5 times fewer high-risk patients. This demonstrates that ScoliScore provides unique information to traditional predictors of curve progression, advancing our understanding of the role of ScoliScore in the clinical setting.
- [Roye BD¹](#), [Wright ML](#), [Williams BA](#), [Matsumoto H](#), [Corona J](#), [Hyman JE](#), [Roye DP Jr](#), [Vitale MG](#). Does ScoliScore provide more information than traditional clinical estimates of curve progression? [Spine \(Phila Pa 1976\)](#). 2012 Dec 1;37(25):2099-103.

Clinical Question

Should this young girl be referred for Scoliscore or traditional management with radiographic examinations, bracing, and then surgical intervention?

Signs of scoliosis



Engaged Learning Task

- Form groups of 3-6 learners
- Select a spokesperson
- Determine if the young, female presented on the previous slide should be evaluated and managed with the traditional protocols or Scoliscore
- Present your case substantiating your position
- 15 minutes for group discussions
- 3 minutes for each presentation

Engaged Learning Task

- Form groups of 3-6 learners
- Select a spokesperson
- Describe the traditional protocol for the evaluation of a adolescent presenting with progressive, adolescent idiopathic scoliosis
- Mention the imaging studies, interventions, length of time and prognosis
- 30 minutes to research and prepare
- 5 minutes for each presentation

Diagnosis and prognosis are the keys to successful treatment of patients with scoliosis!



THANK YOU

GRACIAS

ARIGATO

SHUKURIA

JUSPAKAR

DANKSCHEEN

TASHAKKUR ATU

THANHYEYLAH

SUKSAMANA

TRACI

BĪYAN

SHUKRIA

GRAZIE

MEHRBANI

PALENGS

GOZANADITA

ENCASIBITO

BOLZIN

MERCI